

**PUBLICATION INFORMATION:**

Holcomb, JD, Duncan, D, Lin, M, et al. Helium plasma dermal resurfacing: Consensus guidelines. Dermatological Reviews. 2020; 1: 97– 107. <https://doi.org/10.1002/der2.22>

**FINANCIAL & CONTENT DISCLOSURE:** : John David Holcomb, MD, is a consultant and clinical trial investigator for Apyx Medical and is a past recipient of an unrestricted educational grant funded by Apyx Medical. Michael Lin, MD, is a clinical trial investigator for Apyx Medical. Joseph B. DeLozier III, MD, FACS owns privately purchased stock and stock options for Apyx Medical. Diane Duncan, MD, Richard D. Gentile, MD, MBA, Paul G. Ruff, MD, and Edward Zimmerman, MD, are Medical Advisory Board members, consultants, and clinical research investigators for Apyx Medical and receive compensation in the form of Apyx stock and hourly compensation. JD McCoy, NMD, is a consultant for Apyx Medical. Melinda Lacerna was a clinical trial investigator for Apyx Medical. The opinions contained herein are those of the author and do not necessarily represent the official position or policies of Apyx Medical, Inc.

Apyx Medical sponsored a Dermal Resurfacing consensus meeting and provided discussion topics. Invitees were selected as a sampling of various types of users from very experienced to limited experience to ensure varying perspectives. Dr. Duncan facilitated the consensus meeting and the clinical discussion. The physicians independently arrived at conclusions and their recommended guidelines as detailed in this paper based on those discussions. This publication is an output of this meeting. This article was funded in whole by Apyx.

**MANUFACTURING DISCLOSURE:** Apyx Medical manufactures and owns the Renuvion/J-Plasma technology discussed in this article.

**INDICATIONS FOR USE & INTENDED USE DISCLOSURES**

- The Renuvion® Dermal System is an electrosurgical device for dermatological procedures for the treatment of moderate to severe wrinkles and rhytides, limited to patients with Fitzpatrick skin types I, II or III. The treatment is achieved through controlled heating of the outer layers of the skin so that part or all of the epidermis becomes non-viable and there is controlled thermal modification to the underlying dermis.
- Apyx Medical wants to present you with current scientific discourse. Specific usage outside of the cleared indications may not be safe or effective.


**RISKS:**

- Risks associated with the use of the Renuvion Dermal System include but are not limited to hypertrophic scarring, milia/acne, telangiectasia (spider veins), skin discoloration/hypopigmentation, dormant infection reactivation, infection, bruising or bleeding. Warning: Application of more than one treatment pass in the perioral area, on the forehead, and along the jawline has been associated with hypertrophic scarring.

As with any procedure, individual results may vary. As with all energy devices there are inherent risks associated with its use, refer to the IFU for further information.

*The following document may only be disseminated with this disclaimer cover page attached.*

# Helium plasma dermal resurfacing: Consensus guidelines

John David Holcomb MD<sup>1</sup>  | Diane Duncan MD<sup>2</sup> | Michael Lin MD<sup>3</sup> |  
J. D. McCoy NMD<sup>4</sup> | Richard Gentile MD<sup>5</sup> | Edward Zimmerman MD<sup>6</sup> |  
Melinda Lacerna MD<sup>7</sup> | Paul G. Ruff MD<sup>8</sup> | Joseph B. DeLozier MD<sup>9</sup>

<sup>1</sup>Holcomb—Kreithen Plastic Surgery and MedSpa, Sarasota, Florida

<sup>2</sup>Plastic Surgical Associates, Fort Collins, Colorado

<sup>3</sup>Beverly Hills, California

<sup>4</sup>Contour Medical, Gilbert, Arizona

<sup>5</sup>Gentile Facial Plastic Surgery and Aesthetic Laser Center, Youngstown, Ohio

<sup>6</sup>Aesthetic Revolution, Las Vegas, Nevada

<sup>7</sup>LA Plastic Surgery and Dermatology, Sarasota, Florida

<sup>8</sup>West End Plastic Surgery, Washington, District of Columbia

<sup>9</sup>DeLozier Cosmetic Surgery Center, Nashville, Tennessee

## Correspondence

John David Holcomb, MD, 1S. School Ave,  
Ste 800, Sarasota, FL 34240.  
Email: [drholcomb@sarasota-med.com](mailto:drholcomb@sarasota-med.com)

## Abstract

**Introduction:** Nine experienced physician users of a novel helium plasma dermal resurfacing device for heating the skin at a controlled depth to achieve collagen coagulation, tissue contraction, and neocollagenesis convened to discuss their experiences and keys to success with their off-label use of this device with collectively more than 800 cases performed for facial skin renewal procedures.

**Methods:** A round table discussion format was used to address a variety of topics including pretreatment considerations, optimum treatment parameters, posttreatment healing regimen, and avoidance and management of side effects and complications. All panelists consented to data collection, analysis, compilation, and publication.

**Results:** Ideal candidates for the procedure were identified along with optimum treatment parameters and posttreatment care. Strategies for avoidance and management of complications and side effects were discussed.

**Conclusions:** Consensus guidelines were developed for patient selection, pretreatment considerations, treatment parameters, posttreatment healing regimen, and avoidance and management of complications and side effects.

## KEYWORDS

consensus guidelines, facial renewal, helium plasma, helium plasma dermal resurfacing, skin rejuvenation, treatment protocol

## 1 | INTRODUCTION

Plasma energy skin rejuvenation now has several treatment options including nitrogen plasma skin regeneration (PSR)<sup>1–3</sup> and helium plasma dermal resurfacing (PDR).<sup>4–7</sup> Nitrogen PSR was Food and Drug Administration (FDA) approved for treatment of wrinkles and acne scarring as well as superficial precancerous skin lesions in 2006 (K060948). While the more recently introduced helium plasma technology (Renuvion Dermal System; Apyx Medical Corporation, Clearwater, FL) is FDA approved for soft tissue ablation, coagulation, and cutting, dermal resurfacing treatment remains off-label (not yet FDA approved for a specific skin indication). Nonetheless, this

consensus guidelines panel understands that many practitioners are presently performing off-label helium PDR treatments and believes that publishing these guidelines for best practices is in the interest of patient safety and optimized outcomes. In addition, this consensus guidelines panel recognizes that we are still learning about this new technology as it emerges and that acceptable practices differ amongst clinicians successfully using this technology.

Preclinical studies comparing nitrogen and helium plasma (a second-generation device with radiofrequency (RF) transformer located remotely within the electrosurgical generator as opposed to within the handpiece in the first-generation device) skin tissue interaction in a porcine animal model used similar but not exactly equal

This is an open access article under the terms of the Creative Commons Attribution-NonCommercial-NoDerivs License, which permits use and distribution in any medium, provided the original work is properly cited, the use is non-commercial and no modifications or adaptations are made.

© 2020 The Authors. *Dermatological Reviews* published by John Wiley & Sons Ltd

energy densities that are also in widespread use clinically; 20% and 40% helium plasma power levels correspond to an energy density that is approximately 40% below and 20% above that for nitrogen plasma high energy treatment at 4 J and 2.5 Hz with 6-mm-diameter spot size.<sup>4</sup> Depths of acute tissue injury and chronic reparative healing were greatest for nitrogen plasma followed by 40% and then 20% helium plasma.<sup>4</sup> Acute and 30-day skin tissue contraction measurements showed greater area reduction for helium plasma vs nitrogen plasma.<sup>4</sup> Except for variance in depth of tissue effect, histopathology findings were very similar for the two plasmas at both time points.<sup>4</sup> The study authors suggested that the paradoxical finding of more superficial tissue injury but greater skin tissue contraction for the helium vs nitrogen plasma may relate to differences in skin tissue—plasma interaction (eg, more thorough full-field energy deposition for helium plasma, continuous vs pulsed energy delivery for helium and nitrogen plasma, respectively) and bimodal helium plasma energy delivery (top-down thermal convection/conduction and RF or Joule heating) vs unimodal top-down thermal convection/conduction for nitrogen plasma.<sup>4</sup>

The unique characteristics of the helium PDR technology suggest that it may be suitable for effective skin rejuvenation. An initial helium PDR study of 55 subjects has been completed. The multicenter study evaluated low energy (20% power, continuous helium gas flow at 4 L/min) single-pass treatment with the majority of subjects undergoing full-face treatment. Study results were very positive with most subjects achieving a Facial Wrinkle Scale score improvement of  $\geq 1$  at the 3-month primary endpoint (98% per study investigators vs 64% per blinded independent photographic reviewers), 91% of subjects reporting at least “improved” self-perception of improvement (modified Global Aesthetic Improvement Scale) at the 3-month primary endpoint, and a greater percentage reporting maximum improvement (“very much improved”) at 6 months.<sup>6</sup>

Numerous consensus guidelines have been developed for many available aesthetic procedures and technologies to ensure their safe use and optimized patient satisfaction.<sup>8–13</sup> The objective of the following discussion was to create treatment guidelines for the safe and effective use of this novel helium plasma energy skin rejuvenation device.

## 2 | CONSENSUS PANEL DISCUSSION

A panel of nine experienced facial plastic, general plastic, dermatology, and cosmetic surgeons convened to discuss their experiences and keys to success for using the helium-based plasma device for facial renewal procedures. The panel discussed and reached consensus on topics covering all aspects of patient treatment from patient selection, pretreatment regimens, treatment parameters, posttreatment protocols, and avoidance and management of complications and side effects. A summary of the panel consensus for each treatment topic is summarized below along with other important pearls of experience with the device.

## 3 | PATIENT SELECTION

*Consensus panel guidelines for optimum patient selection for helium PDR treatment are similar to those for nitrogen PSR and laser skin resurfacing, including indications and contraindications. One significant contraindication that is unique to helium PDR is the presence of implanted pacemaker devices as the treatment requires RF tissue coupling and the use of a grounding pad. A further recommendation is to restrict treatment to facial skin with feathering across the jawline into the upper neck permissible.*

Helium PDR candidates should have Fitzpatrick skin type I, II, or III along with the primary indication of readily visible facial wrinkles (mild, moderate, and severe). While they may also have visible UV-induced photodamage this is not a requirement, and if present in the absence of wrinkles, other technologies may be more appropriate for treatment. Patients with fair skin type and visible wrinkles but a diffuse tan of the face and neck should be advised that a temporary or permanent contrast in skin tone could occur in juxtaposed areas of the face and neck after treatment. Good candidates for treatment must be willing and able to accept the amount of downtime associated with the procedure (up to 2 weeks or longer) and must agree to be compliant with the posttreatment skin-healing regimen.

Absolute contraindications for helium PDR include implanted electrical devices, pregnancy or lactation, active infection in the treatment area, poorly controlled diabetes mellitus, significant immunocompromization, skin cancer, or suspicious skin lesion in treatment area and isotretinoin use in past 12 months. In addition, treatment of the upper eyelids should be avoided in the presence of lagophthalmos while treatment of the lower eyelids should be avoided in the presence of malposition or ectropion. While the consensus panel does not recommend helium PDR treatment in patients with skin type IV or higher, the panel agrees that treatment of darker skin types may be permissible in the future with advances in the technology (eg, with fractionalization of energy delivery).

Relative contraindications for helium PDR treatment include recent abrasive treatments (eg, microdermabrasion), emotional lability, inability to follow and perform posttreatment skin-healing regimen, any condition or medication that may adversely impact healing, known susceptibility to keloid formation or hypertrophic scarring, anticoagulation, prior lower eyelid blepharoplasty, or significant lower eyelid laxity. Depending on individual patient circumstances, the use of alternative skin rejuvenation technology may be desirable, but if helium PDR is done, certainly a lower energy setting and/or limitation of treatment to a single pass may be prudent. Pre-emptive or concurrent lower eyelid lateral canthoplasty may enable safe helium PDR treatment of the lower eyelids. Although anticoagulation needs not necessarily disqualify a patient from helium PDR treatment, patients using drugs that reduce coagulation (eg, aspirin and nonsteroidal anti-inflammatory drugs) may experience increased bruising or bleeding at the treatment site.

Alternative treatments to helium PDR should be discussed generally and certainly with those patients that are either not candidates for helium PDR or who may have reservations related to the newness

of the procedure. Other effective treatments include traditional therapies for skin rejuvenation (including full-field CO<sub>2</sub> or erbium YAG laser skin resurfacing, ablative fractional CO<sub>2</sub> laser skin resurfacing), therapies designed to enhance the dermal collagen matrix (eg, multidepth RF microneedling and platelet rich plasma application with microneedling) and treatments that enhance the subdermal tissue scaffold (eg, volumization with poly L-lactic acid, autologous fat grafting).

During the discussion on patient selection, the consensus panel agreed that setting proper patient expectations regarding what to expect during and after the procedure was extremely important. Several recommendations for pretreatment patient education were made including viewing daily healing progression photos from patients that have undergone helium PDR treatment and reviewing detailed posttreatment instructions that outline the expected healing process and identify potential signs and symptoms that should prompt a call with the treating physician's office (Table 1).

The difference in the appearance of the skin following a single-pass treatment without wiping ("frosted" and often darkened desiccated skin) and a multipass treatment with wiping between the first and second passes (typically a pale white color) should also be reviewed. The desiccated skin that remains after single-pass treatment without wiping will often slough completely within 7 days revealing regenerated pink new skin. During the healing process after multipass treatment, initial weeping of a straw-colored fluid may occur followed by the formation of a moist exudate that will ultimately slough away over the coming days. It should be pointed out that if the treatment includes both single- and multipass treatment then the healing process will include both of the above descriptions. Despite adequate compliance with the posttreatment healing regimen, one or more focal areas of slower healing may occur that typically appear as a dry crust.

#### 4 | PRETREATMENT PROTOCOL

*As is customary with perioral laser skin resurfacing,<sup>14</sup> the consensus panel recommends prescribing prophylactic antiviral medication for patients undergoing perioral helium PDR treatment. At this time, the consensus panel makes no formal recommendation for pretreatment preparation of the skin as no pretreatment protocol has been identified that is uniformly efficacious for all patients. The consensus panel does recommend avoiding skincare treatments that disrupt the upper skin layers (eg, microdermabrasion and dermaplaning) for 1 to 3 months before treatment.*

While no pretreatment protocols were uniformly recommended by the consensus panel, the consensus panel suggested several adjunctive treatments that they have found to be beneficial.

The following are optional adjunctive treatments that may be recommended at the discretion of the treating physician and that may help us to reduce the risk of infection, improve wound healing, neocollagenesis and ne elastogenesis, reduce inflammation, and the incidence and/or severity of postinflammatory hyperpigmentation (PIH).

**TABLE 1** When to call treating physician's office after helium PDR treatment

1. Excessive facial swelling
2. Unrelenting burning or stinging sensation of the treated area(s)
3. Burning or stinging with the application of topical occlusive balm
4. Burning or stinging sensation with the application of white vinegar soaks
5. Wounds that are not healed after 10 days
6. Dry eyes, inability to close eyes, and eye pain
7. Spreading redness at the periphery of the treated area(s)
8. Fever, chills, nausea, and vomiting
9. Raised areas that may be tender
10. Concern about wound healing progress

Note: Suggested patient information regarding condition(s) that treating physicians should be aware of.

Abbreviation: PDR, plasma dermal resurfacing.

Prophylactic antiviral medication may be started the night before treatment or on the day of treatment and should be continued for at least 1 week. Swabbing the nose with mupirocin 2% ointment (eg, Bactroban; GlaxoSmithKline, Philadelphia, PA) 48 hours before treatment may reduce the risk of methicillin-resistant *Staphylococcus aureus* infections, especially in patients with a recent (<1 year) history of MRSA infection and whose nasal tissues may be colonized.<sup>15</sup> In addition, cleansing the skin immediately before treatment with an antiseptic (eg, Hibiclens; Mölnlycke Health Care, Norcross, GA) is a common practice that is believed to be beneficial. Any alcohol-containing and potentially flammable skin cleansing preparations should be thoroughly removed (eg, using sterile saline moistened gauze) before helium PDR treatment is started. Query of the consensus panel revealed universal incorporation of prophylactic antiviral therapy but a mixed approach with regard to the use of prophylactic antibiotic therapy with approximately half of the group routinely prescribing a 1-week oral antibiotic regimen (eg, cephalexin 500 mg per oral tid); and while none have observed bacterial treatment site infections, thus so far several have observed viral exanthems (presumed HSV) after completion of 7 days of prophylactic antiviral therapy and have, therefore, extended the duration of antiviral prophylaxis to 10 days postprocedure.

Performing a Jessner's peel (eg, salicylic acid 14%, lactic acid 14%, and resorcinol 14%) 4 weeks before treatment may improve the uniformity of the skin's surface texture (eg, epidermal thickness)<sup>16</sup> that could, in theory, improve the uniformity of energy deposition and absorption during treatment, especially considering that impedance of facial skin is nonuniform and that helium plasma energy absorption is in large part dependent on initial and changing skin tissue impedance values.<sup>4,5</sup> Pretreatment of the facial skin with tretinoin (0.025%, 0.05%, or 0.1%) may also be beneficial in that it improves dermal collagen content and increases cell turnover—this "pre-treatment," however, should be part of an ongoing skin maintenance program and should not be started within 3 months of planned helium PDR treatment due to unpredictability of the skin's response at the initiation of therapy that may include inflammation, drying, and peeling.<sup>17</sup>

While pretreatment with oral steroid medication (eg, prednisone) may help us to alleviate some of the edema associated with the acute inflammatory response, oral steroid medication may be given after treatment if needed. Pretreatment of the facial skin with a proprietary tripeptide/hexapeptide combination (TriHex Technology in Alastin Skin Nectar; Alastin Skincare, Inc, Carlsbad, CA) results in significant changes in the extracellular matrix (ECM), dermis, and epidermis that are themselves beneficial (eg, a reversal of the solar elastotic change in ECM, neocollagenesis in the upper dermis, and strengthened and thickened epidermis)<sup>18</sup>; and early clinical data indicate that skin preconditioning with tripeptide/hexapeptide hastens skin healing and patient recovery after energy-based resurfacing treatments.<sup>19</sup> Although pretreatment with hydroquinone 4% topically has been advocated the literature does not support its use for the prevention of PIH.<sup>20</sup>

In some instances, changing conditions before treatment may require postponement of the helium PDR procedure. Prudent reasons for postponing the procedure include active infection in the treatment area or in remote areas (with or without systemic effects), damaged skin barrier from significant sun or wind exposure, new-onset skin conditions, abrasive/exfoliative skin treatments, non-compliance with pretreatment instructions, and excessive anxiety regarding the treatment or recovery.

## 5 | TREATMENT PROTOCOL

*The consensus panel recognizes the need for adjustment of some treatment parameters to optimize outcomes for individual patients' skin conditions and treatment goals—with this in mind, the consensus panel developed these safe start guidelines for helium PDR treatment (Table 2).*

## 6 | ANESTHESIA AND SAFETY CONSIDERATIONS

*The consensus panel emphasizes that topical anesthesia should not be used before helium PDR treatment due to associated changes in skin impedance and related interference with helium plasma energy deposition. The panel also emphasizes the need to protect against the possibility of oxygen ignition if supplemental oxygen is used during treatment and the need to avoid the use of metal shields for eye protection.*

Helium PDR treatment may be performed under oral sedation, intravenous sedation, or general anesthesia. If not under general anesthesia regional, peripheral (ring) and labial blocks as well as tumescent infiltration are needed for patient comfort. If an endotracheal tube (ETT) or laryngeal mask airway (LMA) is used, the exposed (external) portion should be wrapped with a moist towel during treatment, ETT/LMA leaks should be eliminated and oxygen tension in the gas mixture should be reduced. If supplemental oxygen is being delivered via nasal or oral airway, it should be discontinued during helium plasma energy deposition. Use of oral sedation alone or with intramuscular analgesia may obviate the need for supplemental oxygen and thereby enhance the safety of and

**TABLE 2** Safe start guidelines for helium PDR treatment

1. Anesthesia
  - a. No topical anesthesia
  - b. Oral sedation +/- intramuscular analgesia vs IV sedation vs general anesthesia
  - c. Regional, labial, and peripheral "ring" blocks as indicated
  - d. Sequential tumescent infiltration of the treatment area(s)
2. General safety
  - a. Do not use helium PDR technology if implanted electrical device present
  - b. Oral/IV sedation—discontinue supplemental oxygen during helium plasma energy delivery
  - c. General or laryngeal mask anesthesia—reduce oxygen tension in a gas mixture, ensure no ETT/LMA leak, and wrap external part of the airway with a wet towel
  - d. Ensure activated or hot handpiece tip does not touch the patient or anything flammable
  - e. Practice energy delivery technique—focus on treatment speed and homogenous energy deposition
3. Cornea/eye protection
  - a. No metal corneal shields
  - b. For upper eyelid treatment—keep eyelids closed and apply moist gauze over the lower portion of upper eyelids
  - c. For lower eyelid treatment—keep eyelids closed, apply moist gauze over upper eyelids, and use a tongue blade to prevent injury to eyelashes
4. First pass treatment
  - a. Sequentially treat each desired area after appropriately tumesced
  - b. Device settings: 20%-40% power, 4 L/min helium gas flow, pulsing optional, and tip in the retracted position
  - c. Use appropriate techniques for helium plasma energy deposition and "feathering" at the interface between treated and nontreated tissue
5. Second pass treatment
  - a. Wipe away coagulated (desiccated) outer tissue layers after the first pass
  - b. Device settings: 20%-40% power, 4 L/min helium gas flow, pulsing optional, and tip in the retracted position
  - c. Use appropriate techniques for helium plasma energy deposition and "feathering" at the interface between treated and nontreated tissue

*Note:* General safety considerations and treatment guidelines helium plasma dermal resurfacing.

*Abbreviations:* ETT, endotracheal tube; IV, intravenous; LMA; laryngeal mask airway; PDR, plasma dermal resurfacing.

simplify the procedure. Treating physicians should also remember to avoid placing the handpiece near or in contact with flammable materials (eg, surgical drapes) if activated or if hot from use as a fire could result; they should also place the handpiece in a clean dry location away from the patient as inadvertent contact with the patient could result in a thermal injury.

Patient comfort during initial localization and tumescent infiltration will be improved with the addition of sodium bicarbonate (eg, 1 part in 10-20) to 1% or 2% lidocaine-containing 1:100 000 epinephrine. Patient comfort during initial localization and tumescent infiltration may be further enhanced with the brief use of inhaled nitrous oxide (eg, 50% with oxygen 50%). The nitrous oxide-oxygen



gas mixture should not be used during helium plasma energy delivery due to fire risk. Although short-term nitrous oxide exposure is considered to be safe in normal individuals, contraindications for nitrous oxide use include medical conditions that would generally preclude elective cosmetic procedures and prolonged exposure may cause temporary bone marrow suppression.<sup>21</sup> After the initial local anesthesia blocks, the tumescent solution may be infiltrated fully throughout the face or sequentially infiltrated as treatment of different facial regions progresses (eg, infiltrate forehead, then periorbital region and nose, followed by right cheek and then left cheek, and finally ending with the perioral area).

Suggestions for tumescent anesthesia solution included Klein's solution and a lidocaine-bupivacaine-epinephrine solution. Klein's solution is prepared by adding the following to 1 L of normal saline (0.9% NaCl): 100 mL 1% lidocaine 10 mg/mL or 1000 mg, 1 mL 1:1000 epinephrine 1 mg/mL or 1 mg, and 10 mL 8.4% sodium bicarbonate or 10 mEq.<sup>22</sup> Another option given was a lidocaine-bupivacaine-epinephrine solution prepared as follows: 1:1 mixture of 1% lidocaine 10 mg/mL containing 1 100 000 epinephrine and 0.5% plain bupivacaine 5 mg/mL that is then diluted 1:1 with normal saline (0.9% NaCl) for final concentrations of 0.25% lidocaine, 0.125% bupivacaine, and 1:400 000 epinephrine.

Total tumescent volumes used for full-face treatment ranged from 200 to 500 cc for Klein's solution and 75 to 100 cc for the dilute lidocaine-bupivacaine-epinephrine solution with no suggestion that greater or lesser volumes materially impacts comfort or outcomes. Local anesthetic toxicity should never be an issue with local/tumescent infiltration for a full-face helium PDR treatment. Maximum subcutaneous infiltration doses of lidocaine and bupivacaine should not exceed 3 (plain lidocaine) to 6 (lidocaine-containing

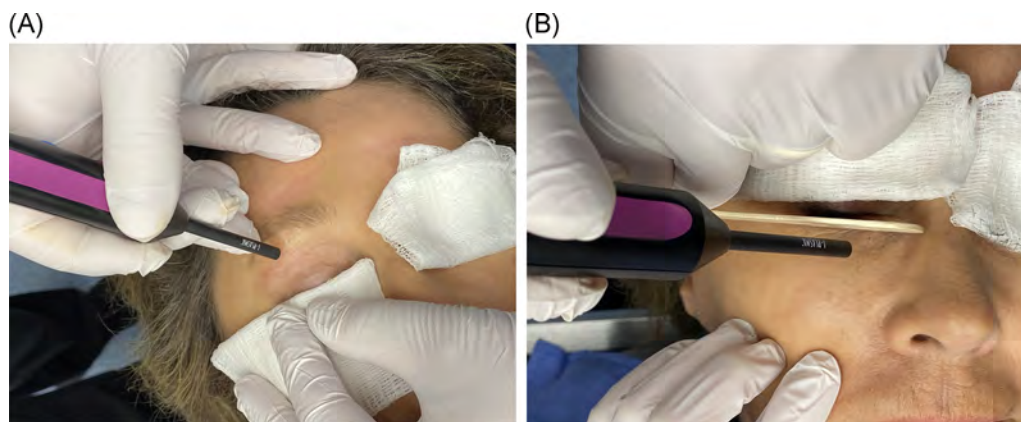
epinephrine) mg/kg and 2 (plain bupivacaine) to 2.5 (bupivacaine containing epinephrine) mg/kg, respectively.<sup>23</sup> Tumescent anesthesia may be administered with an appropriate multihole cannula or 22- to 25-gauge spinal needle.

While polished stainless steel metal shields are often used for cornea/eye protection during ablative laser skin resurfacing procedures, they should not be used with helium PDR treatment of the periorbital region—a nonconducting material should be used with the delivery of helium plasma RF energy to reduce the risk of cornea/eye injury. Another alternative is to keep the eyes closed manually and use folded moist 4 × 4 gauze over the closed eyes only leaving exposed that upper eyelid skin tissue targeted for treatment (Figure 1A). For the lower eyelids, a similar approach may be used, but adding a wooden tongue blade held in place just below the eyelashes (Figure 1B).

## 7 | DEVICE SETTINGS

*The consensus panel currently recommends using a device power setting of 20% to 40% with 4 L/min helium flow and continuous energy delivery (although pulsing not formally recommended some panel members routinely employ slightly higher energy settings and also incorporate pulsing). New users should consider using lower power settings until they are comfortable with the technique. Lower power settings may also be desirable when treating the periorbital area and areas where the skin may be thinner and/or less vascular (eg, periphery of chin, forehead, jawline, and temples).*

Energy density calculations for helium PDR have been determined based on treatment tip movement (velocity) of 1 cm/s over



**FIGURE 1** A, Cornea/eye protection during periorbital helium PDR treatment. Treatment set up for right upper eyelid: the user holds upper eyelid in a closed position with sterile saline moistened folded 4 × 4 gauze over the lower aspect of the eyelid and covering eyelashes. Assistant retracts brow and lower forehead tissue superiorly to fully stretch out infra brow and upper eyelid skin. The user would then treat upper eyelid tissue from lid crease inferiorly to just below brow superiorly. B, Cornea/eye protection during periorbital helium PDR treatment. Treatment set up for right lower eyelid: the user holds upper eyelid in a closed position with sterile saline moistened folded 4 × 4 gauze. The user places a wooden tongue blade just below the ciliary margin keeping eyelashes above and ensuring full contact of the edge of the tongue blade with the skin. Assistant retracts cheek and lower eyelid tissue inferiorly to fully stretch out lower eyelid skin. The user would then treat lower eyelid tissue from immediately adjacent tongue blades superiorly to inferiorly to just the desired inferior extent of treatment. PDR, plasma dermal resurfacing

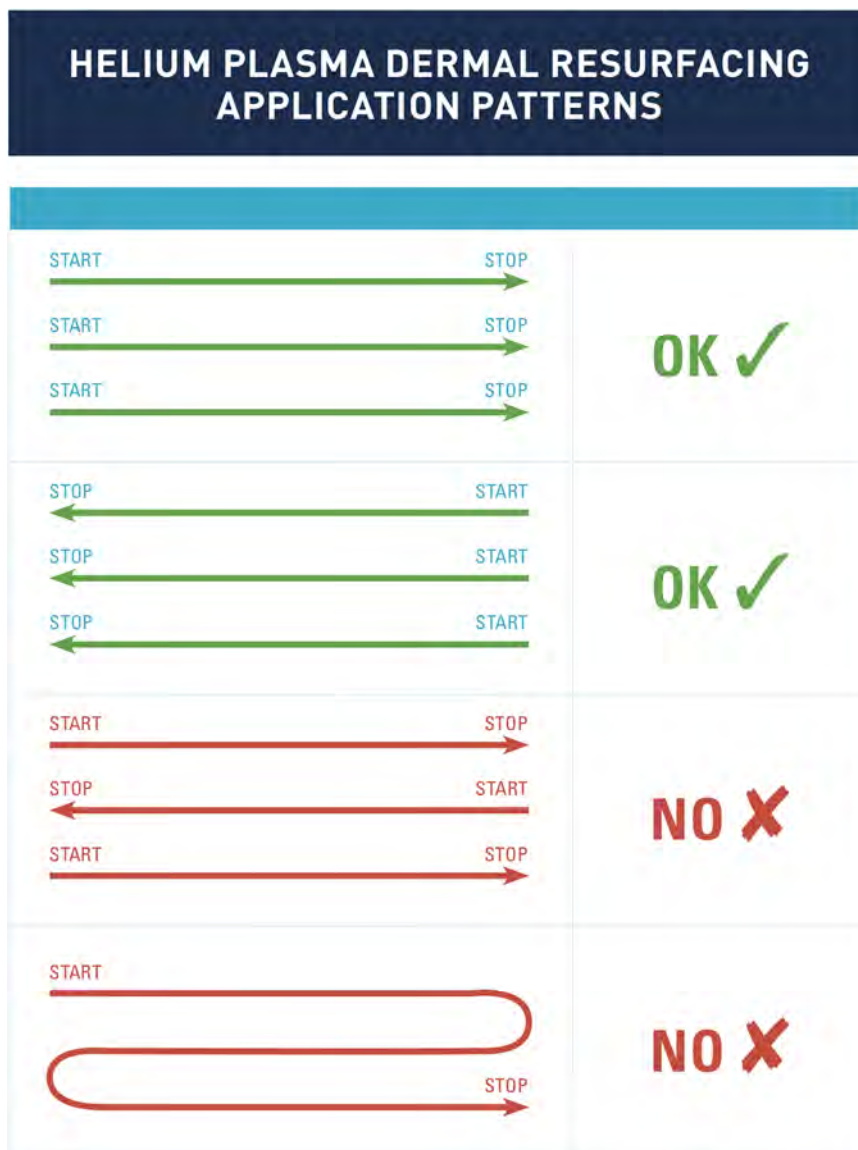the tissue.<sup>4</sup> An inverse relationship exists between treatment tip velocity and energy density—treating the tissue too slowly may increase the risk of complications, while treating the tissue too quickly may reduce treatment effectiveness. Users can easily gauge treatment tip velocity during helium PDR treatments by using a centimeter ruler and recording video during linear energy deposition over a set distance (eg, 5 cm); dividing the linear treatment distance by the time needed to cover this distance determines treatment tip velocity. In general, it may not be advantageous to slow treatment tip velocity too much below 1 cm/s. While no formal recommendation regarding the use of pulsing was made by the consensus panel, at this time, some users are incorporating this additional variable into their treatment paradigms. Compared to no pulsing, that is, continuous energy deposition, implementing equal pulsing on and pulsing off parameters (eg, 20 ms on and 20 ms off) will reduce energy density by 50%. Increasing pulsing on time vs pulsing off time will incrementally bring energy density back up closer to that without

pulsing. So, decreasing treatment tip velocity below 1 cm/s and implementing pulsing have opposite effects on energy density that could potentially be canceled with no net change.

As users become more comfortable with helium PDR treatment, the choice of treatment parameters for various skin conditions and treatment goals will become second nature. The consensus panel again recommends that new users adopt a conservative approach to the treatment of the periorbital area and peripheral transition zones.

## 8 | ENERGY APPLICATION/DEPOSITION

*The consensus panel recommends linear nonoverlapping unidirectional treatment passes (Figure 2) with appropriate treatment parameters and tip velocity to result in even coagulation of superficial skin layers and a uniform white frosted appearance after the initial pass. Desiccated tissue*



**FIGURE 2** Proper helium plasma application pattern. Examples of proper (green lines) and improper (red lines) helium plasma dermal resurfacing energy application patterns. Following these guidelines is suggested to avoid the potential for undesirable increases in energy density at the ends of treatment rows

*should be wiped away between the initial and second pass if more than one pass is planned. While the method of energy application/deposition should be the same for the second-pass skin tissue, interaction is different from the initial pass with a temporary white blanching of tissue and no well-defined linear markings visible. Concurrent treatment with other facial rejuvenation procedures appears to be safe but treatment should be avoided or significantly moderated over areas of superficial skin tissue undermining.*

While handpiece movement (tip velocity) should be reasonably consistent, treatment tip to skin surface distance does not affect energy density significantly, that is, within the range of RF device to skin surface coupling there is no significant increase or decrease in energy density as the treatment tip moves closer to or farther away from the skin surface. Movement of the treatment tip is far enough away from the skin surface such that it is beyond the maximum RF coupling distance will sever the RF bridge and eliminate any effect on the skin.

With appropriate technique and device settings, the initial pass will result in a light white frosting of the tissue, and the treatment lines will have a consistent width of approximately 3 mm. If darker brownish spots are observed, treatment speed may be too slow such that focal increases in energy density and charring occur; if observed treatment speed should be increased. Uneven frosting of the tissue and treatment lines that are thin or that vary in width may also occur if treatment speed is too fast or inconsistent, respectively. Skip zones with untreated tissue between treatment lines are another indication of nonhomogenous energy delivery. If observed, treatment speed should be reduced to obtain the desired even white frosting of the tissue and consistent treatment line width. Slow treatment speeds may increase the risk of adverse events related to excessive energy density (eg, delayed wound healing and hypertrophic scarring). Fast treatment speeds may result in inconsistent treatment results and decreased likelihood of meeting treatment goals.

Three helium PDR treatment paradigms are possible: single pass, multipass, and a mixture of single and multipass. Single-pass treatment is similar to that of the predicate nitrogen PSR technology, where the desiccated outer layers of skin should be left in place during healing.<sup>6</sup> As the "old" treated skin desquamates the newly regenerated pink, "new" skin becomes apparent. For multipass treatment, the desiccated outer skin tissue layers from the first pass should be removed by wiping with gentle pressure using saline-soaked gauze pads before proceeding with the second treatment pass. After removal of all desiccated tissue, a dry gauze pad should be used to dry the tissue thoroughly before proceeding with treatment.

During the second-pass linear treatment, lines may not be visible and no frosting from extensive coagulation of epidermal tissue occurs; instead, the user should expect a pale appearance or blanching of the tissue in addition to the visible contraction of the tissue during treatment. No wiping of the treated tissue surface is necessary after the second pass. Although the second pass may be performed with a perpendicular orientation to the first pass, it is not necessary. It is important, however, to use the proper application pattern during the second and any additional treatment passes; after completing

one treatment line, the next treatment line should begin adjacent to the starting point of the previous treatment line. Special care should be taken not to overlap treatment lines but also to avoid gaps between treatment lines (Figure 2).

The panel also provided the following pearls of experience related to helium PDR treatment. With the treatment of the eyelids, very significant improvement typically results from a single pass; additional tissue contraction will result from an additional pass. Deep glabellar furrows may respond favorably to multipass treatment but typically not from single-pass treatment. Optimum improvement of deep cheek rhytids and skin laxity may require two passes. Similarly, deep lip and perioral lines require more aggressive treatment with two or more passes and with treatment parameters that increase energy density. Atrophic, elongated lobules may respond quite well to lower power (eg, 20%) multipass (eg, four passes) treatment. Transition zone "feathering" (see further description following) is important to the minimize risk of inadvertent energy density-related complications in areas where the skin is thinner and/or may be less vascular (eg, temples, caudal border of the mandible to the neck).

Some members of the panel had experience and were comfortable with concurrent helium PDR treatment and various facial rejuvenation procedures. As with laser skin resurfacing<sup>24</sup> and the nitrogen plasma-based predicate device,<sup>25</sup> helium PDR may be safely performed concurrently with a browlift and facelift procedures. Depending on the depth and extent of tissue undermining of the mid- and lower facial tissue during facelift procedures, both power and depth of treatment should be limited (eg, <30% power and single pass only) over the facelift flaps. Treatment of the perioral area where no undermining is present can be done more aggressively as needed to address lip lines and peri-oral wrinkles. The panel recommended against concurrent treatment with injectables including neuromodulators, fillers, and fat grafting unless performed in areas that are not undergoing helium PDR (eg, upper facial injectables with perioral helium PDR treatment).

## 9 | POSTTREATMENT HEALING REGIMEN

*The consensus panel recommends careful attention to posttreatment healing instructions that include head elevation until any initial inflammatory edema subsides, occlusive balm applied to the treated skin, vinegar soaks and tepid to cool showers multiple times each day, and transitioning to a light moisturizer after re-epithelialization is complete.*

Patient-healing responses to helium PDR treatment vary and should be carefully monitored by the treating physician and his/her clinical staff. Depth of treatment will be affected by skin impedance and thickness, power, treatment speed, pulsing, and a number of passes. While the number of days required for complete re-epithelialization may take longer with deeper treatments, single-pass treatment at a lower power level (eg, 20%) should be achieved within 10 days after treatment.<sup>6</sup> Although pretreatments with either topical tretinoin 0.1% cream<sup>26</sup> or tripeptide/hexapeptide<sup>19</sup> are thought to be beneficial for expediting re-epithelialization after full-field ablative



laser and ablative fractional CO<sub>2</sub> laser resurfacing, it is not yet clear whether these pretreatment skin preconditioning regimes have similar effects after helium PDR. And while use of tripeptide/hexapeptide immediately after ablative or nonablative fractional laser resurfacing does appear to improve healing,<sup>27-29</sup> similar studies supporting the use of tripeptide/hexapeptide immediately after full-field deep laser skin resurfacing are lacking and the consensus panel does not currently recommend the use of tripeptide/hexapeptide during the initial recovery period (before re-epithelialization) following helium PDR. Some areas of the skin typically heal faster than others, even within the same treatment region of the face. As healing progresses, it is permissible to transition to the use of a light moisturizer for areas that are re-epithelialized while continuing use of the occlusive ointment (eg, Aquaphor Healing Ointment; Beiersdorf AG, Hamburg, Germany) over focal areas that are continuing to heal.

Most patients experience pruritis during initial healing that is improved with the use of dilute white vinegar soaks multiple times each day (eg, as much as every several hours) for 20 to 30 minutes each time. To make a vinegar-water soak, fill a clean bowl with cold tap water and a few ice cubes and one tablespoon of white vinegar for every cup of water. Clean 4 × 4 gauze are wetted with the dilute white vinegar solution and then applied to the treated areas of the face; wetted gauze should be replaced with new wet gauze before they dry (alternatively, the dilute white vinegar solution may be repeatedly dripped over the gauze). The soak should not sting—if so, make sure that the recipe was followed properly and that the white vinegar component is not more than called for. Make sure the dilute white vinegar solution stays chilled and replace when warm. Latex or latex-free gloves should be worn during application of vinegar soaks and occlusive dressing application. More significant pruritis may require the addition of an oral H1 receptor antagonist (eg, hydroxyzine 25 mg per oral q12 hours) and, if severe, patients may be advised to wear mittens or socks over their hands during sleep to prevent unintended secondary wounding.

During the posttreatment phase, treating physicians should be alerted to any unexplained pain or burning sensations, any erosion or deep ulceration of the treated skin, pain or tenderness in the treatment area, and any systemic flu-like symptoms (eg, fever, chills, headache, myalgia, nausea, vomiting, and malaise). While treating physicians should strive to deliver homogenous treatments wherein tissues are treated uniformly, focal areas with deeper effect may occur following treatment if the energy density delivered to the tissue inadvertently exceeds the threshold for normal tissue repair.

While initial wound healing may be complete within 10 days, more time may be required with deeper treatment with these areas taking as long as more than 2 weeks for full re-epithelialization. After initial healing (or even if a few small areas are continuing to heal), patients may use a mineral-based camouflage and/or tinted sunblock to conceal erythema and protect from UV radiation. Several on the consensus panel suggested relatively early use (after initial re-epithelialization) of a proprietary tripeptide/hexapeptide combination (TriHex Technology in Alastin Skin Nectar; Alastin Skincare, Inc) to help reduce

inflammation and redness as well as promote efficient neocollagenesis and neoelastogenesis. Recognizing the potential for postlaser skin hypersensitivity,<sup>30</sup> the consensus panel specifically recommended the use of physical UVA/B blocking sunscreens (eg, titanium dioxide- and/or zinc oxide-containing) rather than products with potentially irritating ingredients (eg, avo/oxybenzone, various antioxidants) as well as avoiding topicals containing alpha- and beta-hydroxy acids and retinols until at least several months after initial healing. Similarly, they recommended avoiding facial skin-care treatments that are abrasive for at least 3 months after initial healing.

Digital photographs should be captured at the various stages of the healing process as well as pretreatment and 1-, 3-, and 6-months posttreatment. Photodocumentation of the subject's progress during healing can be a valuable tool to gauge progress and assess response to modifications of the posttreatment healing regimen.

## 10 | AVOIDANCE AND MANAGEMENT OF COMPLICATIONS AND SIDE EFFECTS

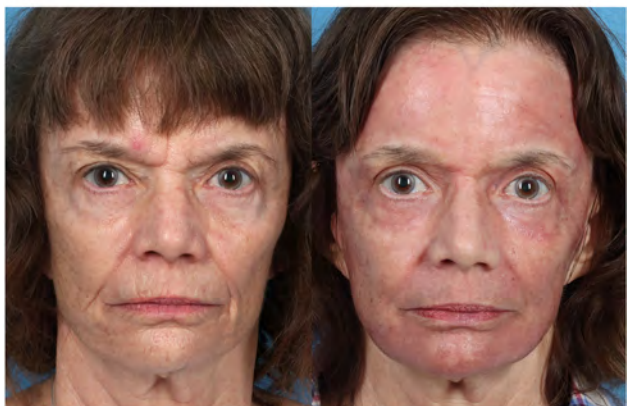*The consensus panel recommends vigilance on the part of the treating physician and his/her staff to identify and respond to any potential complications or side effects with appropriate timeliness.*

It is the consensus panel's experience that the most commonly encountered side effects following helium PDR include initial acute posttreatment edema and pruritis, prolonged erythema lasting several months or longer, milia formation, and PIH. Less common side effects include delayed wound healing in focal areas requiring 2 or more weeks for re-epithelialization and telangiectasia formation.

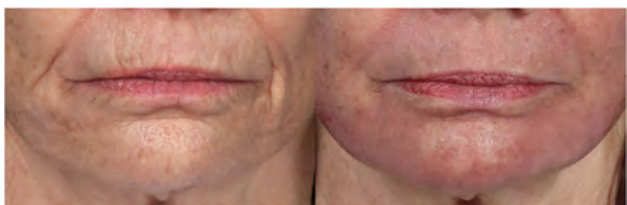Complications that have been encountered by the consensus panel include hypertrophic scarring, exacerbation of acne, reactivation of latent herpes simplex, and hypopigmentation. Any of the side effects and complications may occur after an appropriately conducted treatment and with appropriate compliance with the post-treatment healing regimen.

While postlaser erythema may be partially mitigated with dual-wavelength phototherapy<sup>31</sup> or temporarily reduced with topical alpha adrenergics (eg, brimonidine tartrate 0.33% gel and oxymetazoline hydrochloride 1% cream) gradual incremental reduction of erythema intensity toward baseline is expected within 3 to 6 months even without adjunctive treatment.<sup>32</sup> Milia formation may occur as a result of disruption of follicular units during treatment, aberrant follicular re-epithelialization during healing, and may be compounded with the use of occlusive moisturizers.<sup>33</sup> Use of enzymatic cleansers may help us to alleviate milia formation although unresponsive milia may require gentle debridement. PIH may become evident as soon as 4 to 6 weeks after treatment. While avoiding early treatment with hydroquinone may be desirable, some members of the consensus panel have successfully used a proprietary hydroquinone-free topical containing tranexamic acid and phenylethyl resorcinol (Lytera 2.0 Pigment Correcting Serum; SkinMedica Inc, An Allergan Company, Carlsbad). Prolonged wound healing may require the continuation of a topical occlusive ointment or topical silver sulfadiazine for focal

(A)



(B)



**FIGURE 3** A, Full-face helium plasma dermal resurfacing. B, Perioral close-up. Left, before treatment. Right, 6 weeks after full-face helium plasma dermal resurfacing. Treatment parameters for first pass included full-face treatment at 20% power, 4 L/min helium gas flow, and 20 ms on and 20 ms off pulsing. After wiping away desiccated surface tissue, a second pass (40% power, 4 L/min helium flow, and 20 ms on and 20 ms off pulsing) was made over the glabella, upper eyelids, and perioral areas. Notice (1) improvement of medial brow position with greater visibility of upper eyelids; (2) improvement of lip lines and perioral folds; (3) continuing erythema of areas where the skin is thin and/or a second pass was made; and (4) residual focal dyschromia in the cheek areas where treatment depth was limited by a single treatment pass

areas with superficial dry crusts. Wounds that remain open and moist may benefit from allograft or xenograft (eg, Cytal Wound Matrix 1-Layer; ACell, Columbia, MD) sheets. Telangiectasias may appear with robust neovascularization during the inflammatory phase of wound healing. Telangiectasias generally respond well to treatment with lasers of appropriate wavelengths.

Reactivation of latent herpes simplex is typically relatively easily managed with appropriate oral and topical medications; more severe cases that seem to be worsening despite oral and topical medications may also require intravenous antiviral therapy, infectious disease evaluation, and hospitalization.<sup>13</sup> Any involvement of the conjunctiva (palpebral or scleral) should also prompt immediate evaluation by an ophthalmologist. Although often self-limited exacerbation of acne (transient acneiform eruption) may require adjustment to a less occlusive (noncomedogenic) topical as well as oral antibiotic therapy.<sup>33</sup>

Relative hypopigmentation may occur immediately after laser skin resurfacing treatments that remove accumulated melanin in treated skin that is juxtaposed to darker nontreated skin—the condition is

generally temporary with more superficial laser treatments. Permanent hypopigmentation appears several to many months after laser skin resurfacing and is more likely with deeper and more aggressive treatments (eg, higher power, multiple passes) in subjects with more extensive pretreatment rhytidosis and darker skin tones and in those who realize a greater degree of improvement in rhytidosis.<sup>34–36</sup> Although the precise etiology of postlaser resurfacing hypopigmentation is unknown, it has been suggested that a decrease in melanocyte number, decrease in melanosome synthesis, or impairment of melanosome transfer may be causal.<sup>37</sup> Although complete normalization of severe laser-induced hypopigmentation is not possible, presently several groups have reported improvement with ablative and non-ablative fractional laser treatment protocols.<sup>38,39</sup>

Hypertrophic scarring is more likely in subjects that are known keloid scar formers and in treatment areas where the skin tissue is thin and/or less vascular (eg, lower eyelid, lower margin of mandible and chin, especially after facelift surgery wherein neck skin has been transposed to and/or above the jawline)—caution is advised when treating these subjects and potentially more permissive skin tissues.<sup>40,41</sup> Hypertrophic scarring may occur following treatment wherein the energy density delivered to the tissue inadvertently exceeds the threshold for normal tissue repair. While a single pass may be adequate for the treatment of the eyelids, a second pass may be warranted in cases with more significant dermatochalasis and tissue laxity.

“Feathering” in the traditional sense with respect to laser skin resurfacing wherein the surface effect can be reduced significantly by moving the handpiece farther away from the tissue (increasing the spot size) cannot be performed with helium PDR. If the handpiece is moved beyond the maximum RF coupling distance, no tissue effect will occur. So “feathering” with helium PDR can be accomplished via lowering the power setting, increasing treatment speed, or implementation of pulsing; more than one of these treatment parameters may be altered at the same time. In addition, the RF bridge should be intentionally severed before moving beyond the transition zone onto tissue that is not designated for treatment.

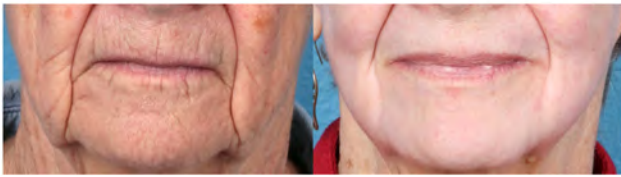If hypertrophic scarring occurs and remains untreated permanent scarring may result. Hypertrophic scars may respond to intralesional steroid (eg, triamcinolone) or antimetabolite (eg, 5-fluorouracil) therapy as well as topical silicone preparations (eg, gels or sheets).

Caution should be exercised when treating the periorbital area in subjects with pre-existing lagophthalmos, prior upper or lower eyelid blepharoplasty, lower eyelid malposition, significant lateral canthal, and lower eyelid laxity and xerophthalmia. Treatment of the upper eyelid area should be avoided if lagophthalmos is present. Conservative treatment is advisable in subjects that have undergone prior upper or lower eyelid surgery and where additional tightening may seem likely to cause lagophthalmos or lower eyelid malposition. Pretreatment or concurrent correction of lower eyelid malposition or lateral canthal laxity may prevent worsening or development of lower eyelid malposition related to skin tissue contraction from helium PDR treatment. Subjects with dry eye syndrome should not undergo aggressive periorbital helium PDR treatment.

(A)



(B)



**FIGURE 4** A, Full-face helium plasma dermal resurfacing. B, Perioral close-up. Left, before treatment. Right, 6 months after prophylactic lower eyelid lateral canthoplasty and full-face helium plasma dermal resurfacing. Treatment parameters for first pass included full-face treatment to mandibular line inferiorly with 50% power, 4 L/min helium gas flow, and 60 ms on and 20 ms off pulsing. After wiping away desiccated surface tissue, a second pass (50% power, 4 L/min helium gas flow, and 80 ms on and 20 ms off pulsing) was made over the cheeks and perioral areas. Notice (1) improvement of dyschromia over forehead, cheeks, and nose; (2) improvement of lip lines; and (3) significant skin tissue contraction and remodeling over cheeks and perioral area as well as along jawline

## 11 | CONSENSUS GUIDELINES SUMMARY

Helium PDR treatment indications, contraindications, pretreatment and safety considerations, posttreatment healing regimen, and side effects and complications are similar to those for ablative laser skin resurfacing. The presence of an implantable pacemaker is a unique contraindication for the new helium plasma-based technology due to the requirement for patient grounding for effective RF tissue coupling. Although the use of topical anesthetic is optional for ablative laser skin resurfacing, topical anesthesia should not be used with helium PDR due to its impact on skin surface impedance and energy absorption. Treatment technique for helium PDR's bimodal energy deposition differs from both the predicate nitrogen PSR technology and ablative laser skin resurfacing; the helium PDR treatment tip must be held close enough to the skin to maintain the integrity of the RF bridge and tissue coupling and the treatment is dynamic with continuous movement of the handpiece over the tissue at an appropriate speed. While the concept of "feathering" is applicable, it is accomplished in a very different manner than with ablative lasers.

Initial appearance and healing after single-pass helium PDR are similar to that of the predicate nitrogen PSR treatment with initial

frosting or darkening of desiccated outer skin layers that remain intact as a natural biological dressing during initial healing. Initial appearance and healing after double- or multipass helium PDR are similar to deep ablative laser skin resurfacing. Continued improvement may occur for at least 3 to 6 months after helium PDR with gradual additional skin texture changes that in some cases are very easily discernible upon the comparison of pre- and posttreatment photographs.

The new helium PDR technology offers the potential for very substantial skin tissue contraction and tightening (Figures 3 and 4) on a platform that also performs basic monopolar and bipolar cautery functions and that with a different handpiece also enables significant subdermal tissue contraction.

## ACKNOWLEDGMENT

The activity in this study was supported by Apyx Medical Corporation, Clearwater, FL.

## CONFLICT OF INTERESTS

Consensus panel members' disclosed holdings in Apyx Medical Corporation include privately purchased stock (Joseph B. DeLozier and Richard Gentile) and stock options (exercised: Joseph B. DeLozier; not exercised Diane Duncan, Richard Gentile, Paul G. Ruff, and Edward Zimmerman). J. David Holcomb is a consultant for Apyx Medical Corporation as well as a principal investigator for a previously concluded helium plasma dermal resurfacing study. J. David Holcomb and Michael Lin are principal investigators for an ongoing helium plasma dermal resurfacing study, both sponsored by Apyx Medical Corporation.

## ORCID

John David Holcomb  <http://orcid.org/0000-0002-5402-9779>

## REFERENCES

1. Kilmer S, Semchyshyn N, Shah G, Fitzpatrick R. A pilot study on the use of a plasma skin regeneration device (Portrait® PSR3) in full facial rejuvenation procedures. *Lasers Med Sci*. 2007;22(2): 101-109.
2. Foster KW, Moy RL, Rincher FF. Advances in plasma skin regeneration. *J Cosmet Dermatol*. 2008;7(3):169-179.
3. Elsaie ML, Kammer JN. Evaluation of plasma skin regeneration technology for cutaneous remodeling. *J Cosmet Dermatol*. 2008;7(4): 309-311.
4. Holcomb JD, Schucker A. Helium plasma skin regeneration: evaluation of skin tissue effects in a porcine model and comparison to nitrogen plasma skin regeneration. *Lasers Surg Med*. 2019;52:23-32. <https://doi.org/10.1002/lsm.23167>
5. Holcomb JD. Plasma energy skin rejuvenation. *Facial Plast Surg Clin North Am*. 2020;28:67-74. <https://doi.org/10.1016/j.fsc.2019.09.006>
6. Holcomb JD, Kelly M, Hamilton TK, DeLozier JB, III. (2020). A prospective study evaluating the use of helium plasma for dermal resurfacing. *Lasers Surg Med*. <https://doi.org/10.1002/lsm.23257>
7. Gentile RD, McCoy JD. Pulsed and fractionated techniques for helium plasma energy resurfacing. *Facial Plast Surg Clin North Am*. 2020;28(1): 75-85. <https://doi.org/10.1016/j.fsc.2019.09.007>
8. Fabi SG, Joseph J, Sevi J, Green JB, Peterson JD. Optimizing patient outcomes by customizing treatment with microfocused ultrasound



- with visualization: gold standard consensus guidelines from an expert panel. *J Drugs Dermatol*. 2019;18:426-432.
9. Goldie K, Peeters W, Alghoul M, et al. Global consensus guidelines for the injection of diluted and hyper-diluted calcium hydroxylapatite for skin tightening. *Dermatol Surg*. 2018;44:S32-S41.
  10. Ozog DM, Rkein AM, Fabi SG, et al. Photodynamic therapy: a clinical consensus guide. *Dermatol Surg*. 2016;42:804-827.
  11. Carruthers J, Burgess C, Day D, et al. Consensus recommendations for combined aesthetic interventions in the face using botulinum toxin, fillers, and energy-based devices. *Dermatol Surg*. 2016;42: 586-597.
  12. Bertossi D, Cavallini M, Cirillo P, et al. Italian consensus report on the aesthetic use of onabotulinum toxin A. *J Cosmet Dermatol*. 2018;17: 719-730.
  13. Waldman A, Bolont D, Arndt KA, et al. ASDS guidelines task force: consensus recommendations regarding the safety of lasers, dermabrasion, chemical peels, energy devices, and skin surgery during and after isotretinoin use. *Dermatol Surg*. 2017;43:1249-1262.
  14. Alster TS, Nanni CA. Famciclovir prophylaxis of herpes simplex virus reactivation after laser skin resurfacing. *Dermatol Surg*. 1999;25(3): 242-246.
  15. Perl TM, Cullen JJ, Wenzel RP, et al. Intranasal mupirocin to prevent postoperative *Staphylococcus aureus* infections. *N Engl J Med*. 2002; 346:1871-1877. <https://doi.org/10.1056/NEJMoa003069>
  16. Soleymani T, Lanoue J, Rahman Z. A practical approach to chemical peels. *J Clin Aesthet Dermatol*. 2018;11(8):21-28.
  17. Mukherjee S, Date A, Patravale V, Korting HC, Roeder A, Weindl G. Retinoids in the treatment of skin aging: an overview of clinical efficacy and safety. *Clin Interv Aging*. 2006;1(4):327-348. <https://doi.org/10.2147/cia.2006.1.4.327>
  18. Widgerow AD, Jiang L, Calame A. A single-center clinical trial to evaluate the efficacy of a tripeptide/hexapeptide antiaging regimen. *J Cosmet Dermatol*. 2019;18(1):176-182. <https://doi.org/10.1111/jocd.12507>
  19. Widgerow AD, Cohen SR, Fagien S. Preoperative skin conditioning: extracellular matrix clearance and skin bed preparation, a new paradigm. *Aesthet Surg J*. 2019;39(S3):S103-S111. <https://doi.org/10.1093/asj/sjz022>
  20. West TB, Alster TS. Effect of pretreatment on the incidence of hyperpigmentation following cutaneous CO<sub>2</sub> laser resurfacing. *Dermatol Surg*. 1999;25(1):15-17. <https://doi.org/10.1046/j.1524-4725.1999.08123.x>
  21. Young A, Ismail M, Papatsonis AG, Barua JM, Callearly JG, Masood J. Entonox Inhalation to reduce pain in common diagnostic and therapeutic outpatient urological procedures: a review of the evidence. *Ann R Coll Surg Engl*. 2012;94(1):8-11. <https://doi.org/10.1308/003588412X1317121499702>
  22. Klein JA, Jeske DR. Estimated maximal safe dosages of tumescent lidocaine. *Anesth Analg*. 2016;122(5):1350-1359. <https://doi.org/10.1213/ANE.0000000000001119>
  23. Williams DJ, Walker JD. A nomogram for calculating the maximum doses of local anesthetic. *Anaesthesia*. 2014;69:847-853. <https://doi.org/10.1111/anae.12679>
  24. Koch BB, Perkins SW. Simultaneous rhytidectomy and full-face carbon dioxide laser resurfacing: a case series and meta-analysis. *Arch Facial Plast Surg*. 2002;4(4):227-233. <https://doi.org/10.1001/archfaci.4.4.227>
  25. Holcomb JD, Kent JK, Rousso DE. Nitrogen plasma skin regeneration and aesthetic facial surgery: multicenter evaluation of concurrent treatment. *Arch Facial Plast Surg*. 2009;11(3):184-193. <https://doi.org/10.1001/archfaci.2009.29>
  26. Buchanan PJ, Gilman RH. Retinoids: literature review and suggested algorithm for use prior to facial resurfacing procedures. *J Cutan Aesthet Surg*. 2016;9(3):139-144. <https://doi.org/10.4103/0974-2077.191653>
  27. Vanaman Wilson MJ, Bolton J, Fabi SG. A randomized, single-blinded trial of a tripeptide/hexapeptide healing regimen following laser resurfacing of the face. *J Cosmet Dermatol*. 2017;16(2):217-222. <https://doi.org/10.1111/jocd.12339>
  28. Robinson DM, Frulla AP. Randomized, split-face/decollate comparative trial of procedure enhancement system for fractional non-ablative laser resurfacing treatment. *J Drugs Dermatol*. 2017;16(7): 707-710.
  29. Nelson AM, Ortiz AE. Effects of anhydrous gel with TriHex peptides on healing after hybrid laser resurfacing. *J Cosmet Dermatol*. 2020; 19(4):925-929. <https://doi.org/10.1111/jocd.13270>
  30. Widgerow AD, Braun SA. Post-laser hypersensitivity and the atopic patient. *Plast Reconstr Surg*. 2000;106(1):155-159. <https://doi.org/10.1097/00006534-200007000-00031>
  31. Trelles M, Elman M, Slatkine M, Harth Y. Accelerated reduction of post-skin-resurfacing erythema and discomfort with a combination of non-thermal blue and near infrared light. *J Cosmet Laser Ther*. 2005; 7(2):93-96. <https://doi.org/10.1080/14764170500237316>
  32. Braun SA, Artzi O, Gerber PA. Brimonidine tartrate 0.33% gel for the management of posttreatment erythema induced by laser skin resurfacing. *J Am Acad Dermatol*. 2017;76(2):e53-e55. <https://doi.org/10.1016/j.jaad.2016.10.020>
  33. Metelitsa AI, Alster TS. Fractionated laser skin resurfacing treatment complications: a review. *Dermatologic Surg*. 2010;36(3):299-306. <https://doi.org/10.1111/j.1524-4725.2009.01434.x>
  34. Bernstein LJ, Kauvar AN, Grossman MC, Gernonemus RG. The short- and long-term side effects of carbon dioxide laser resurfacing. *Dermatol Surg*. 1997;23(7):519-525. <https://doi.org/10.1111/j.1524-4725.1997.tb00677.x>
  35. Kim YJ, Lee H-S, Son W-W, Kim S-N, Kye Y-C. Analysis of hyperpigmentation and hypopigmentation after Er:YAG laser skin resurfacing. *Lasers Surg Med*. 2005;36(1):47-51. <https://doi.org/10.1002/lsm.20120>
  36. Ward PD, Baker SR. Long-term results of carbon dioxide laser resurfacing of the face. *Arch Facial Plast Surg*. 2008;10(4):238-243. <https://doi.org/10.1001/archfaci.10.4.238>
  37. Vachiramon V, Thadanipon K. Postinflammatory hypopigmentation. *Clinical Dermatol*. 2011;36(7):708-714. <https://doi.org/10.1111/j.1365-2230.2011.04088.x>
  38. Tierney EP, Hanke CW. Treatment of CO<sub>2</sub> laser induced hypopigmentation with ablative fractional laser resurfacing: case report and review of the literature. *J Drugs Dermatol*. 2010;9(11):1420-1426.
  39. Mautari AB, Fabi SG, Fitzpatrick R. Repigmentation of hypopigmented scars using an erbium-doped 1,550-nm fractionated laser and topical bimatoprost. *Dermatologic Surg*. 2012;38(7):995-1001. <https://doi.org/10.1111/j.1524-4725.2012.02389.x>
  40. Fife DJ, Fitzpatrick RE, Zachary CB. Complications of fractional CO<sub>2</sub> laser resurfacing: four cases. *Lasers Surg Med*. 2009;41(3):179-184. <https://doi.org/10.1002/lsm.20753>
  41. Avram MM, Tope WD, Yu T, Szachowicz E, Nelson JS. Hypertrophic scarring of the neck following ablative fractional carbon dioxide laser resurfacing. *Lasers Surg Med*. 2009;41(3):185-188. <https://doi.org/10.1002/lsm.20755>

**How to cite this article:** Holcomb JD, Duncan D, Lin M, et al. Helium plasma dermal resurfacing: Consensus guidelines. *Dermatological Reviews*. 2020;1-11. <https://doi.org/10.1002/der.2.22>