

Safety and efficacy of helium plasma for subdermal coagulation

Paul G. Ruff IV, MD¹  | Vaishali Doolabh MD² | Edward M. Zimmerman MD³  | Richard A. Gentile MD, MBA⁴

¹West End Plastic Surgery, Washington, District of Columbia, USA

²Contemporary Plastic Surgery, Jacksonville, Florida, USA

³Aesthetic Revolution Las Vegas, Las Vegas, Nevada, USA

⁴Gentile Facial Plastic and Aesthetic Laser Center, Youngstown, Ohio, USA

Correspondence

Edward M. Zimmerman, Aesthetic Revolution Las Vegas, 9130 W. Post Rd, Suite 100, Las Vegas, NV 89148, USA.

Email: dr.z@me.com

Abstract

Background: Surgical and nonsurgical treatments or procedures are often combined to achieve desired aesthetic results. A novel helium-based plasma device has recently been developed to briefly heat soft tissue which coagulates collagen and achieves additional tissue contraction through neocollagenesis and tissue remodeling. Two chart reviews were performed on patients who had undergone liposuction combined with helium plasma treatment.

Objectives: The primary objective was to evaluate the safety of these combined procedures. Secondary objectives were to assess aesthetic improvements and overall subject satisfaction.

Methods: Both studies retrospectively reviewed medical records for adult subjects undergoing a subdermal coagulation procedure with the helium plasma device following liposuction. One review included pre- and posttreatment subject images and subject satisfaction.

Results: Study 1 identified 37 subjects who were male ($n = 6$) and female ($n = 31$), 21–70-years old with a mean body mass index (BMI) of 27 kg/m^2 (range, $18\text{--}41 \text{ kg/m}^2$). Study 2 identified 148 eligible subjects. Most subjects were female ($n = 120$), 21–84-years old with a mean BMI of 27 kg/m^2 (range, $18\text{--}44 \text{ kg/m}^2$). Mean plasma generator settings were 70% power, mean helium flow was 3 L/min with four to six passes per area. Among subjects with efficacy data, most subjects (77%) reported aesthetic improvement and were happy with their results, would recommend to a friend, and would consider having their procedure repeated (68%). Overall satisfaction was achieved by 74%.

Conclusions: These results suggest helium plasma is a safe and effective adjunct therapy when used in combination with liposuction.

KEYWORDS

aesthetic improvements, helium plasma, liposuction, safety

This is an open access article under the terms of the Creative Commons Attribution License, which permits use, distribution and reproduction in any medium, provided the original work is properly cited.

© 2020 John Wiley & Sons Ltd

1 | INTRODUCTION

The number of cosmetic procedures performed annually continues to grow, reaching 17.7 million in 2019, an increase of 163% since 2000.¹ Surgical procedures have a long history of aesthetic applications including skin rejuvenation^{2,3} and an increasing number of pharmacologic agents, devices, and energy-based rejuvenation has become available. Many of these procedures are being combined to improve therapeutic outcomes^{4,5} in different anatomical areas.^{6,7} Treatment combinations include toxins and fillers,⁸⁻¹⁰ fillers and energy-based therapies,¹¹⁻¹³ different energy-based therapies^{14,15} and combining surgical procedures with skin resurfacing, intense pulsed light, and neuromodulators.¹⁶ Consensus recommendations have been developed for many of these treatment combinations.^{6,7}

Liposuction is a surgical procedure intended to reduce and smooth the contours of the body and improve individual appearance. Liposuction can dramatically improve contours but it does not tighten skin, relying on normal skin retraction.¹⁷ Skin in certain areas of the body is prone to developing skin redundancy or laxity following liposuction.¹⁸

A novel helium-based plasma device is a recent addition to aesthetic surgical procedures. Helium plasma achieves soft tissue contraction by briefly heating tissue to temperatures greater than 85°C.¹⁹ The result of heating collagen is coagulation and immediate contraction of collagen fibers^{20,21} by up to 38%.²² The subsequent wound-healing response results in additional tissue contraction through neocollagenesis and tissue remodeling.²³⁻²⁵

Although liposuction has become one of the most popular cosmetic procedures in the world,^{1,26} little has been published about combining liposuction with other aesthetic procedures.²⁷ Two post-marketing chart reviews were performed on patients who had undergone liposuction combined with helium plasma treatment. The primary objective was to evaluate the safety of these combined treatments. Secondary objectives were to assess the extent of aesthetic improvements and overall subject satisfaction.

2 | METHODS

2.1 | Chart Review #1

2.1.1 | Study subjects

Eligible subjects were male and female, 21 years of age or older who had received helium plasma for subdermal coagulation following a liposuction procedure, expressed their willingness to comply with all study requirements, and had pre- and posttreatment images available for evaluation. Reasons for exclusion from the study included diabetes or a bleeding disorder, use of immunosuppressant medications, an additional surgical procedure in the anatomical area to be treated with helium plasma subdermal coagulation, or an illness or condition that might put the subject at risk or jeopardize the objectives of the study.

2.1.2 | Procedure

Paper and electronic medical records for subjects meeting the eligibility requirements were reviewed. All procedures were performed on the arms, abdomen, or neck in a typical clinic setting. Blinded pre- and posttreatment images of the treatment area were obtained to assess the extent of tissue contraction. To be eligible for analysis, the images must have met predetermined eligibility criteria for image consistency established by an independent review committee and included similar pre- and posttreatment subject positioning, lighting, and original joint photographic experts group (JPEG) format. A panel of three independent reviewers observed before and after images for visual differences in the target area (MS Clinical Research, Ltd.). Quantitative assessments of angle reduction and area measurements between before and after images were calculated and the percentage reduction was reported. Subject satisfaction surveys were completed by all study subjects following treatment.

2.1.3 | Endpoints

Subject variables included gender, age, body-mass index, and comorbidities. Surgical variables included concomitant procedures, infiltrate mixture, undermining technique, aspiration process, procedure time, total blood loss, helium plasma generator setting (percent power, helium flow) and type of handpiece used, surgical technique details, and anatomical areas treated. Outcome variables included length of follow-up, reduction in neck angle measurement, and body area measurement, and subject satisfaction. Safety variables included intra- and postprocedural adverse events and surgical complications.

For abdominal measurements, the before and after images were analyzed using available markers identified on the body that do not change to align and create a reference point. The area was calculated as % of reduction = (Before - After)/(Before - Target) × 100.

2.2 | Chart Review #2

This retrospective study reviewed paper or electronic medical records for subjects meeting the eligibility requirements of being male or female, 21 years of age or older who had undergone a subdermal coagulation procedure with the helium plasma device following liposuction. Deidentified information was collected to perform descriptive statistics. Images were additionally mapped for quantitative measurements. The same site was isolated from the images obtained at both pre- and postprocedure.

Patient variables include age, gender, body-mass index (BMI), and comorbidities; surgical variables included concomitant procedures, infiltrate mixture, undermining technique, aspiration process, procedure time, total blood loss, intraoperative complications, type of device handpiece used, device generator settings and treated areas; and outcome variables included duration of follow-up, and adverse events.

Assessment of sagginess under the chin was analyzed both by neck angle and neck area. The angle across the jawline to under the chin was measured and reduction in angle calculated. Additionally, an area measurement under the chin was calculated as % of reduction = (Before – After)/(Before – Target) × 100.

3 | RESULTS

3.1 | Chart Review #1

Study subjects ($N = 37$) were male ($n = 6$) and female ($n = 31$), 21–70-years old with a mean BMI of 27 kg/m^2 (range, 18–41 kg/m^2). The mean duration of posttreatment follow-up was 3.5 months (range, 1 day to 11 months). For most subjects (84%), a 1:1 infiltrate mixture was utilized and the remainder (16%) received 2% lidocaine with epinephrine.

Methods of undermining included ultrasound-assisted aspiration (VASERlipo®; Solta Medical, Inc.; $n = 29$), cannula without suction ($n = 7$), and unknown method ($n = 1$). All subjects received liposuction with ultrasound-assisted aspiration (78%), cannula suction (19%), or an unknown method (3%). The anatomical areas treated with liposuction and helium plasma coagulation included anterior thighs ($n = 8$), arms ($n = 8$), buttocks ($n = 4$), female breasts ($n = 2$), hips (“love handles”; $n = 17$), infra-axillary ($n = 4$), inner thighs ($n = 13$), lower face ($n = 6$), male breasts ($n = 3$), neck ($n = 14$), outer thighs ($n = 11$), posterior thigh ($n = 8$), scapular rolls ($n = 8$), and stomach ($n = 17$).

The mean plasma generator settings were 70% power (range, 40%–85%) and mean helium flow was 3 LPM (range, 1.5 to 4 LPM) with a mean of six passes per area (range, 1.5–6 passes). Several handpieces were used (J-Plasma/Renuvion® Precise 150-mm Blade Tip (59%), 27-cm Blade Tip (27%), or unknown (14%).

The procedure duration was longer than 2 h ($n = 1$), 2–4 h ($n = 21$), 4–7 h ($n = 2$), or unknown duration ($n = 3$). The amount of aspiration during the procedure was estimated to be lesser than or equal to 20 ml ($n = 17$), 30–50 ml ($n = 9$), 60–150 ml ($n = 7$), or an unknown quantity ($n = 4$). Subjects were followed for less than 1 month (25%), 1–5 months (44%), and 6–11 months (31%). There were no intra- or postprocedural complications.

Among the eligible subjects, 12 sets of pre- and posttreatment images of the abdomen ($n = 3$), arms ($n = 1$), and neck ($n = 8$) met the review criteria and the remainder were ineligible for analysis due to quality. Visual inspection by the Independent Photographic Reviewers found all evaluated sets of subject images (100%) were different. Reviewers identified visual differences in terms of sagging under the chin, significant arm tightening, and the difference in the protuberance in the abdomen area for applicable body areas. All posttreatment subject images were correctly identified by the independent photographic reviewers 100% of the time.

The mean reduction in neck angle was 49.2% (range, 12.4%–73.6%) and the mean reduction in the submental neck area was 52.0% (range, 46.1 to 67.8%). Figure 1 demonstrates neck angle measurement with a 68.6% reduction in angle. Procedure

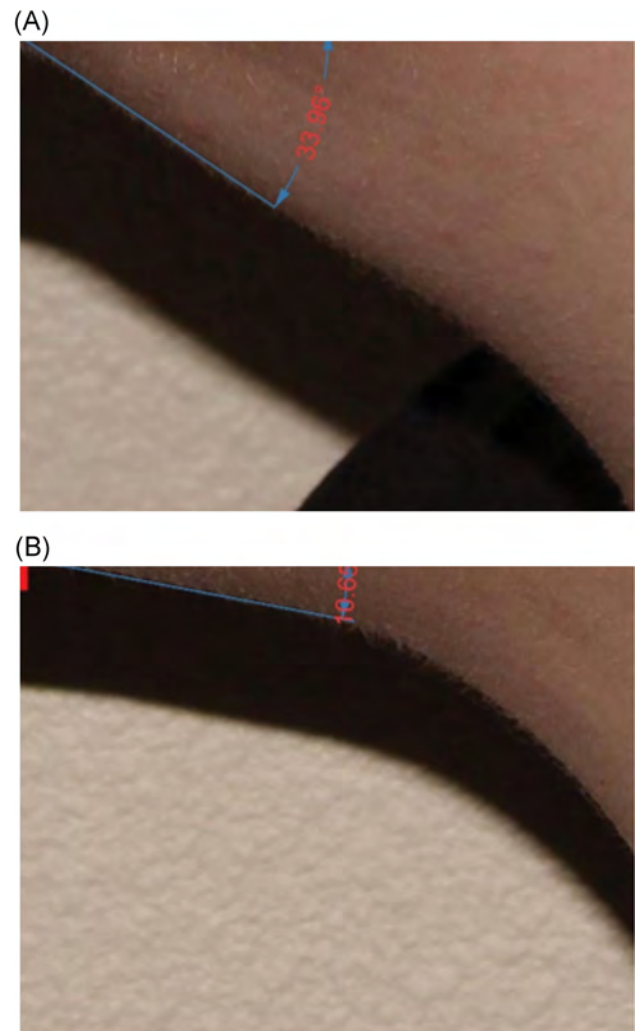


FIGURE 1 Treatment of submental angle. This subject achieved a 68.6% reduction in submental angle. (A) Pretreatment, (B) posttreatment. Photo credit, Edward Zimmerman, MD

information for this subject is: Liposuction with 3-mm George Fisher cannula, less than 20 ml aspiration, helium plasma passes unknown, 60% power, 1.5 LPM. Figure 2 shows the neck area reduction of 56.7%. Procedure information for this subject is: Ultrasound-assisted liposuction, less than 20 ml aspiration, J-Platzy sutures, six passes helium plasma with 60% power, 4 LPM. For arm measurements, the back of the arm was sectioned into three parts. The diameter of each section was then measured in milliliters for each arm. The mean reduction was then calculated using: (Pixel of arms/Total Pixel) × 100. This measurement was performed independently for right and left arms in comparative evaluation between the before and after images. The percent reduction in the area is a representation of percent arm tissue contraction. An average of both arms was used to represent the Overall Percent Area Reduction. The mean area reduction in the left and right arm was 24.6% and 28.1%, respectively, with an overall reduction of 26.4% as demonstrated in Figure 3. Procedure information for this subject is: Ultrasound-assisted liposuction with power setting 70%, less than 50 ml aspiration, four passes helium plasma at 70% power, 2.5 LPM.

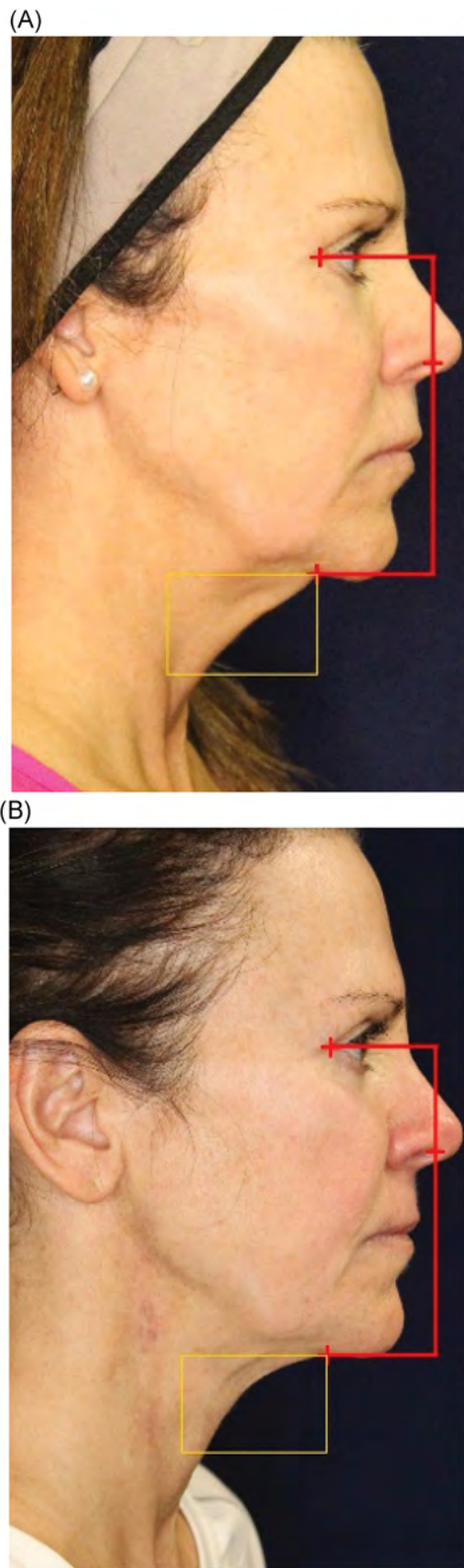


FIGURE 2 Treatment of the submental area. This subject achieved a 56.7% reduction in the submental area. (A) Pretreatment, (B) posttreatment. Photo credit, Vaishali Doolabh, MD

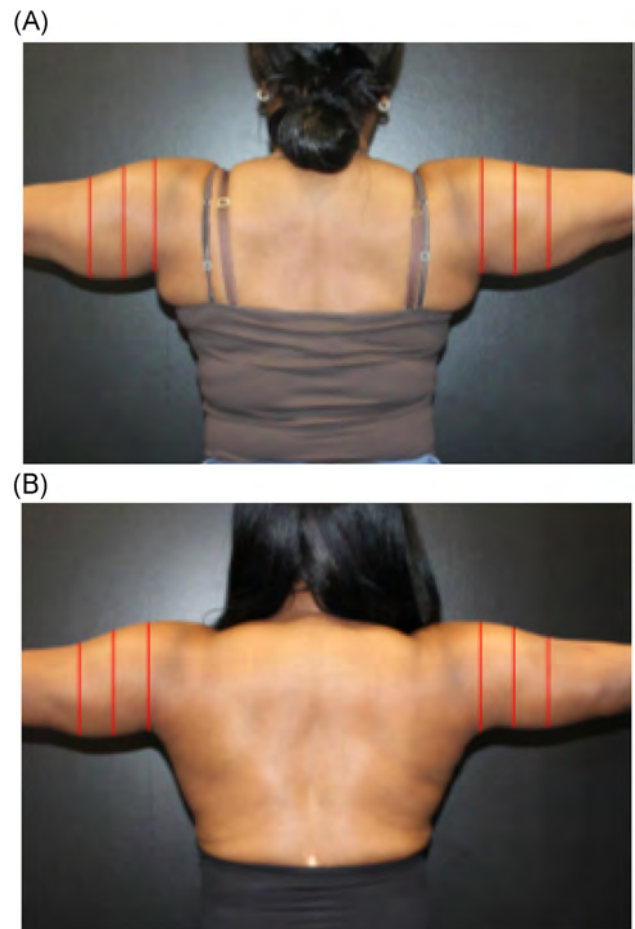


FIGURE 3 Treatment of upper arms. This subject achieved a 26.4% overall reduction in the arm area. (A) Pretreatment, (B) posttreatment. Photo credit, Paul G. Ruff, MD

The mean reduction in abdominal width was 82.1% (range, 52%–100%) and mean area reduction was 96.0% (range, 29.7%–66.2%). Figure 4 shows abdominal area measurement and a 29.7% reduction in area. Procedure information for this subject is: Ultrasound-assisted liposuction with power settings of 70% to stomach, hips, thighs, neck and arms, aspiration unknown, and helium plasma to abdomen, flanks, and arms with an unknown number of passes at 80% power, 3 LPM. Thighs were treated with helium plasma at 40% power, 3 LPM.

Most subjects (75.7%) reported aesthetic improvement (Improved, 21.6%, Much Improved, 13.5%, and Very Much Improved, 40.5%) following their procedure (Tables 1) and (67.6%, $n = 25$) were happy with their results, would recommend to a friend, and would consider having their procedure done again. Overall satisfaction was achieved by 74% ($n = 27$) of subjects by a scale from 1 to 10 (1 is the worst, 10 is the best), with scores 6 or more counted as satisfied (Table 2). On the basis of the Subject Global Aesthetic Improvement Scale (S-GAIS) scores, subjects rated the change in their appearance as Very Much Improved (40.5%), Much Improved (13.5%), Improved (21.6%), No Change (13.5%), Worse (8.1%), or did not respond (2.7%).

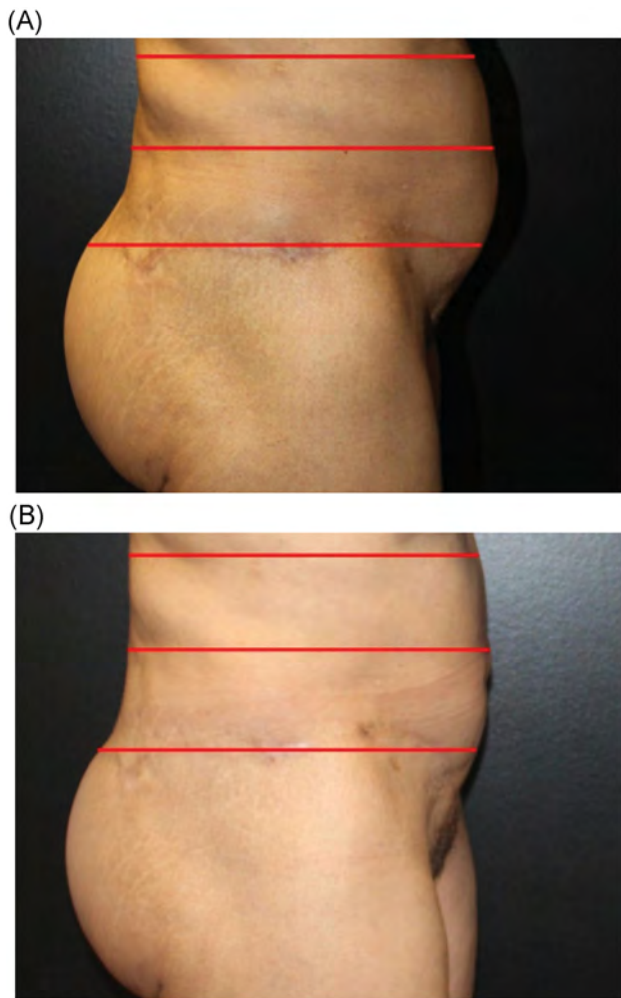


FIGURE 4 Treatment of abdominal area. This subject achieved a 29.7% reduction in the abdomen area. (A) Pretreatment, (B) posttreatment. Photo credit, Paul G. Ruff, MD

One adverse events (AE) of redness and firmness on right neck was considered possibly device-related and resolved after 117 days. An AE of upper buttocks redness resolved after 12 days, an AE of seroma left sacrum area resolved after 9 days, and an AE of swelling resolved after 64 days. These latter three events were not

TABLE 1 Subject Global Aesthetic Improvement Scale evaluation

Response	n (%)
Very much improved	15 (40.5)
Much improved	5 (13.5)
Improved	8 (21.6)
No change	5 (13.5)
Worse	3 (8.1)
Not answered	1 (2.7)
Total	37 (100.0)

TABLE 2 Overall subject satisfaction survey

Score	Percent
1	8
2	0
3	5
4	11
5	3
6	5
7	11
8	22
9	14
10	22

Note: On the basis of a score of 1 (worst) to 10 (best)

considered helium plasma device-related. All AEs were determined to be mild in severity.

3.2 | Chart Review #2

The chart review identified 148 eligible subjects. Most subjects were female ($n = 120$), 21–84-years old with a mean BMI of 27 kg/m^2 (range, 18 to 44 kg/m^2). The mean duration of postprocedure follow-up was 3.4 months (range, none to 14 months).

For almost all subjects (95%), a 1:1 infiltrate mixture was utilized and a few (4%) received a 0.75:1 mixture. Undermining was performed with an ultrasound-assisted method with power (Vaser™; $n = 136$; 92%), laser-assisted liposuction (SmartLipo™; $n = 9$; 6%) or unknown ($n = 3$; 2%). Liposuction was performed in all subjects (100%) using ultrasound-assisted aspiration ($n = 132$; 92%), small cannula suction ($n = 9$; 6%), or unknown ($n = 3$; 2%).

The anatomical areas treated with liposuction and helium plasma included the stomach ($n = 74$), hips (love handles, $n = 67$), neck ($n = 47$), inner thigh ($n = 39$), scapular rolls ($n = 35$), arms ($n = 33$), lower face ($n = 27$), infra-axillary ($n = 19$), anterior thigh ($n = 22$), outer thigh ($n = 22$), posterior thigh ($n = 20$), male breast ($n = 16$), buttocks ($n = 12$), female breast ($n = 11$), lower legs ($n = 7$), knees ($n = 1$), pubis ($n = 1$), and eyes ($n = 1$).

The mean generator settings were 70% power (range, 20%–100%), mean helium flow 3 LPM (range, 1.5–4.0 LPM) with a mean of four passes per treatment area (range, 2–9 passes). The device handpieces used during the study (Renuvion® Precise) were 150 mm ($n = 28$; 19%), 27 cm ($n = 64$; 43%), 33 cm ($n = 4$; 3%), or unknown ($n = 52$; 35%).

The total procedure time was less than 2 h ($n = 36$), 2–4 h ($n = 73$), 4–8 h ($n = 34$), or unknown duration ($n = 5$). The mean aspiration volume during the procedure was estimated to be lesser than or equal to 20 ml ($n = 40$), 30–50 ml ($n = 47$), 60–100 ml ($n = 25$), 150–500 ml ($n = 15$), or an unknown volume ($n = 21$). The mean duration of follow-up was lesser than or equal to 1 month (34%), 2–5 months (38%), or 6–11 months (28%).

The reported adverse events ($N = 34$) were definitely related ($n = 2$), probably related ($n = 1$) or possibly related ($n = 17$). The most common events were seromas ($n = 14$; 9%) with a mean duration of 44 days, and swelling ($n = 3$, 2%) with a mean duration of 94 days. Two serious adverse events which occurred during the study were subcutaneous hematoma in the left chest requiring hospitalization and hematoma in the right chest wall requiring aspiration. Both events were determined to be possibly device-related and resolved in a mean of 19.5 days. There were no unexpected events.

4 | DISCUSSION

The objectives of these retrospective studies were to evaluate the safety and efficacy of helium plasma when used for subdermal tissue coagulation following liposuction. Among the 37 subjects from Chart Review #1 who underwent combined procedures, there were no serious adverse events or unexpected events with only one related mild adverse event reported. All subjects participated in a retrospective satisfaction questionnaire. Most subjects reported high levels of aesthetic improvement and overall satisfaction. Of the 12 subjects with eligible images for review and analysis, all demonstrated improved tissue contraction after a mean follow-up period of 3.5 months as determined by independent reviewers. Additionally, all subjects demonstrated a reduction in neck angle, neck area, arm area, and abdominal area for applicable images analyzed.

The larger group of 148 subjects from Chart Review #2 was treated with combined procedures over a broad range of anatomical areas. Few reported adverse events were considered definitely or probably related. Two serious adverse events were reported; however, both subjects were treated with ultrasound-assisted liposuction and helium plasma making it unclear which device or if the combined use of devices was responsible. Although the adverse events of seroma were commonly reported, it is a known complication associated with ultrasound-assisted liposuction.²⁸

The subjects in Group 2 were treated on 454 anatomical areas with 34 reported adverse events, an event rate of 7.8%. This compares favorably with similar reports. In one report, the incidence of minor complications associated with radiofrequency-assisted liposuction across all treatment areas was 8.3% and major complications was 6.25%.²⁹

There is little information available regarding liposuction in combination with other aesthetic procedures. A prospective cohort of patients who underwent liposuction between 2008 and 2013 was identified by researchers from the CosmetAssure database. Published results indicate that among subjects undergoing liposuction alone procedures ($N = 31,010$), the overall complication rate was 0.7%.²⁷ The complication rate increased significantly when liposuction was combined with other aesthetic procedures; however, these were largely surgical procedures such as abdominoplasty and breast augmentation.²⁷ When liposuction was combined with facial procedures such as rhinoplasty and facelift, the rate of adverse events was less than those when those facial procedures were performed alone (0%–1.5% vs. 0.4%–3.0%).

Helium plasma technology represents a novel method to safely and effectively improve the appearance of lax skin in several anatomical areas. Treated subjects expressed high levels of satisfaction. The results of this study suggest helium plasma is a safe and effective adjunct therapy when used in combination with liposuction. Limitations of this study included the retrospective study design, a small number of eligible subjects, and missing data for a few subjects. A clinical trial with subjects randomized to undergo liposuction with or without helium plasma would help define the contribution made by this adjunct treatment. More data will become available as the use of helium plasma becomes more widely utilized.

The primary limitation to this study is the retrospective nature of a chart review and the lack of control groups.

5 | CONCLUSION

Two retrospective studies were completed of patients who underwent a procedure where a helium driven plasma radiofrequency device was used as a tool for subdermal coagulation of tissue. The results of these retrospective studies suggest helium plasma is safe and may be an effective adjunct therapy when used in combination with liposuction. Further research is warranted and underway (ClinicalTrials.gov Identifier: NCT04146467).

ACKNOWLEDGMENTS

The authors acknowledge the editorial assistance of Dr. Carl S. Hornfeldt, Apothekon, Inc., during the preparation of this manuscript. These studies were sponsored by Apyx Medical, Clearwater, FL USA.

CONFLICT OF INTERESTS

Paul G. Ruff and Edward Zimmerman are paid consultants, speakers, stock options recipients, recipients of clinical research grants, and medical advisory board members for Apyx Medical. Vaishali Doolabh is a paid consultant, speaker, and recipient of clinical research grants for Apyx Medical. Richard A. Gentile is a paid consultant, speaker, stock options recipient, purchased stock owner, recipient of clinical research grants, and medical advisory board member for Apyx Medical.

PHOTO CONSENT

All patients in this study consented to photographs and the use of those photographs in educational content and scientific journals.

ORCID

Paul G. Ruff  <http://orcid.org/0000-0003-3882-0787>

Edward M. Zimmerman  <https://orcid.org/0000-0003-0324-0408>

REFERENCES

1. American Society of Plastic Surgeons. Plastic Surgery Statistics Report, 2018. www.PlasticSurgery.org. Accessed October 29, 2019.
2. Devgan L, Singh P, Durairaj K. Surgical cosmetic procedures of the face. *Otolaryngol Clin North Am*. 2019;52:425-441.

3. Charafeddine AH, Drake R, McBride J, Zins JE. Facelift: history and anatomy. *Clin Plast Surg.* 2019;46:505-513.
4. Vanaman M, Fabi SG, Cox SE. Neck rejuvenation using a combination approach: our experience and a review of the literature. *Dermatol Surg.* 2016;42 S94-S100.
5. Humphrey S, Beleznyay K, Fitzgerald R. Combination therapy in midfacial rejuvenation. *Dermatol Surg.* 2016;42 S83-S88.
6. Fabi SG, Burgess C, Carruthers A, et al. Consensus recommendations for combined aesthetic interventions using botulinum toxin, fillers, and microfocused ultrasound in the neck, décolletage, hands, and other areas of the body. *Dermatol Surg.* 2016;42:1199-1208.
7. Carruthers J, Burgess C, Day D, et al. Consensus recommendations for combined aesthetic interventions in the face using botulinum toxin, fillers, and energy-based devices. *Dermatol Surg.* 2016;42: 586-597.
8. Narurkar VA, Cohen JL, Dayan S, et al. A comprehensive approach to multimodal facial aesthetic treatment: injection techniques and treatment characteristics from the HARMONY Study. *Dermatol Surg.* 2016;42:S177-S191.
9. Cartier H, Hedén P, Delmar H, et al. Repeated full-face aesthetic combination treatment with abobotulinumtoxinA, hyaluronic acid filler, and skin-boosting hyaluronic acid after monotherapy with abobotulinumtoxinA or hyaluronic acid filler. *Dermatol Surg.* 2020; 46(4):475-482.
10. Anand C. Facial contouring with fillers, neuromodulators, and lipolysis to achieve a natural look in patients with facial fullness. *J Drugs Dermatol.* 2016;15:1536-1542.
11. Koren A, Isman G, Cohen S, et al. Efficacy of a combination of diluted calcium hydroxylapatite-based filler and an energy-based device for the treatment of facial atrophic acne scars. *Clin Exp Dermatol.* 2019;44:e171-e176.
12. Urdiales-Gálvez F, Martín-Sánchez S, Maíz-Jiménez M, Castellano-Miralla A, Lionetti-Leone L. Concomitant use of hyaluronic acid and laser in facial rejuvenation. *Aesthetic Plast Surg.* 2019;43:1061-1070.
13. Casabona G, Nogueira Teixeira D. Microfocused ultrasound in combination with diluted calcium hydroxylapatite for improving skin laxity and the appearance of lines in the neck and décolletage. *J Cosmet Dermatol.* 2018;17:66-72.
14. Dayan E, Chia C, Burns AJ, Theodorou S. Adjustable depth fractional radiofrequency combined with bipolar radiofrequency: a minimally invasive combination treatment for skin laxity. *Aesthet Surg J.* 2019; 39:S112-S119.
15. Yang C, Li Q. A prospective study of safety and efficacy of combination therapy with bipolar radiofrequency-based intense pulsed light, infrared light, and diode laser in Chinese subjects with photoaged skin. *J Cosmet Laser Ther.* 2016;18:339-344.
16. Hammoudeh ZS, Stevens WG. Nonsurgical adjuncts following facelift to achieve optimal aesthetic outcomes: "Icing on the cake". *Clin Plast Surg.* 2019;46:613-623.
17. Hunstad JP, Aitken ME. Liposuction: techniques and guidelines. *Clin Plast Surg.* 2006;33:13-25.
18. Dixit VV, Wagh MS. Unfavourable outcomes of liposuction and their management. *Indian J Plast Surg.* 2013;46:377-392.
19. Gentile RD. Renuvion/J-Plasma for subdermal skin tightening facial contouring and skin rejuvenation of the face and neck. *Facial Plast Surg Clin North Am.* 2019;27:273-290.
20. Vangsnest CT Jr, Mitchell W 3rd, Nimni M, Erlich M, Saadat V, Schmotzer H. Collagen shortening. An experimental approach with heat. *Clin Orthop Relat Res.* 1997;337:267-271.
21. Hayashi K, Thabit G 3rd, Massa KL, et al. The effect of thermal heating on the length and histologic properties of the glenohumeral joint capsule. *Am J Sports Med.* 1997;25:107-112.
22. Ross VE, Yashar SS, Naseef GS, et al. A pilot study of in vivo immediate tissue contraction with CO2 skin laser resurfacing in a live farm pig. *Dermatol Surg.* 1999;25:851-856.
23. Sadick N. Tissue tightening technologies: fact or fiction. *Aesthet Surg J.* 2008;28:180-188.
24. Fabi SG. Noninvasive skin tightening: focus on new ultrasound techniques. *Clin Cosmet Investig Dermatol.* 2015;8:47-52.
25. Souren JM, Ponec M, van Wijk R. Contraction of collagen by human fibroblasts and keratinocytes. *In Vitro Cell Dev Biol.* 1989;25: 1039-1045.
26. Chia CT, Neinstein RM, Theodorou SJ. Evidence-based medicine: liposuction. *Plast Reconstr Surg.* 2017;139:267-274e.
27. Kaoutzanis C, Gupta V, Winocour J, et al. Cosmetic liposuction: preoperative risk factors, major complication rates, and safety of combined procedures. *Aesthet Surg J.* 2017;37:680-694.
28. Glashofer M, Coleman WP 3rd, Lewis A, Mason S, Plaisance J. Seroma formation following abdominal liposuction. *Dermatol Surg.* 2005;31:770-771.
29. Theodorou SJ, Paresi RJ, Chia CT. Radiofrequency-assisted liposuction device for body contouring: 97 patients under local anesthesia. *Aesthetic Plast Surg.* 2012;36:767-779.

How to cite this article: Ruff PG, Doolabh V, Zimmerman EM, Gentile RA. Safety and efficacy of helium plasma for subdermal coagulation. *Dermatological Reviews.* 2020;1-7. <https://doi.org/10.1002/der2.34>

- The Renuvion® APR Handpiece is intended for the delivery of radiofrequency energy and/or helium plasma where coagulation/contraction of soft tissue is needed. Soft tissue includes subcutaneous tissue.
- The Renuvion APR Handpiece is intended for the coagulation of subcutaneous soft tissues following liposuction for aesthetic body contouring.
- The Renuvion APR Handpiece is indicated for use in subcutaneous dermatological and aesthetic procedures to improve the appearance of lax (loose) skin in the neck and submental region.
- The Renuvion APR Handpiece is intended for the delivery of radiofrequency energy and/or helium plasma for cutting, coagulation and ablation of soft tissue during open surgical procedures.
- The Renuvion APR Handpiece is intended to be used with compatible electro-surgical generators owned by Apyx Medical.

When the article¹ was first published online, there is a typo in Second line of 7th paragraph in Section 3.1 “The mean reduction in abdominal width was 82.1% (range, 52%–100%) and mean area reduction was **96.0%** (range, 29.7%–66.2%)”.

The bold number (96.0) should be changed to 65.3%.

We apologize for this error.

REFERENCE

1. Ruff PG, Doolabh V, Zimmerman EM, Gentile RA. Safety and efficacy of helium plasma for subdermal coagulation. *Dermatological Reviews*. 2020;1:108-114. <https://doi.org/10.1002/der2.34>