

We are IntechOpen, the world's leading publisher of Open Access books Built by scientists, for scientists

5,700

Open access books available

141,000

International authors and editors

180M

Downloads

Our authors are among the

154

Countries delivered to

TOP 1%

most cited scientists

12.2%

Contributors from top 500 universities



WEB OF SCIENCE™

Selection of our books indexed in the Book Citation Index
in Web of Science™ Core Collection (BKCI)

Interested in publishing with us?
Contact book.department@intechopen.com

Numbers displayed above are based on latest data collected.
For more information visit www.intechopen.com



Enhanced Lipocontouring of the Arms

Julie Khanna and Maryam Saheb-Al-Zamani

Abstract

The visibility of arm contour in both men and women has been a source of discussion throughout time. Arm strength and athleticism is not limited to the male physique only. Iconic women such as Madonna and Michelle Obama have made discussions about arm contour more and more commonplace. Over the years arm contour has been a difficult area to address due to the thinness of the skin which often required surgical excision and unsightly scars. Liposuction of the arm has advanced to not only allow for improved contour but also options of refining muscular definition. With the addition of energy-based technologies such as radiofrequency, we can offer less invasive options to patients who may have previously only been candidates for excisional procedures. Liposuction of the arms can be performed under local anesthesia. This chapter introduces a new algorithm for assessment and treatment of arm contour which incorporates newer energy-based devices along with surgical options.

Keywords: Arm contouring, Liposuction, VASER, Ultrasound-assisted Liposuction, High-Definition Liposuction, Radiofrequency, Skin Tightening, Brachioplasty

1. Introduction

According to the 2019 Aesthetic Plastic Surgery National Databank Statistics [1], close to 20,000 upper arm lift procedures are performed annually. Although the appearance of the arms is a common concern among plastic surgery patients, with increasing emphasis placed on arm contour and definition in popular and social media, arm contouring via brachioplasty is consistently ranked as one of the least popular body contouring procedures. This is in no doubt owing to the conspicuous brachioplasty scar which is typically tolerated only by post dramatic weight loss (PDWL) patients or those with significant skin laxity from aging [1, 2]. At the other end of the treatment spectrum, non- or minimally-invasive treatment options such as liposuction are available to patients with mild to moderate arm fatty excess but good skin contractility and quality [3]. Until recently, there has been a large treatment gap between the two ends of the spectrum for patients with mild to moderate skin laxity, or even those with significant skin laxity who are intolerant of the brachioplasty scars. With the advent of energy-based devices that can be coupled with liposuction and excisional surgeries, treatment algorithms can now be broadened to serve the full range of patients with various levels of adiposity, skin laxity, and photoaging. In this chapter, we outline our preferred approach to arm contouring, which combines Vibration Amplification of Sound Energy at Resonance (VASER) liposuction with radiofrequency (RF) skin tightening treatments and other

complementary treatments as needed to address adipose excess, enhance muscular contour, and improve skin tightening and quality.

2. Pertinent arm anatomy

The subcutaneous fat layer of the arm is divided into two layers: a superficial or areolar layer and a deep or lamellar layer, with the latter being more prone to fat accumulation [2]. With the arm by the patient's side, Hoyos [4] divides the arm into four regions: anterior, posterior, internal (adjacent to body), and external (away from body) (**Figure 1**). The major fat composition of the anterior, external, and internal regions is a thin layer of superficial fat. Pinch test in the internal region is commonly less than 1 cm and aggressive liposuction is typically avoided to prevent contour deformities [5]. The major neurovascular structures travel in the internal region, close to the bicipital groove, but are located deep to the deep fascia and away from zones of liposuction [5, 6]. The posterior region contains a distinct deep layer of fat that can vary in thickness with patient body mass index (BMI) and is focal to arm lipocontouring. The arm shape is primarily determined by the muscular composition of the deltoid, biceps, triceps muscles, and the overlying fat [4]. The ideal arm contour is defined by convexities and concavities, highlights and shadows that correspond to underlying musculature. With the arm and elbow abducted at 90 degrees, shape of the anterior arm is defined by the deltoid and biceps muscle mass convexities. The shape of the posterior arm is more intricate, with triceps muscle mass creating a convexity in the midportion and concavities proximally at

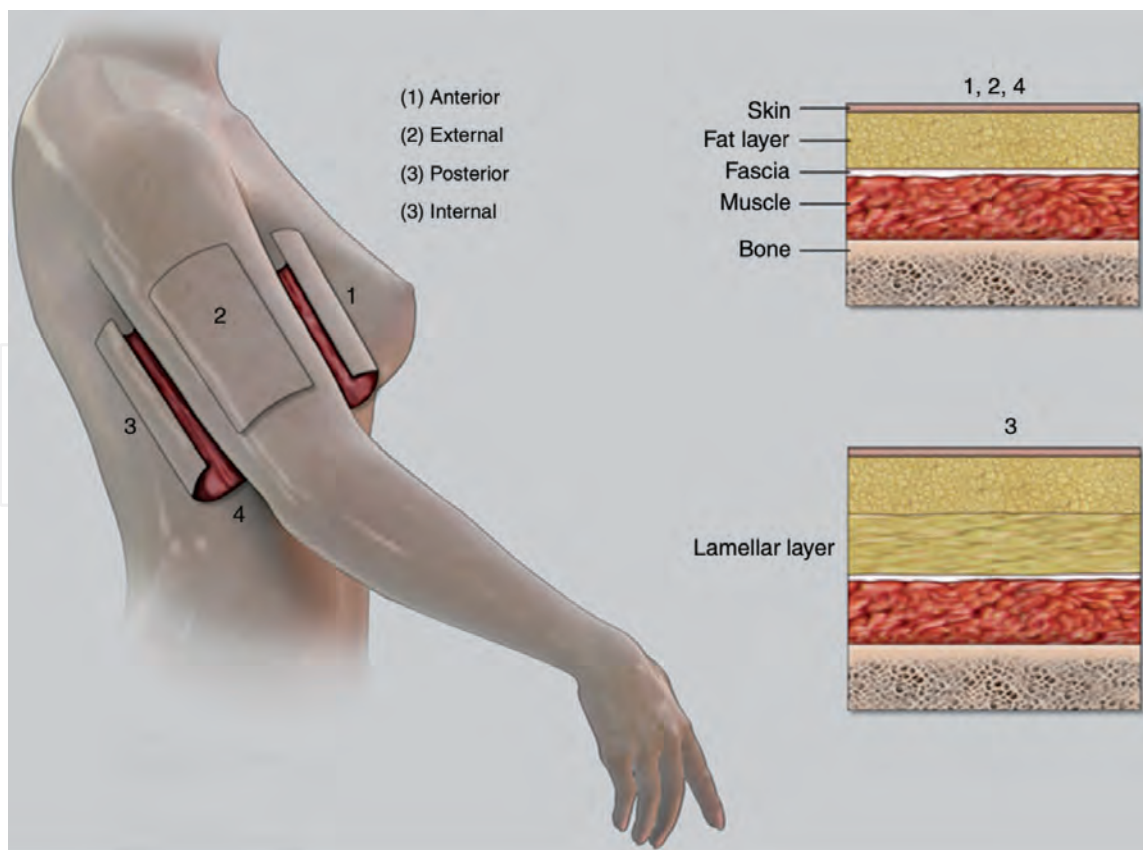


Figure 1. Fat distribution and zones of contour assessment in the arm, according to Hoyos [4]. The arm is divided into 4 zones: anterior (1), external (2), posterior (3), and internal (4). Fat is divided into a superficial (areolar) and a deep (lamellar) layer in the arm. The posterior zone (3) is prone to fat accumulation in the deep layer. The remaining zones are largely comprised of superficial fat layer and less susceptible to fat accumulation in normal BMI ranges. (Image reprinted with permission).

muscle insertion and distally owing to the flat triceps tendon [4]. Arm contouring techniques, whether by liposuction or excisional surgery, aim to enhance these ideal aesthetic arm shapes, while respecting the patient's overall body habitus to create a desired and harmonious silhouette.

3. Favored technologies and adjuncts to liposuction

Our preferred approach to lipocontouring of the arms has evolved as different technologies and methods have become available over the years. Each modality and approach shared here with the readers has been clinically evaluated in our practice with regards to its application, enhancement of results, and patient safety.

3.1 VASER liposuction

The workhorse of our approach to lipocontouring of the body, including the arms, is using ultrasound-assisted liposuction (UAL) to prepare the fat for smooth extraction with some skin retraction and limited blood loss. We use VASER (Solta Medical, Bothell, WA), which is a third-generation UAL device. Following infiltration of tissues with tumescent fluid, the VASER blunt probe is gently moved through both the superficial and deep layers of fat. VASER uses ultrasonic energy to emulsify the fat for removal by suction-assisted or power-assisted liposuction (SAL, PAL respectively). The emulsification process occurs through a combination of cavitation, mechanical, and thermal effects. The cavitation effect occurs when the VASER probe, vibrating at ultrasonic frequencies, creates microbubbles that implode and release energy that disrupts the fat layer architecture, while preserving the integrity of the fat cells and tissue matrix [4, 7, 8]. The mechanical effect occurs when the vibrating tip comes into contact with adipocytes [4]. We compare this effect to shaking the grapes off of a vine. As a by-product of the high-frequency vibration, thermal energy is created [4], which contributes to a modest amount of skin tightening following liposuction. Care must be exercised to avoid accumulation of excess thermal energy at any one location by keeping the probe in constant smooth motion.

VASER liposuction offers several advantages over traditional liposuction, with respect to smooth fat harvest and minimizing irregularities, improved skin retraction, and limiting blood loss. Traditional forms of liposuction (SAL and PAL) can lead to contour irregularities, especially in the thin, soft tissues of the upper arm and in the superficial fat layer, that present as cannula lines, uneven fat pockets, and potential iatrogenic cellulite-like appearance of the thin internal skin. Loosening of the adipocytes with VASER emulsification prior to aspiration leads to smoother fat extraction as well as the ability to use finer cannulas. Further, the thermal energy from VASER can melt the superficial fat and tighten the fibroseptal network (FSN), leading to an improved arm contour and appearance [9]. VASER liposuction has been shown to result in significantly more (53%) skin retraction relative to SAL (17% skin retraction per liter of liposuction with VASER compared to 11% with SAL) [10]. In cases of negligible fat excess in the arms with limited need for liposuction, we still find VASER to be immensely helpful. The blunt probe of the VASER helps to gently pre-tunnel prior to the use of any other instrumentation (SAL/PAL aspiration or skin tightening with subdermal RF devices) to minimize tissue trauma and create smoother outlines. In addition, the moderate skin tightening effects of VASER can be synergistic with other skin tightening treatments.

By virtue of keeping the tissue matrix and neurovascular networks intact, VASER liposuction can result in 26% reduced blood loss compared to traditional liposuction [10], enhancing patient safety especially when arm liposuction is coupled with other concurrent surgeries or multiple areas of liposuction.

3.2 Skin tightening with radiofrequency (RF) devices

The greatest barrier to arm skin excision procedures has been the need for extended conspicuous scars that limit the choice of arm-bearing clothing, which is the common presenting complaint in the first place. While there is still no replacement for the extent of skin laxity correction that can be achieved by removal of skin, we find that the improvements achieved with minimally-invasive arm contouring methods frequently meet the desired goal of many patients, and at the very least may help shorten the length of any eventual skin excision scars. VASER can provide a modest amount of skin retraction following liposuction as discussed above which may be sufficient in patients with mild skin laxity. In most other cases, we utilize RF technologies devised for skin contractility as an adjunct to lipocontouring.

3.2.1 Subdermal application of RF

A number of studies have demonstrated that neocollagenesis occurs when soft tissues and the dermis are heated to a temperature of 60 to 80°C and skin surface to approximately 40°C [11]. When RF energy is applied subdermally, conversion of RF energy to heat in this temperature range can be achieved, resulting in collagen fiber restructuring and formation as opposed to tissue necrosis. RF energy in the subcutaneous and subdermal space is converted to heat and results in contraction by two mechanisms. First, cleavage of hydrogen bonds in the collagen fibrils results in shrinkage and thickening of the FSN immediately after energy application. Second, the wound healing cascade is initiated, which results in neocollagenesis, angiogenesis, and elastin reorganization with effects on the skin quality observed over the three to four months following treatment [12]. Subdermal RF heating has been shown to result in FSN contraction and soft tissue contraction of up to 47% [13]. A 50% reduction in vertical height of lax pendulous skin and skin surface contraction of 33.5% can be achieved in the arm with RF treatment [9].

There are two categories of subdermal RF devices available for skin tightening: (1) “bulk heating” devices that utilize RF energy for focal tissue heating (such as Thermi and InMode), and (2) a helium-based plasma device that utilizes RF energy to generate a plasma beam as well as creating thermal energy (Renuvion) [14]. These device categories are described below, and their similarities and differences are highlighted.

“Bulk heating” RF was initially introduced as a monopolar device, which consisted of an energy-emitting subdermal probe and required a grounding pad on the body (Thermitight, Thermi, Irving, TX). Since energy is focused at the tip of the probe, heat accumulates in a small region of tissues quickly (“hot spots”) and dissipates slowly to surrounding tissues. Tissue heating can therefore be uneven and poorly optimized. An external monitoring device for heating at the skin surface device is required for safety and to avoid burns from hot spots [14]. Newer bulk-heating RF technologies utilize bipolar devices with two electrodes, an internal one inserted into the subcutaneous layer and an external one making contact with skin surface, to create a unidirectional transfer of energy through the tissues between the two probes. Since RF energy is directed between the two electrodes, only the

intervening tissue is heating, limiting unintended thermal energy elsewhere. A grounding pad is not required. Bodytite (InMode, Lake Forest, CA) is a commonly used bipolar RF device for skin tightening with body contouring procedures. Bodytite handpiece has built-in internal and external temperature monitors that promote safety and eliminate the need for skin thermal surveillance with a separate camera [11, 15]. Bipolar RF devices circumvent many of the application and safety limitations of the earlier monopolar devices. As such, we no longer utilize subdermal monopolar RF in our practice.

The latest subdermal RF device to enter the market has been Renuvion (formerly branded as J-Plasma; Apyx Medical Corporation, Clearwater, FL). Renuvion utilizes RF energy to create a helium plasma in addition to traditional thermal heating. Briefly, RF energy is delivered to the handpiece to energize an electrode, while helium gas is passed over, creating a helium plasma which delivers heat to the tissues by two methods. First, production of plasma beams, by ionization and rapid neutralization of helium atoms, produces heat directly. Secondly, the plasma beam functions as an effective electrical conductor to transfer a portion of the RF energy directly to the tissues. Heat is generated as the current passes through the resistance of the tissues— a process known as “Joule heating” [14]. The Renuvion plasma beam heats soft tissue targets to temperatures greater than 85°C for less than 0.1 second to achieve desired coagulation and contraction. Unlike bulk heating, tissues surrounding the treatment target remain much cooler allowing for rapid cooling of target zones after treatment application by process of heat conduction and limiting hot spots. The plasma beam conducts through tissues that offer the least path of resistance for flow of RF energy: either through tissue that is closest to the electrode or tissue that has the lowest impedance (easiest for energy to flow through). In the subcutaneous plane, the collagen network of the FSN is typically the closest tissue and is the primary target of the heating and contraction process. As fibers are treated, they coagulate, contract, and present higher impedance. This, coupled with the withdrawal movement of the handpiece, results in the plasma beam quickly alternating between treating different and new tissue targets, which present lower impedance, in a 360° treatment field. The plasma beam efficiently results in focused treatment of FSN to result in maximal tissue contraction and skin tightening without heating the full thickness of the dermis [14].

3.2.2 Superficial and transdermal application of RF

Skin of the medial arm is thinner than other areas of the trunk and extremities and is therefore prone to early wrinkling [2]. In addition, the arms and shoulders undergo notable sun exposure resulting in further photoaging that leads to pigmentation changes, rough skin texture, and “crepey” skin appearance. In order to provide a harmonious improvement in appearance of the arms, skin quality must also be carefully assessed and addressed.

3.2.2.1 Superficial RF treatment

For gentle treatment of mild to moderate photoaging, superficial monopolar RF, such as Thermage (Thermi) can be used. Superficial monopolar RF utilizes gentle nonablative heat delivery from skin surface to the dermis at a controlled depth to result in visible improvements in skin tightening, texture, and rhytids, as well as significant histologic increases in collagen types I and III, and neocollagenesis [16, 17]. Although consistent results are seen with this technology on the face, results are less consistent when applied to the arm in our practice and thus infrequently used.

3.2.2.2 Transdermal RF treatment

More notable improvements to skin quality, including reduced laxity, roughness, and improved hydration, can be achieved when RF energy can be delivered to deeper levels of the dermis and subdermal tissues. Fractional RF devices (Fractora or Morpheus8; InMode or Profound, Candela Medical, Mississauga, ON, Canada), utilize (micro)needles or electrodes to heat the dermal and subdermal levels in a nonablative fashion. Heating of the subdermal tissues results in a degree of fat emulsification and mild contouring [12]. Skin needle puncture has been shown to improve skin texture and mild rhytids. These results are amplified when coupled with RF energy. Histologic changes consistent with increased reticular dermal thickness, dermal collagen, hyaluronic acid, and elastin content are seen following RF microneedling [15, 18]. These results are clinically notable as well. A randomized, blinded, quantitative study of skin laxity demonstrated a 16% improvement in skin laxity from baseline with fractional RF treatment as opposed to 49% achieved with surgical facelifting, and an improvement of 37% of that of facelifting with a single fractional RF treatment [19]. Fractional RF via (micro)needling can be applied in a multitude of fashions to enhance appearance of the arms. Fractional RF can augment the tightening effects of subdermal RF treatment in cases of severe skin laxity or more moderate cases of skin laxity who also present with moderate to severe skin roughness and photoaging changes. Additionally, due to its less invasive nature, RF (micro)needling can be used to address difficult-to-treat areas such as fat pads just proximal to the elbow or at the axillary-arm junction. Untreated islands of skin expedite recovery with fractional RF treatments, similar to fractional laser resurfacing [12, 15].

4. Preoperative evaluation

4.1 Treatment algorithm

Multiple algorithms for classification and treatment of arm deformities have been previously described [20–22]. These classifications all aim to address adipose and/or skin excess with liposuction, variations of brachioplasty, or a combination of these approaches. They do not incorporate energy-based methods of improving skin laxity and quality, which we find to be quite efficacious in improving arm aesthetics. Algorithms for assessment and management of the arm should be updated to accommodate new skin tightening procedures which may result in a decreased need or desire to proceed to more aggressive skin excision surgeries to achieve the patient's expected results. Theodorou et al. [11] proposed an algorithm that incorporates some energy devices to address arm adiposity, as well as skin laxity and quality, ranging from SAL, Laser-assisted liposuction (LAL), RF-assisted liposuction (RFAL), RFAL and staged skin excision, to brachioplasty. We expand upon this proposal by incorporating superficial and transdermal RF treatments as well as other adjuncts that are usually further required to improve poor skin texture and quality. **Figure 2** outlines our algorithm for assessment and treatment of arm aesthetics.

4.2 Photography and documentation

Preoperative assessment in liposuction is always the single most important step in proper surgical planning and the management of the patient's desires and expectations. Evaluation of the arms must not only include areas of excess fat but a

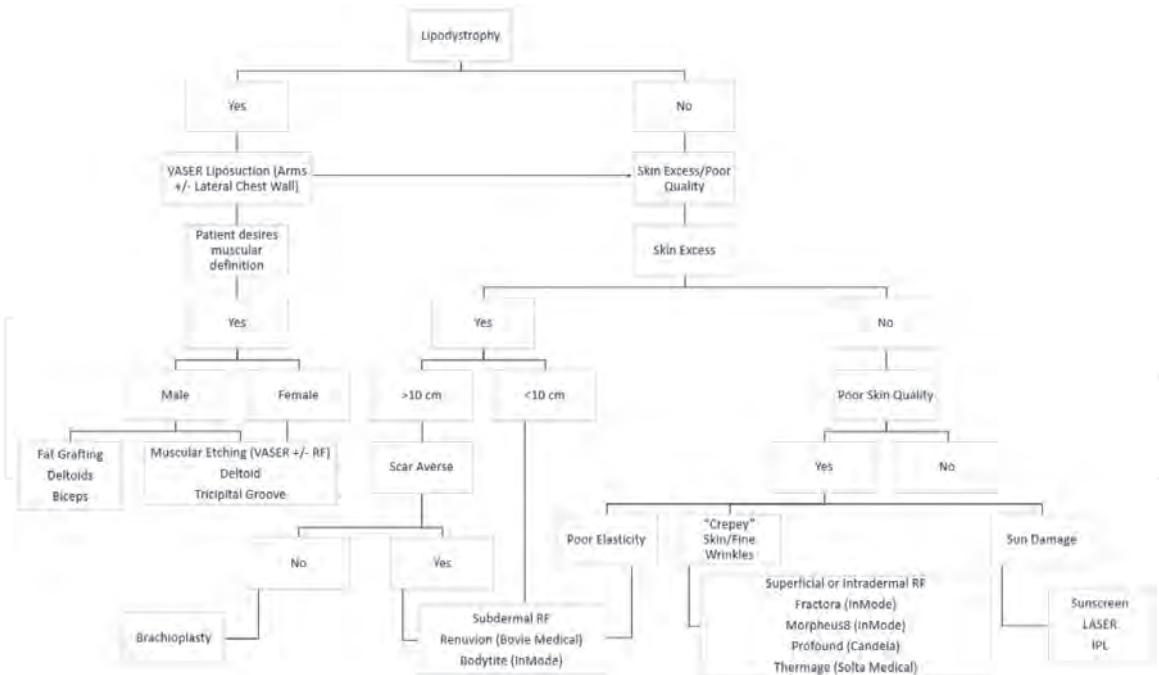


Figure 2. Our approach to assessment and treatment of patients presenting for arm enhancement. It is important to identify lipodystrophy as well as excess skin and other markers of skin photoaging for comprehensive improvement of arm appearance. Liposuction is coupled with other energy-based devices as necessary. In some patients, skin removal with brachioplasty is still considered gold standard and recommended.

detailed examination of the quality and quantity of skin, as well as the underlining musculature. Furthermore, aesthetics of adjoining anatomical areas such as the lateral chest wall, anterior axillary fold, posterior axillary fold, and the forearm should be considered and treated if appropriate.

In obtaining a full analysis of the arm, it is imperative to ask the patient what disturbs them the most about their extremity and the view(s) in which they see the concern most prominently. Dynamic assessment of the arms is also important to establish the patient's desires and expectations. The terms "bat wings", "bingo arms", or "hello Helens" imply a significant amount of redundant and possibly pendulous skin in the upper arm which may require surgical excision to obtain a true decrease in the skin volume. Obtaining a preoperative video is an excellent way of documenting the amount and dynamics of loose skin. Such video can also help document the aesthetic concerns preoperatively and their improvements postoperatively. Preoperative measurement of arm circumference is helpful to assess asymmetries and to follow postoperative results. Assessment of skin tone, texture, stretch, loss of elasticity, and the presence of striae should be included and incorporated into the operative planning.

Standard photography of front and back with shoulders abducted and elbows flexed at 90 degrees, in front of an appropriate photographic background, is of critical importance. Close-up assessment of skin is also crucial both in the planning phase and in the photo documentation phase.

5. Surgical technique

5.1 Marking

The patient is marked in the standing position with the shoulders abducted and elbows flexed at 90 degrees. The position of the ulnar nerve is marked. The areas of excess fat where deep liposuction is required in the posterior zone, extending

anteriorly and internally as needed, are outlined. The extent of liposuction is confirmed from front and back, and with the arms adducted and abducted. Adjoining regions of excess fat such as in the anterior axillary fold, lateral chest wall, and distal arm/elbow region are also marked (**Figure 3a**).

The zones of skin laxity are marked next. Due to the thinness of the skin in the internal aspect of the arm, this is the focal area of treatment with skin tightening devices. Treatment zones may extend more anteriorly and posteriorly as needed and beyond the area of the planned liposuction. The thicker skin of the external arm typically does not require treatment with subdermal skin tightening devices. If photoaging is present, that can be marked for treatment with adjunct modalities (**Figure 3b**).

When muscular etching is planned, we follow Hoyos' approach [4]. Muscular etching should reflect the patient's complete body habitus. A patient with higher BMI and poor muscle definition elsewhere will appear incongruent if muscular etching is performed on their arms. When appropriate in men, muscular etching includes enhancement of all three large muscles of the arm (deltoid, biceps, and triceps). This may include small volume fat grafting (approximately 25-50 cc) to the muscles, primarily deltoid +/- biceps, to enhance bulk. In women, it is important to establish the patient's desired degree of perceived athleticism that is in balance with their body shape. Many women want a softer look, in which case muscular etching is not performed. A large portion of women desire a toned appearance of the arms, in which case only the deltoid muscle is highlighted. In a small subset of women who strive for a full muscular appearance of their arms, further etching of the tricipital groove and biceps is added; fat grafting is rarely used in our practice for female patients (**Figure 3c**).

5.2 Preparation and anesthesia

Liposuction of the arm can either be done under local anesthetic or general anesthetic, and with or without the addition of other procedures. Arm liposuction under local anesthetic is well tolerated by patients. The patient's ability to participate in positioning and movement is very beneficial when local anesthetic is used.

Our preferred method of local anesthesia entails a combination of MKO jelly lozenge (locally compounded Midazolam 3 mg, Ketamine 25 mg, Ondansetron 2 mg) with inhaled patient-administered nitrous oxygen (Pro-Nox, Inc.; CAREstream Medical Ltd., Oakville, ON, Canada). A small access incision is placed 2 cm proximal to the olecranon in the midline or more radially thus avoiding the ulnar nerve. If more ulnar-sided access is necessary, an additional surgical incision may be placed anterior to the medial epicondyle and lateral to the biceps tendon insertion. To obtain access to the proximal arm and the anterior axillary fold, an incision can be placed behind the lateral edge of the pectoralis muscle in the axilla. Occasionally a posterior axillary incision may be necessary, especially when trying to obtain muscular etching of the posterior deltoid and the tricipital groove.

When arm liposuction is done in combination with other body contouring procedures or breast surgery, general anesthetic may be the best choice. All areas are locally infiltrated with a combination of xylocaine with epinephrine tumescent fluid with both local and general anesthetic cases (**Table 1**). When arm contouring is combined with other procedures that involve the patient being prone, the posterior axillary fold, deltoid, and tricipital groove definition can be treated from posteriorly. The remaining arm liposuction is performed with the patient supine. Draping of the arm must allow 360-degree access (**Figure 4**). The use of ear oximetry probes and leg blood pressure cuffs are helpful in patient monitoring while keeping field sterility even when the arm is moved.

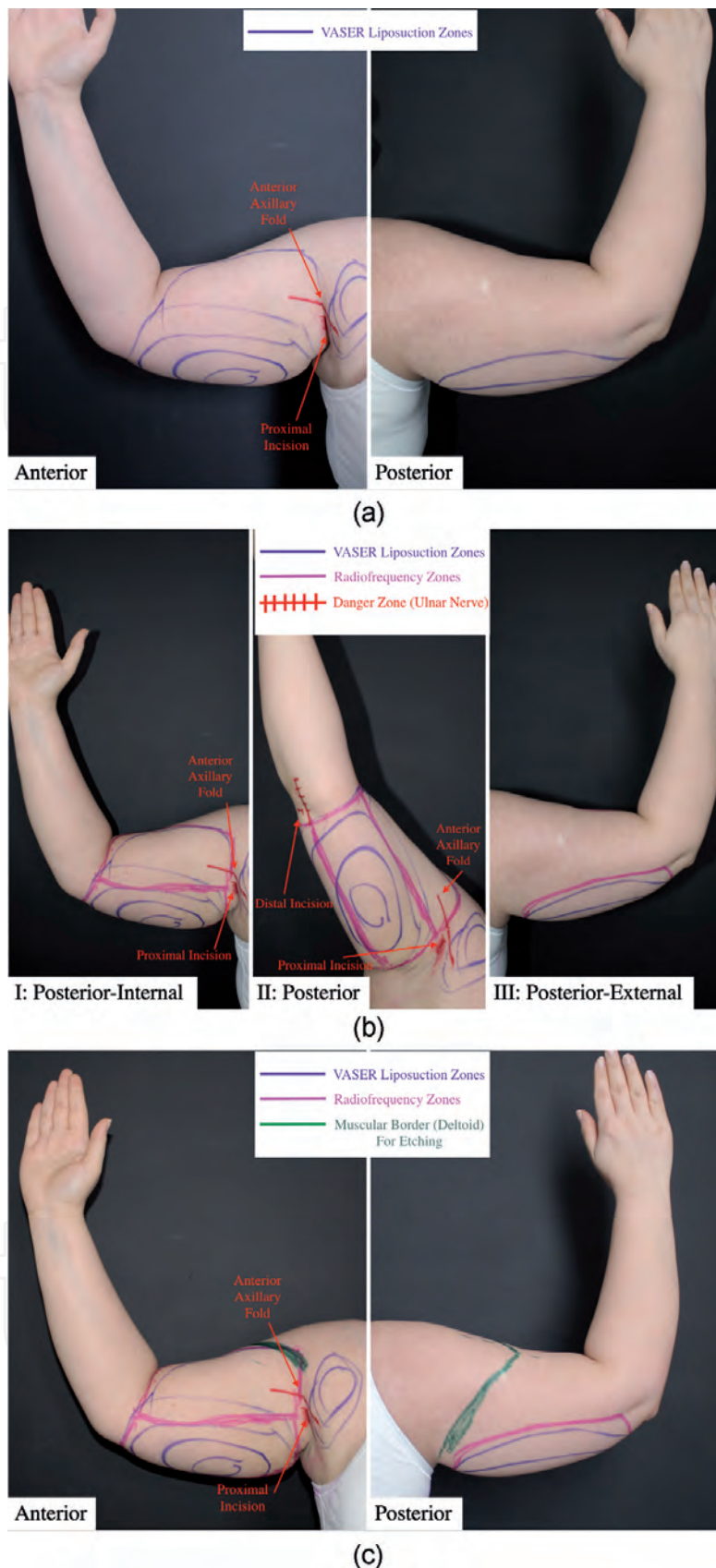


Figure 3. Markings for arm lipocontouring. (a) Areas of excess fat for debulking are marked (purple). Fat excess build-up is mostly in the posterior zone of the arm in the deep layer and is the focus of liposuction. (b) Areas of poor skin laxity for treatment with subdermal RF are marked (pink). The region of skin tightening treatment can extend anteriorly and posteriorly beyond the region of liposuction as required. The path of the ulnar nerve is marked as a danger zone. Distal access incision is made away from the position of the ulnar nerve; similarly, VASER liposuction and subdermal RF are avoided in this area. (c) If muscular etching is required, the muscle borders are palpated and marked (green). In females, commonly the deltoid is enhanced with careful superficial liposuction. In men, muscular etching may involve enhancement of deltoid, biceps, and triceps muscles.

Tumescent Fluid	Local Anesthesia	General Anesthesia
Ringer's Lactate	1000 cc	1000 cc
1% Lidocaine (without epinephrine)	80 cc	20 cc
Epinephrine	1 mg	1 mg
8.4% Sodium Bicarbonate	10 cc	0 cc

Table 1.

Composition of tumescent fluids used for local and general anesthetic (GA) case. Sodium bicarbonate is used as a buffer to decrease the pain of the acidic lidocaine when procedures are performed under local anesthetic. Accordingly, less lidocaine is required for analgesia when patients are under general anesthetic.

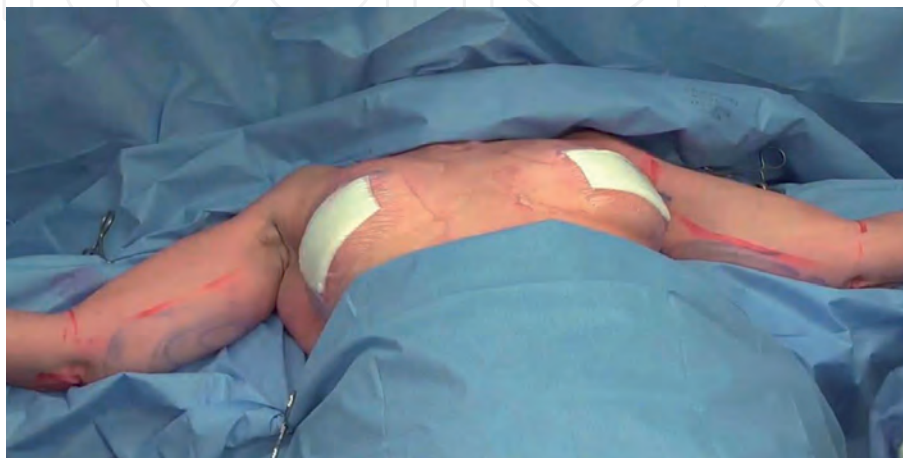


Figure 4.

Draping allowing for sterile 360-degree access to the patient's arms used in both local and general anesthetic cases.

5.3 VASER liposuction

With the use of PAL, the tumescent solution is infiltrated with a 3 mm basket cannula (**Figure 5**). The average infiltration of tumescent amount is approximately a ratio of 1:1-1:5. Vibration from PAL infiltration of tumescent solution can be a helpful sensory distraction for patients having surgery under local anesthesia. Furthermore, PAL allows for even infiltration throughout tissues even in presence of significant scarring due to previous liposuction or other non-invasive fat reduction procedures such as cryolipolysis or deoxycholic acid injections [23, 24]. A UAL probe of 3 mm is used for fat emulsification followed by lipoaspiration with SAL, again using a 3 mm cannula. Our standard VASER settings are between 60 and 70% on VASER mode for fat emulsification and pre-tunneling in both the deep and superficial fatty layers of the arm. Tissue treatment with VASER is always performed in both the deep and superficial layers even if only deep liposuction is planned. Superficial fatty layer treatment with VASER provides a modest degree of skin tightening which may be sufficient on its own or can be coupled with other technologies as necessary. Deep liposuction below the superficial fascia layer (deep/lamellar fat layer) can be carried out aggressively in order to debulk areas of excess adiposity in the posterior arm region with limited risk of creating contour abnormalities. It is important to address lipodystrophy around the distal arm/elbow region as well as the anterior and posterior axillary folds as necessary. These regions are best addressed with small and short cannulas for focused liposuction with limited restriction in arc of instrument movement.

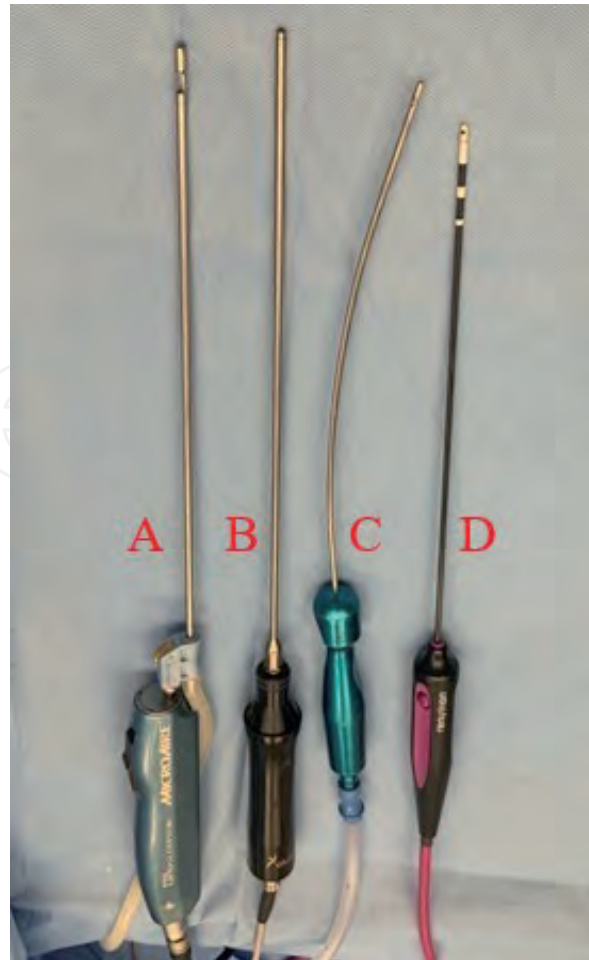


Figure 5.
Typical devices using during enhanced arm liposuction in our practice: (A) power-assisted device with gentle basket cannula for tumescence fluid infiltration (PAL, MicroAire surgical instruments, Charlottesville, VA); (B) VASER probe; (C) 3 mm curved suction-assisted liposuction (SAL) cannula; (D) subdermal radiofrequency (RF) device (Renuvion, 15 cm probe).

Strategic superficial liposuction may be carried out if required and/or when muscular etching is being performed. The authors try to avoid a complete 360° release of subcutaneous fat when possible as fat removal from the external zone of the arm is often limited or even unnecessary. Avoiding a complete 360° surgical release may allow for earlier resolution of swelling by decreasing the disruption of the venous and lymphatic systems. The addition of lateral chest wall liposuction if excess bulk is present there can provide added benefit by making the arms seem smaller as there is less tissue pushing the bulk of the arms out when adducted.

5.3.1 Artistic enhancement

To further enhance results of arm liposuction, we can incorporate the concepts of muscular etching [4] into the planning. For enhanced muscular definition and etching, careful compression while liposuctioning with a curved cannula is used to gradually create depression at the border of the muscle as desired. This is an advanced technique that should be gradually adopted as the surgeon gains experience and confidence in arm contouring [4]. Compression during liposuction elsewhere is not recommended as unwanted and difficult-to-correct depressions and irregularities can develop rapidly.

Removing a small amount of fat superficially to increase the definition of the anterior and posterior edges of the deltoid can push the aesthetic caliber of the result in arm liposuction. The posterior tricipital groove is not as clearly defined in

all patients but is a pleasing appearance in lean, more muscular female and male patients and can be enhanced with superficial liposuction when in synchrony with the patient's body shape. Biceps enhancement with superficial liposuction in the anterior bicipital groove in our practice is less common and mostly performed for male patients. Care must be taken to protect underlying neurovascular structures.

The addition of fat grafting at this stage to further enhance results, particularly into the deltoid and occasionally into the biceps muscles, can help patients achieve the desired muscular definition that they are looking for [4]. Typically, a small amount of fat grafting of less than 50 cc per arm intramuscularly can achieve this result.

5.4 Skin tightening with RF

The thin nature of the arm skin has made it a challenging area for liposuction (similar to the medial thighs). Assessing the skin quality is critical. Many patients with arm skin laxity would prefer to be left with some loose skin and avoid the telltale sign of a brachioplasty scar. The adjunct use of RF can also possibly concert a patient who may have required a full, long brachioplasty scar to a shorter scar, limited to the mid upper arm.

The use of subcutaneous RF techniques have been beneficial in further improving skin tightening and quality [6, 9]. RF subdermal skin tightening is more powerful and is particularly advantageous as it avoids targeting dermal chromophores and epidermal injury, thus can be used in any Fitzpatrick skin type, unlike transdermal RF and laser treatments [12].

5.4.1 Subdermal RF

When incorporating subdermal RF into the treatment plan, tumescence followed by UAL of the deep and superficial adipose tissue is carried out first. Treatment with subcutaneous heating of the Renuvion device follows completion of liposuction. The area for RF treatment is divided into ergonomic, accessible sections for the surgeon. Typically in the arm, we have three zones for RF treatment (posterior, posterior-internal, and posterior-external). There must be a minimum of two access points on the arm to allow for egress of the helium gas. Treatments in the zone are performed by the radial application of RF energy on the outstroke only at speed of 1-1.5 cm/s. Care is taken to avoid applying energy within a 2-5 cm arc of the access incision to prevent overtreatment and the possibility of a burn. Each zone is treated with three passes only, then we move on to the subsequent area. Once all areas are treated, we retreat all zones with another three passes. This 3 + 3 technique avoids the deposition of excessive heat energy and possible injury. As per Duncan, a 10 x 15 cm segment of tissue is usually treated with approximately 5 kJ [14]. Surface skin heating is not an endpoint with this technology, unlike other energy devices, and may actually imply excessive energy delivery. Care is taken to avoid tenting of the probe underneath the dermis and to keep the probe in constant motion during energy activation. After completing RF, fine cannula SAL is gently used as a final stage to evacuate any residual helium gas and to correct fine irregularities.

Some surgeons advocate for the creation of an "internal seam" by depositing additional RF energy along the posterior border of the arm ("triceps midline meridian") [6]. We typically avoid concentrating energy deposition in a given location as it can result in irregular contraction and palpable fibrosis. Sufficient tissue tightening and circumferential volumetric contraction can be achieved with a systematic application of RF energy with limited overlapping.

5.4.2 Transdermal RF

Examining quality of a patient's superficial skin is very important. Combining subcutaneous RF technology with transdermal RF devices can enhance the result even further. A number of such technologies exist. In our practice, (micro)needling RF with Fractora or Morpheus8 (InMode) or Profound (Candela Medical) can be used to enhance the final result. RF (micro)needling parameters have been described elsewhere [15] and are beyond the scope of this chapter. One to three treatment sessions may be required to achieve desired improvements in skin quality. The first RF (micro)needling treatment session may be performed concurrently with more invasive surgical procedures, including liposuction, with or without subdermal RF, and/or brachioplasty to optimize anesthesia and post treatment recovery. Generally, three to six weeks of recovery time are allowed between treatment sessions. When picking the right technology, multiple factors must be considered, including specific patient concerns, tone and texture of the skin, and Fitzpatrick skin type.

5.5 Brachioplasty

Surgical excision of excess skin of the arm is the gold standard in improving arm contour; however, the conspicuous and sometimes hypertrophic scarring in a publicly visible area can make this option undesirable. Previously, surgeons have attempted to describe limited brachioplasty approaches by varying the length and position of the surgical scar, ultimately at the expense of the improvement that can be achieved. Small scars such as axillary-only obtain limited changes in arm contour, whereas extended brachioplasty scars from distal to the elbow and including the lateral chest wall result in transformative changes to the patient's shape in their arm and chest. We recognize that excision of skin in some patients is unavoidable to achieve desired results. A detailed discussion of brachioplasty surgery is beyond the scope of this chapter [25].

We advocate and implement a two-stage approach in order to limit scar length without compromising the amount of improvement and arm contour. In patients with excessive fatty tissue who are unable to lose weight through lifestyle changes, we first perform liposuction with or without skin tightening to recruit as much skin retraction as possible. As a second stage, a brachioplasty procedure with possible further skin tightening can be performed, thus hopefully resulting in a shorter surgical scar. On many occasions, patients are satisfied enough with the results of the first stage, that they often decline skin excision and request further enhancement with liposuction with or without skin tightening.

5.6 Adjunct non-surgical treatments

Treatment of sun damage to the skin with sunscreen, topical products, and laser treatments to improve skin texture and pigmentation changes should also be considered.

6. Postoperative care

Patients are all placed in a compressive garment post-operatively. Surgical garments are used for the first two weeks. Afterwards, patients are allowed to change into commercially available seamless, zipper-less compressive garments (such as Spanx™ or athletic compression shirts). The larger amount of fluid generated

with UAL with or without additional RF treatment occasionally requires the use of drains, brought out through the posterior elbow. Alternatively, the elbow incision is left open to allow for drainage. Most commonly a 7 mm drain is used if required. They are asked to try and keep their arms elevated above their hearts when seated or sleeping for the first week. Patients are encouraged to begin lymphatic massage after one week. Patients are instructed to avoid any heaving lifting (above 10 lb) or vigorous exercise until four to six weeks post-surgery. After this period, activity level can be gradually increased as tolerated. Gentle range-of-motion is never restricted.

7. Clinical cases

7.1 Case 1: liposuction

This 41-year-old patient presented to our practice desiring enhanced contour of the arms along with her trunk. She was 5'7", 144 lb., and worked out on a regular basis. She found the area of her arms were a persistent problem despite her workout regime. She underwent trunk and arm liposuction under general anesthetic. The arms were infiltrated with 500 cc of tumescent fluid per side and 200 cc of lipoaspirate was removed per side using VASER UAL. Liposuction was carried out predominantly in the deep layer with a small amount of superficial liposuction in the region of the deltoid groove to create the desired level of muscle enhancement for the patient. Pre- and post-operative results at 1 year are shown in **Figure 6**.

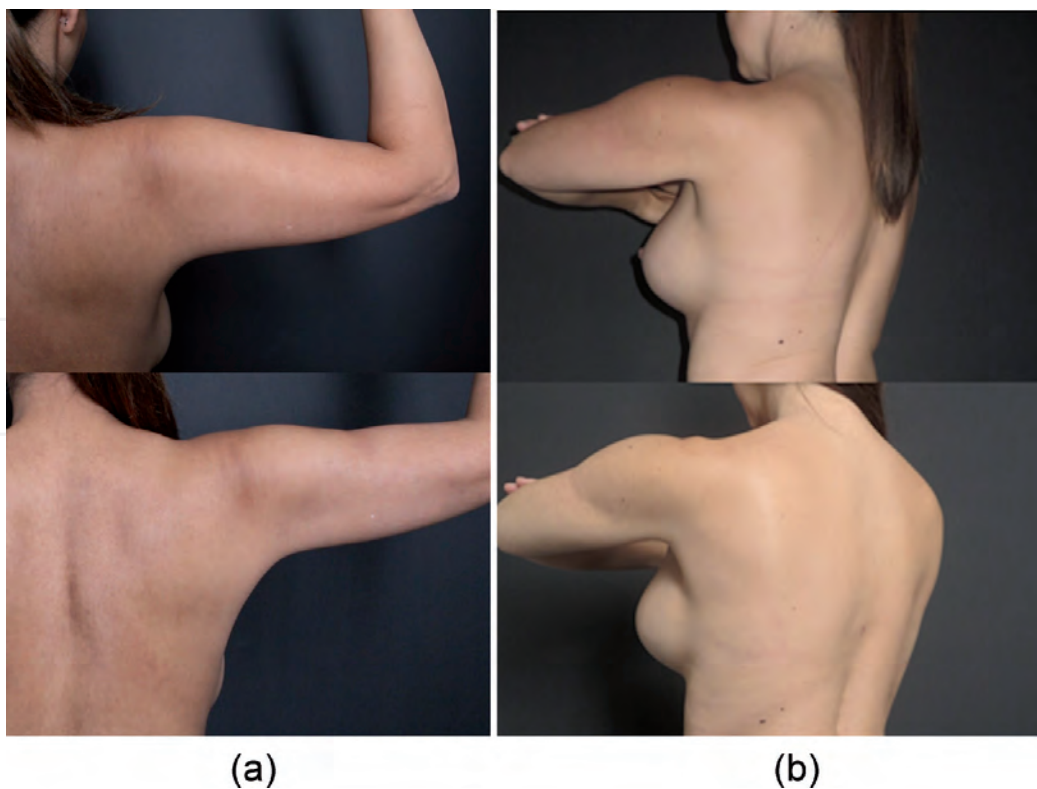


Figure 6. Liposuction of the arms (case 1). This 41 year-old female with normal BMI and active lifestyle underwent arm and trunk liposuction for improved definition. Liposuction was performed with VASER UAL. Gentle liposuction of the superficial fat layer was performed to enhance the deltoid muscle and impart a more toned appearance of the arms. Results are shown pre-operatively and 1 year postoperatively on the right side posteriorly (a) and left side obliquely (b).

7.2 Case 2: liposuction and subdermal RF

This 51-year-old woman presented to our practice with concerns regarding the size of her arms and avoided sleeveless shirts. She was 5'2" and 163 lb. Her medical history was notable for a previous thyroidectomy and her only medication was levothyroxine. The patient was noted to have diffuse upper arm lipodystrophy with significant striae. The distance from the bicipital groove to the most dependent area was greater than 10 cm. She did not wish to undergo any excisional/scarring procedure, even though it was made clear this would be the gold standard of treatment in her situation.

The patient underwent arm liposuction, along with a concomitant facial procedure, under general anesthesia. Each arm was infiltrated with 750 cc of tumescent fluid using PAL system, then VASER UAL was performed (60%, VASER mode, 3 mm VASER probe) in both the deep and superficial planes. Liposuction was carried out with a 3 mm standard liposuction cannula to remove 650 cc of lipoaspirate on each side from each arm. Subdermal RF treatment was then performed with Renuvion (80%, 2 L/min, for 3 + 3 passes as described above). No drains were used. Pre- and post-operative results at 1 year are shown in **Figure 7**. The option of repeating the RF at one year to obtain further skin tightening was disclosed pre-operatively. At one year post surgery, the patient was thrilled with her results and declined further RF or alternative treatments.

The typical operative sequence of arm lipocontouring with VASER UAL and subdermal RF is outlined in **Table 2** and demonstrated in Video 1 (<https://drive>).

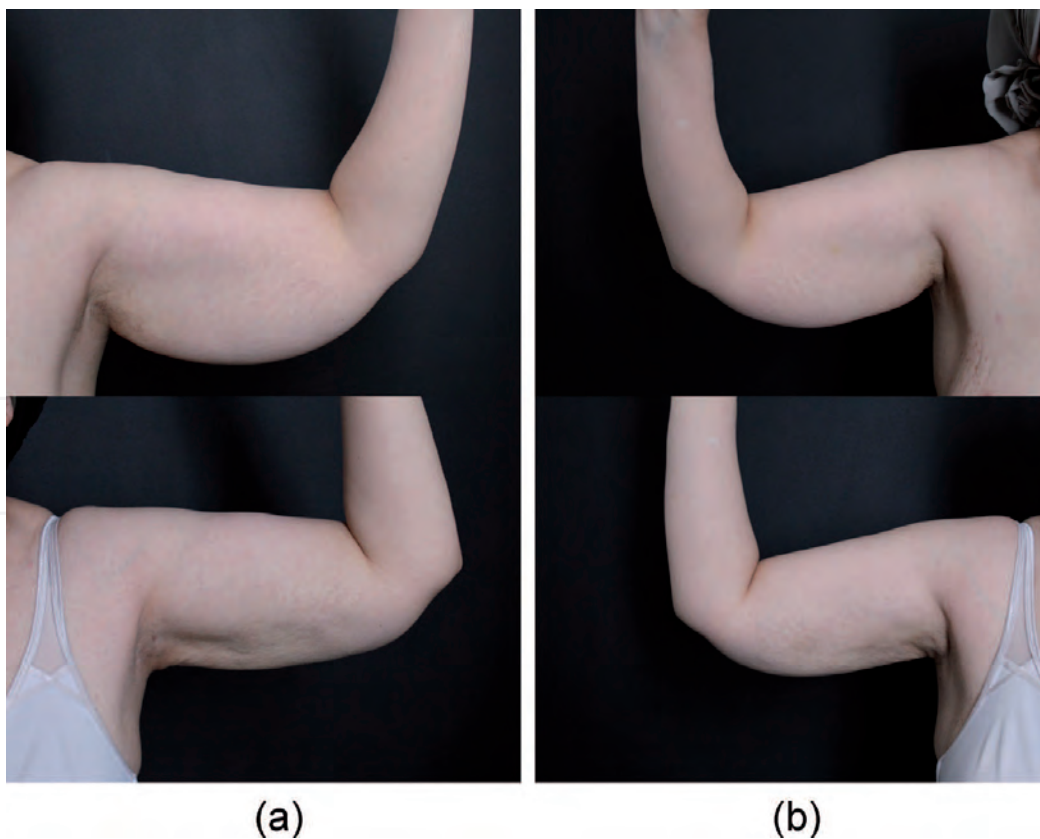


Figure 7. Liposuction and subdermal RF of the arms (case 2). This 51-year-old woman with BMI of 29.8 presented with lipodystrophy, skin excess, and poor skin quality and striae. She was averse to brachioplasty scar. As such, a staged approach was proposed beginning with VASER UAL (650 removed from each arm) and subdermal RF (Renuvion). Results are shown pre-operatively and 1 year postoperatively on the left (a) and right (b) sides. She was very pleased with the outcome following the initial procedure and elected not to proceed with further liposuction and subdermal radiofrequency treatments as planned.

Summary of Operative Approach to VASER UAL and RF Skin Tightening

Pre-operative:

Markings: Patient is marked for proximal and distal access incisions, zones of excess adiposity requiring VASER liposuction, and, if indicated, regions of RF skin tightening. If muscular enhancement is planned, the borders of the arm muscles (deltoids +/- triceps) are palpated and marked. The course of the ulnar nerve at the cubital tunnel is marked as a “no-go” zone.

Intra-operative:

Positioning: Patient is placed supine with arms extended on arm boards. The arm may be flexed at the shoulder and elbow at 90 degrees throughout the case as necessary to reach the posterior and external zones of the arm adequately. Under local anesthesia, patient can perform this movement by themselves; otherwise the limb is positioned by an assistant. To allow free movement, bilateral upper extremities and anterior chest are prepped and the extremities are free-draped.

Anesthesia: If the procedure is performed under local anesthesia, the patient is offered Pro-Nox for comfort, which they self-administer. Additionally, they may be offered MKO prior to the procedure as an anxiolytic and mild oral sedative. Alternatively, the procedure can be performed under IV sedation or general anesthetic.

Measurements: Arm circumference can be taken at 2 points along the upper arm prior to start of treatment and at the end of treatment with a sterile tape measure. These measurements are of particular benefit to denote and correct asymmetry between the two sides.

Incisions: Access incisions are infiltrated with local anesthetic and a 1 cm skin incision is made with scalpel. Care is taken to stay away from the ulnar nerve distally.

Tumescence: The zones of planned treatment are infiltrated with tumescent fluid until appropriate turgor is reached (variable between patients and dependent on body habitus). It is important that both the superficial and deep fat layers are adequately infiltrated.

VASER UAL: Access ports are inserted to protect skin incisions. VASER pre-treatment is performed first with typical settings of 60% on VASER mode in superficial fat layer. Deep fat layer may be treated with 60% on VASER or Continuous mode, depending on amount of adipose excess. End point is loss of tissue resistance to VASER probe. Liposuction is then performed with a small (3 mm cannula). Care is taken to debulk in the deep adipose layer only. Superficial liposuction is performed carefully and only in areas where the muscle border is intended to be enhanced.

RF Skin Tightening: Next, RF skin tightening is performed if indicated. We prefer Renuvion and use settings of 80% power and 2 L/min of helium gas flow. Treatment is performed with 3 passes initially followed by another 3 passes a few minutes later to allow sufficient tissue thermal relaxation (total of 6 passes).

Alternatively, if Bodytite is utilized, we typically use internal and external temperature cut-offs of 70° C and 40° C. Skin is continuously monitored for overheating, redness, and end-hits are avoided with all technology devices. Minimal liposuction is performed afterwards to remove any debris and gas.

Closure: Proximal incisions are closed with deep-dermal 4-0 Monocryl suture. Typically, the distal incision is left open and dressings are used to soak up excess drainage. If necessary, a 7 mm Jackson-Pratt drain may be utilized, exiting from distal excision.

Postoperative:

Garment & Drain: Patient is placed in compression garment for 6 weeks postoperatively. Typically, the distal incision is left open and dressings are used to soak up excess drainage. If any drains are used, they are removed after 30 cc or less of serosanguinous drainage in a 24 hour period has been reached.

Table 2.

Summary of our typical approach to arm lipocontouring with VASER UAL and subdermal RF skin tightening.

google.com/file/d/1IUFLpe7koOBtZf7dCtcGFkU-RBsieNQq/view?usp=sharing) for a different patient.

7.3 Case 3: liposuction, subdermal RF, and brachioplasty

This 53-year-old woman was seen in consultation for changes to her arms following massive weight loss of 130 lb. through healthy lifestyle changes in diet, and exercise. She was 5'7" and 183 lb. at time of assessment. The patient was concerned with the quantity of excess skin, as well as the poor quality, noted by striae, poor elasticity, and pendulous excess skin. After discussing the advantages and disadvantages of various procedures, the decision was made to proceed with

bilateral extended brachioplasty with UAL liposuction and subcutaneous RF to improve the quality of the remaining skin. The nature of the scarring involved was discussed in detail.

Under general anesthesia, 1000 cc of tumescence fluid (**Table 3**) was infiltrated into each arm and lateral chest wall using a small basket PAL cannula. A 3 mm VASER probe was used for fat emulsification, followed by liposuction to remove 400 cc from each arm. Surgical excision of the redundant skin was carried out to remove 588 g of tissue from the right arm and 515 g of tissue from the left arm. Subdermal RF (Bodytite) was used to heat the remaining skin prior to final subcuticular closure to achieve further skin tightening. A drain was used on each side. Pre- and post-operative results at 1 year are shown in **Figure 8**.

	RIGHT ARM	LEFT ARM
Proximal Circumference (cm)	PRE: 50 POST: 34	PRE: 47 POST: 34
Distal Circumference (cm)	PRE: 39 POST: 28.5	PRE: 36 POST: 28.5
Tumescence (cc)	1000	1000
Lipoaspirate (cc)	400	400
Skin Excision Weight (g)	588	515

Table 3.

Intraoperative measurements and weights of tissue excised from case 3. Circumference of the arm is taken prior to surgery (PRE) and intraoperatively following liposuction and excision (POST) to ensure relative symmetry at the end of the procedure. These measurements also help highlight pre-existing arm size asymmetries and differences in relative amount of tissues excised from each side.

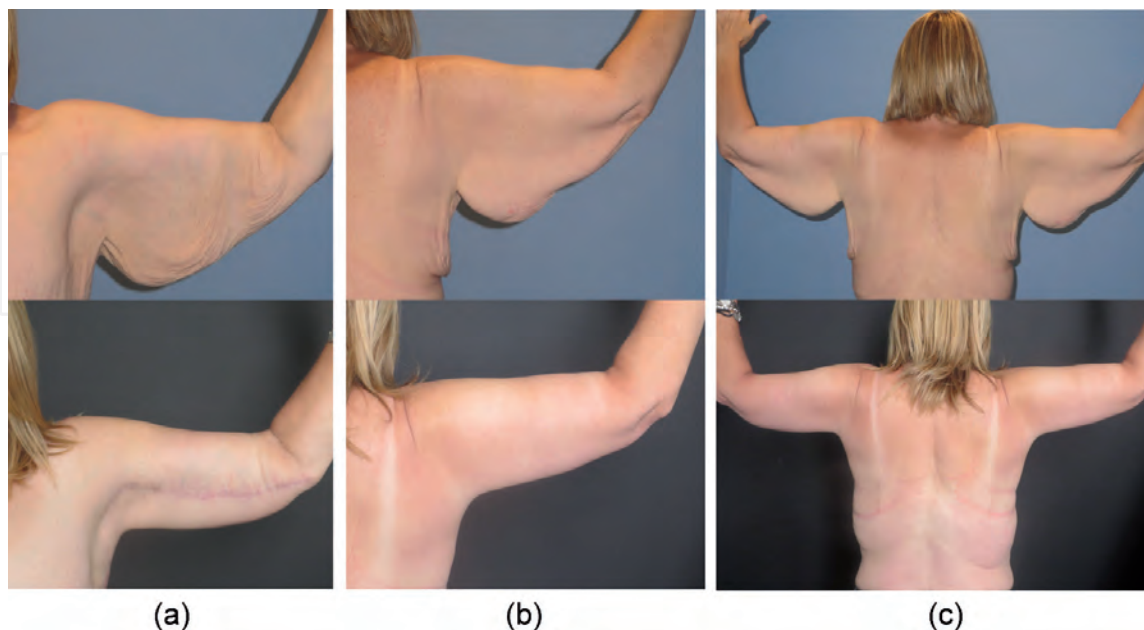


Figure 8.

Liposuction and subdermal RF of the arms coupled with extended brachioplasty. This 53-year-old PDWL woman presented with lipodystrophy and significant skin excess and poor quality of the arms and extending to the lateral chest wall. She underwent VASER UAL and extended brachioplasty. The remaining skin regions anterior and posterior to the brachioplasty excision were treated with subdermal RF (Bodytite) for further improvement in skin retraction and quality. Results are shown pre-operatively and 1 year-postoperatively from a left anterior (A), right posterior (B), and bilateral posterior (C) perspective.

8. Pearls

8.1 Surgery under local anesthesia with conscious sedation

One of the greatest advantages to minimally invasive approaches to arm contouring is the ability to perform the procedure under local anesthesia safely and comfortably for both the patient and the surgeon. A complete medical history, physical examination, and review of patient's medications and allergies is integral to safe administration of any medication, including for procedures performed under local anesthesia with or without sedation.

8.1.1 Nitrous oxide (*Pronox*)

We commonly utilize Pro-Nox, which is a combination of 50% nitrous oxide and 50% oxygen delivered through a one-way valve. The patient holds the mouthpiece and inhales the gas for comfort as needed. The device inherently minimizes risk of overdose as the patient is unable to hold the mouthpiece if they become too drowsy. It is therefore important not to assist the patient in holding or controlling the mouthpiece device. The use of nitrous oxide is well-established in dental literature and has been adopted to many dermatologic and aesthetic procedures, including tumescent liposuction, as a safe analgesic adjunct [26–28]. Additional monitoring with a pulse oximeter is advised for longer procedures. Surgeons must be aware of contraindications to its use which include but are not limited to pregnancy, certain pulmonary diseases (COPD, cystic fibrosis), recent tympanic membrane surgery, claustrophobia, and intoxication, etc. Adverse effects are mild and infrequent and include emotional lability (most commonly laughter and euphoria), nausea, and dizziness. It has a quick onset and recovery times are 5 to 10 minutes allowing for patients to drive themselves home following smaller local procedures [26].

8.1.2 Oral sedatives (*lorazepam, MKO lozenges*)

In order to reduce any stress or anxiety associated with the procedure, we have traditionally administered sublingual lorazepam to patients undergoing procedures under local anesthesia lasting greater than 45 minutes or those with underlying anxiety. Recently, oral formulations of midazolam, ketamine, and ondansetron have become available as prefabricated lozenges (MKO Melt, ImprimisRx, San Diego, CA), which can also be prepared at any compound pharmacy (Midazolam 3 mg, Ketamine 25 mg, Ondansetron 2 mg). We have found this new oral combination to be highly effective for longer duration procedures under local anesthesia, including arm lipocontouring. The medication provides anesthetic, sedative, and antiemetic effects that set in within 15 minutes and 30 minutes to peak effect. Anesthetic and sedative effects can last up to 4 hours after administration [29] and, as with any form of sedation, the patient is monitored post procedure until discharge criteria are met and released to the care of a responsible adult for 24 hours.

9. Pitfalls and complications

The usual complications associated with liposuction can be seen in arm lipocontouring including infection, seroma, irregularities, sensory or motor nerve injury, the need for further liposuction enhancement, and loose skin requiring (additional) RF treatment or skin excision. The added complication of burns to the skin with any energy-device (UAL or RF) must also be discussed with the patient preoperatively.

9.1 Asymmetries

As with any other procedure where two sides of the body are treated, it is important to note and educate patients on any pre-existing asymmetries during the consultation process and prior to any procedure. The circumference of the arm is measured at two landmarked positions on each arm prior to surgery. The measurements are confirmed again intraoperatively prior to start of surgery and at the end of surgery to ensure relative symmetry. It is important for surgeons to remember, and educate patients, that it is not how much fat or skin excess is removed that needs to be similar but rather the tissue that remains should be symmetric.

9.2 Irregularities

One of the most significant challenges with any form of body contouring, but particularly in the arm where there is less fat and high public visibility, is avoidance of irregularities and unsightly adhesions. Failure to address loose skin or poor quality in the appearance of skin can set the patient up for an undesirable or unrealistic outcome. The key to smooth liposuction is to recognize the superficial and deep adipose layers and make sure to debulk only the deep layer. Liposuction of the superficial layer of fat will result in visible divots and difficult-to-correct irregularities and asymmetries. Of course, when done carefully, superficial liposuction and purposeful creation of contours and shadows is the underlying principle and technique of muscular etching. We advise all surgeons to master lipocontouring of the deep fatty layer of the arm prior to attempting muscular etching. When performing muscular etching, less is more. It is also important to palpate the patient's own muscular boundaries and aim to only enhance the muscle borders rather than to artificially enforce muscles on the soft tissues to avoid odd-appearing contours, especially with movement and muscle activation.

Several principles can help surgeons avoid irregularities, in addition to staying in the deep adipose layer. We advocate using a small cannula (3 mm). A curved cannula is optimal for reach in cylindrical regions such as the arms (and medial thighs) and can help to enhance the smooth curvature of muscle boundaries where needed. We have a low threshold for performing fat equalization following aspiration as in the SAFE technique [30] with either a power-assisted or handheld basket cannula (off suction) if any irregularities are noted. When using energy-based devices (VASER or RF skin tightening), excessive heat application can result in fibrosis and uneven adhesions. As covered below, the key to any energy application is to protect the entry site, avoid end-hits and tenting up the device tip against dermis, and keeping the handpiece in constant motion to avoid such adverse outcomes.

9.3 Excess skin

We have found that energy devices provide a treatment gap for patients with mild to moderate skin laxity (with or without associated lipodystrophy) and those who are scar intolerant. We advise every patient that, while significant improvement in skin laxity and quality can be achieved with energy-devices, no alternative treatment is equivalent to lax tissue excision with surgery. There is also variability in individual response to skin tightening treatments, and multiple treatments, or even possible skin excision, may be indicated in the future.

The best candidates for energy-based minimally invasive skin tightening are those with mild to moderate skin laxity. PDWL patients and even those with significant striae typically have an irreversibly damaged dermis and are better suited for excision surgery. This does not mean that skin tightening with RF cannot

be incorporated into their treatment journey to provide advantageous results. We often discuss and offer a staged approach to treatment of these patients beginning with VASER liposuction of the deep layer to debulk the arm and RF treatment of the subdermis. At the second stage, brachioplasty is performed. With this two-stage approach, some improvement in the skin laxity is achieved by recruiting the patient's own skin tightening and the length of the excisional scar is more shortened, particularly at the elbow, axilla, and the lateral chest wall. In some cases, additional treatments with subdermal RF may also be performed.

9.4 Burns and tissue necrosis

All energy-based devices, whether utilizing ultrasound, RF, or laser, generate heat that results in soft tissue skin tightening as a primary or secondary treatment goal. Skin burns and tissue necrosis, however, can result from too much energy and heat application. In order to avoid excess energy accumulation in any treatment area, the device is kept in smooth motion, end-hits are avoided, tissues are well-hydrated, and the incision and immediate surrounding skin are protected with use of a port and energy application is avoided in a 2-5 cm radius around the entry site.

Along with more skilled application of technology, energy-based devices themselves have evolved to provide more tissue protection and safety. The earlier generations of UAL devices generated high levels of ultrasound energy, thought to underlie most UAL complications such as burns and seroma formation. The current generation of VASER device delivers notably lower amounts of ultrasound energy to the soft tissues, especially when using the pulsed (VASER) mode, while still efficiently and effectively emulsifying fat and supporting skin tightening [5].

RF devices have undergone improvement as well. As described earlier, bipolar devices have developed to better manage direction of heat and energy application than monopolar devices. Bodytite incorporates internal and external temperature monitors with safety shut-offs if the tissue heats beyond temperature boundaries set by the surgeon. Perfusion imaging assessment using indocyanine green imaging and optical coherence tomography demonstrated no compromise of subdermal perfusion following treatment with a bipolar RF device [12].

We use Renuvion as our preferred subdermal RF device in the arm for its efficacy and safety features. Renuvion generates a low-current RF energy, the depth of heating is minimal, and overheating of the tissues with multiple passes is less likely. As tissues are treated, the fibroseptal bands coagulate, contract, and increase in impedance. The plasma beam thereby quickly alternates to target different tissues adjacent to the device tip in a 360° fashion, as untreated tissues present lower impedance. Surrounding untreated tissue remains cool, allowing for heat to dissipate quickly post treatment by heat conduction. Energy flow is thereby fractional resulting in effective FSN contraction without excessive heating of the tissue field and, in particular, the dermis. The difference in subdermal and skin surface temperatures is much larger with Renuvion, allowing for safe skin temperatures to be maintained without the need for temperature monitoring. With subsequent passes in the same region, the energy continues to follow the path of least resistance (lower impedance) and therefore preferentially treats previously untreated tissue. With multiple passes, untreated tissues are optimally targeted, and over-treatment of any single area is avoided [14].

Regardless of the device used, the risk of burn is not entirely eliminated. Should there be any concern about too much heat application and burn potential, the area should be cooled with a cold moist dressing immediately. We apply topical dimethyl sulfoxide (DMSO) for any areas of potential skin compromise beginning immediately postoperatively and continued at home by the patient as long as required.

DMSO is a topical anti-inflammatory agent that has been shown to be beneficial to wound healing and analgesia [31]. Any areas of skin or tissue necrosis must be cared for in accordance with principles of burn and wound healing.

9.5 Seroma

The lymphatic system in the arm courses alongside the venous system and is enveloped by the deep fascial system. With any excisional surgical approaches, superficial dissection is essential to preserve the lymphatic network and prevent issues with seroma formation. Although energy-based minimally invasive devices tend to produce more postoperative serous drainage, the lymphatic system is not compromised. Dayan et al. [12] demonstrated the safety profile of subdermal RF application using indocyanine green lymphatic imaging, which demonstrated no compromise of lymphatic channels, peristaltic function, or subclinical lymphedema post-treatment. Instead of circumferential treatment of the arm (360-degree liposuction with or without skin tightening), we advocate leaving behind a bridge of undisturbed skin and subcutaneous tissues at least 5 cm wide along the lateral border of the arm to decrease postoperative swelling. Gravity-based drainage of fluid from the elbow incision is sufficient, although drains are occasionally used.

9.6 Nerve injury

9.6.1 Ulnar nerve

The ulnar nerve arises from the medial cord of the brachial plexus and travels deep to the fascia in the upper portion of the arm. It becomes more superficial when it pierces the intramuscular septum 8 cm superior to the medial epicondyle at the arcade of Struthers and travels medial to the triceps before passing through the cubital tunnel posterior to the medial epicondyle. Surgical incisions must be placed away from the ulnar nerve and placed either on the radial side of the elbow or anterior to the medial epicondyle if more ulnar-sided access is necessary. The path of the ulnar nerve at the elbow is marked and liposuction or energy application is avoided in this critical region.

9.6.2 Sensory nerves

The medial brachial and medial antebraichial sensory nerves arise from the medial cord of the brachial plexus and travel just superficial to the deep fascia along with the basilic vein. In the distal 1/3 of the arm, sensory branches can be encountered (often 7-14 cm proximal to the medial epicondyle) [2]. The nerves can be injured during dissection of the distal 1/3 of the arm in brachioplasty procedures. Direct nerve damage or transection is less likely with minimally invasive approaches.

9.7 Infection

Less invasive approaches to arm contouring tend to be associated with less postoperative major complications than excisional approaches with brachioplasty. Although no studies that directly compare the two approaches in comparable groups have been conducted to date, trends can be drawn from available large population databases. Studies of patients enrolled in the CosmetAssure database from 2008 to 2013 [32, 33] revealed that major complications occurred in 0.7% of patients undergoing liposuction alone and in 1.3% of brachioplasties alone. When brachioplasty

was combined with liposuction, overall rate of major complications increased to 3.6% although the study was limited to liposuction as a procedure and not necessarily specific to liposuction of the arms per se. BMI equal or higher than 30 kg/m² was found to be an independent risk factor for infection. To minimize risk of infection with arm contouring procedures, complete sterile preparation and draping is required, even if a less-invasive approach is taken. Patients are encouraged to achieve a healthy BMI as lipocontouring is not a replacement for healthy lifestyle, and a normal BMI can optimize patients for better recovery as well as better results. Patients who are PDWL are at higher risk of nutritional deficiencies and are encouraged to undertake a complete healthy protein-rich diet prior to surgery [34].

9.8 Learning curve and management of surgeon/patient expectations

As with the adoption of any new surgical technique or technology into one's practice, it is of paramount importance to recognize the learning curves associated with novel approaches and to proceed cautiously. Following mastery of the device itself—learning how to operate safely with balance of tumescence, zones of treatment, energy settings, depth of device placement and direction and speed of device manipulation—patient selection and management of expectations are key to success. Younger surgeons are encouraged to establish comfort with location and planes of deep versus superficial fat pockets in the arms and gain success with debulking of excess deep fat of the posterior region of the arm before attempting superficial liposuction and muscular etching to avoid unwanted irregularities and contours. Similarly, when implementing RF skin tightening, it is best to select cases of mild skin laxity and ptosis in which treatment response is likely to be in keeping with both patient and surgeon expectations. It is always the gold standard to offer excisional surgery to patients with significant skin laxity, striae, and/or severe photoaging, where the damaged dermis can be less reliable in terms of contraction and neo-collagenesis upon which RF depends. Depending on location of skin excess, whether it is mostly involving the axilla region, the entire dependent portion of the arm, extending to the elbow, or extending to the chest wall, the patient may be best treated with axillary short scar brachioplasty, traditional brachioplasty, extended brachioplasty to below elbow, or extended brachioplasty to lateral chest as indicated [25]. While patients may be deterred by the conspicuous brachioplasty scar, it is important to emphasize trade-off between scar and amount of arm contouring and skin tightness desired by the patient. A patient with significant skin excess who wants ideal arm contour and as much skin tightness as possible will never be satisfied with results achieved with RF skin tightening alone. Conversely, a patient who is completely intolerant of scars but is satisfied with even mild to moderate improvement of skin laxity, will be well-served with RF skin tightening. Although RF skin tightening can be safely combined with excisional surgery concurrently, we again advocate that the surgeon establishes comfort with the technology first. Furthermore, we recommend utilizing lower energy settings and avoiding application of energy within a 2-5 cm margin of incision edge to ensure skin viability and uncompromised wound healing.

10. Alternative treatment options and their limitations

10.1 RF-assisted liposuction (RFAL)

RF-assisted liposuction is an alternative means of utilizing RF energy to emulsify fat and tighten soft tissues as an adjunct to correction of lipodystrophy with

liposuction. Utilizing the RFAL technique, RF is applied to the subcutaneous tissues following infiltration with tumescence. Thereafter, excess fat and fluid is removed with SAL or PAL [35]. RFAL is a useful alternative technique that achieves many of the same goals as contouring with VASER liposuction and skin tightening with RF. There are two advantages to separating the process of lipocontouring and soft tissue tightening: one lies in the flexibility to harvest viable adipocytes with VASER liposuction that can then be utilized for fat grafting if needed [7, 8], and the second is the reduced disposable cost of utilizing the single-use RF handpiece only for patients that truly need additional skin tightening. Additionally, by performing liposuction prior to RF energy application, tissue heating is optimized as the volume of intervening heat-resistant fatty layer will be decreased, and the subdermis and FSN better exposed as desired targets of energy application [14].

10.2 Laser-assisted liposuction

In addition to VASER and RFAL, another modality that utilizes energy for adipocyte lysis prior to aspiration and offers a degree of skin tightening is Laser-assisted liposuction (LAL). Multiple systems are marketed that utilize 1064 nm Nd:YAG, 1320 nm Nd:YAG, and 980 nm diode lasers conducted via an optical fiber within a cannula and placed in direct contact with adipose tissue. The laser produces photomechanical and photothermal effects that result in adipocyte lysis, small vessel coagulation, dermal coagulation, and subsequent neocollagenesis [36, 37]. While to our knowledge there are no published reports that directly compare VASER to LAL, a similar amount of skin retraction could be achieved with LAL (between 11 and 17%) [36, 37]. There are some limitations to the use of LAL: Since absorption of laser energy results in adipocyte rupture and death, this technique eliminates potential harvest of viable fat cells that can be utilized for fat grafting [36]. There is also a steep learning curve associated with LAL. Duration of laser activity in tissues is variable and affected by tissue thickness and volume as well as overall treatment size, previous scarring and fibrosis, and skin laxity. Loss of resistance denotes adipocyte lysis and is utilized as an endpoint. Surgeons must be vigilant to avoid excessive energy build up at the fiber tip that can rapidly build up and result in tissue necrosis [36].

10.3 Water jet-assisted liposuction

Water jet-assisted liposuction (WAL) targets a thin fan-shaped water stream into soft tissues to release fat lobules from the matrix. WAL can yield lipoaspirates well-suited for fat grafting but does not improve overall liposuction results or skin retraction after treatment [38, 39]. Although the aspirated fat is of excellent quality with minimal bleeding, the time required to aspirate even one area was found to be inefficient in our hands and excessively prolonged operative time in combined procedures. This, and the lack of improved outcome in liposuction or skin quality, made WAL a nonviable option in our practice.

10.4 Cryolipolysis

Cryolipolysis is a useful non-invasive adjunct for reduction of fullness in patients with spot or localized fat excess and otherwise good skin quality. Applications of cryolipolysis in the extremities is generally limited as most patients require contouring of the entire upper length of the extremities with skin quality frequently also needing to be addressed. Rivers [23] has described the use of multiple coupled cryolipolysis applicators to broaden inclusivity of patients to those with more fatty excess, but this technique can be costly for patients. We reserve cryolipolysis for

treatment of patients who seek only non-invasive treatments, are young with good skin quality and elasticity, and have mild localized areas of adipose excess in the upper arm or anterior axillary region. Remaining patients are treated according to our proposed arm contouring treatment algorithm.

10.5 Deoxycholic acid

Deoxycholic acid (Kybella (USA) or Belkyra (Canada) Allergan Pharmaceuticals, Markham, ON, Canada) is an injectable treatment for subcutaneous fat excess, currently approved for improvement of submental fat. Deoxycholic acid induces adipocytosis and local inflammatory response to result in improved neck contour [24]. Off-label treatment of the upper arms with deoxycholic acid has been described [24], although to our knowledge no studies of large patient sizes, long-term results, and potential complications have been published. As one of the clinical trial centers for use of deoxycholic acid in the submental region, we have extensive experience with the product and its method of action. Given its localized treatment area, need for multiple treatments, significant post-treatment swelling, lack of improvement of skin quality, need for high volumes of product and corresponding cost, and residual subcutaneous fibrosis that can impair future surgical treatments (such as with liposuction), we do not recommend use of deoxycholic acid for arm contouring. Adverse neurotoxic effects of deoxycholic acid resulting in demyelination of nearby nerves with resultant anesthesia/hyesthesia of sensory nerves and weakness of motor nerves, is another limiting factor in broadened use of this drug in body contouring [24].

11. Conclusion

Arm liposuction is a very rewarding procedure for both patients and surgeons that can be easily performed under local anesthetic or in combination with other procedures under general anesthetic. The addition of energy-based devices has expanded treatment options for patients with arm contouring concerns who either do not desire significant brachioplasty excisional surgery or who do not have enough excess skin to warrant the large incisions. These technologies can also be used to enhance the results even in our more traditional brachioplasty patients.

Acknowledgements

The authors would like to acknowledge Shantel Lultschik and Brenda Wright RN for their assistance in editing this chapter.

Conflict of interest

Dr. Julie Khanna is a consultant for VASER, Inmode, Renuvion, and Allergan. Dr. Maryam Saheb-Al-Zamani has no interests to disclose. There were no financial conflicts of interest in preparation of this chapter.

IntechOpen

IntechOpen

Author details

Julie Khanna* and Maryam Saheb-Al-Zamani
ICLS (Private Practice), Oakville, Canada

*Address all correspondence to: drkhanna@icls.ca

IntechOpen

© 2021 The Author(s). Licensee IntechOpen. This chapter is distributed under the terms of the Creative Commons Attribution License (<http://creativecommons.org/licenses/by/3.0>), which permits unrestricted use, distribution, and reproduction in any medium, provided the original work is properly cited. 

References

- [1] Aesthetic Plastic Surgery National Databank Statistics for 2019 [Internet]. 2019. Available from: https://www.surgery.org/sites/default/files/Aesthetic-Society_Stats2019Book_FINAL.pdf. [Accessed: 2021-03-21]
- [2] Miotto G, Ortiz-Pomalez Y. Arm contouring: Review and current concepts. *Aesthet Surg J*. 2018; 8(8):850-860. doi: 10.1093/asj/sjx218.
- [3] Hoyos F, Perez M. Arm dynamic definition by liposculpture and fat grafting. *Aesthet Surg J*. 2012;32(8):947-987. DOI: 10.1177/1090820X12461498
- [4] Hoyos F, Prendergast P. *High Definition Body Sculpting: Art and Advanced Lipoplasty Techniques*. New York: Springer; 2014. 244 p. DOI: 10.1007/978-3-642-54891-8
- [5] Garcia Jr O. Liposuction of the upper and lower extremities. In: Aly, A, Nahas, F, editors. *The Art of Body Contouring: A Comprehensive Approach*. New York: Thieme Medical Publishers, 2017. 614 p. ch14.
- [6] Theodorou S, Chia C, Wilson S. Radiofrequency-assisted liposuction for arm contouring. In: Theodorou S, Chia C, Dayan E, editors. *Emerging Technologies in Face and Body Contouring*. New York: Thieme Medical Publishers; 2020. 244 p. ch18.
- [7] Duscher D, Atashroo D, Maan ZN, Luan A, Brett EA, Barrera J, *et al*. Ultrasound-assisted liposuction does not compromise the regenerative potential of adipose-derived stem cells. *Stem Cells Transl Med*. 2016;5(2):248-57. DOI: 10.5966/sctm.2015-0064
- [8] Duscher D, Maan ZN, Luan A, Aitzetmüller MM, Brett EA, Atashroo D, *et al*. Ultrasound-assisted liposuction provides a source for functional adipose-derived stromal cells. *Cytotherapy*. 2017;19(12):1491-1500. DOI: 10.1016/j.jcyt.2017.07.013
- [9] Duncan DI. Improving outcomes in upper arm liposuction: adding radiofrequency-assisted liposuction to induce skin contraction. *Aesthet Surg J*. 2012; 32(1):84-95. DOI: 10.1177/1090820X11429549.
- [10] Nagy MW, Vanek PF. A multicenter, prospective, randomized, single-blind, controlled clinical trial comparing VASER-assisted lipoplasty and suction-assisted lipoplasty. *Plast Reconstr Surg*. 2012; 129(4), 681e-689e. doi:10.1097/prs.0b013e3182442274
- [11] Theodorou SJ, Del Vecchio D, Chia CT. Soft tissue contraction in body contouring with radiofrequency-assisted liposuction: A treatment gap solution. *Aesthet Surg J*. 2018;38(Suppl 2):S74-S83. DOI: 10.1093/asj/sjy037
- [12] Dayan E, Theodorou S, Rohrich RJ, Jay Burns A. Aesthetic applications of radiofrequency: Lymphatic and perfusion assessment. *Plast Reconstr Surg Glob Open*. 2020;8(10):e3193. DOI: 10.1097/GOX.0000000000003193
- [13] Paul M, Blugerman G, Kreindel M, Mulholland RS. Three-dimensional radiofrequency tissue tightening: a proposed mechanism and applications for body contouring. *Aesthetic Plast Surg*. 2011;35(1):87-95. DOI: 10.1007/s00266-010-9564-0
- [14] Duncan DI. Helium Plasma-Driven Radiofrequency in Body Contouring [Internet]. 2019. Available from: <https://www.intechopen.com/online-first/helium-plasma-driven-radiofrequency-in-body-contouring>. [Accessed: 2021-03-21]
- [15] Dayan E, Chia C, Burns AJ, Theodorou S. Adjustable depth fractional radiofrequency combined

with bipolar radiofrequency: A minimally invasive combination treatment for skin laxity, *Aesthet Surg J*. 2019;39 (Suppl 3):S112–S119. <https://doi.org/10.1093/asj/sjz055>

[16] el-Domyati M, el-Ammawi TS, Medhat W, et al. Radiofrequency facial rejuvenation: evidence-based effect. *J Am Acad Dermatol*. 2011;64(3):524-535. DOI: 10.1016/j.jaad.2010.06.045

[17] Han SH, Yoon YM, Lee YW, Choe YB, Ahn KJ. Usefulness of monopolar thermal radiofrequency treatment for periorbital wrinkles. *Ann Dermatol*. 2018;30(3):296-303. DOI:10.5021/ad.2018.30.3.296

[18] Seo KY, Yoon MS, Kim DH, Lee HJ. Skin rejuvenation by microneedle fractional radiofrequency treatment in Asian skin: Clinical and histological analysis. *Lasers in Surgery and Medicine*. 2012;44(8):631-636. DOI: 10.1002/lsm.22071

[19] Alexiades-Armenakas M, Rosenberg D, Renton B, Dover J, Arndt K. Blinded, randomized, quantitative grading comparison of minimally invasive, fractional radiofrequency and surgical face-lift to treat skin laxity. *Archives of Dermatology*. 2010;146(4). DOI: 10.1001/archdermatol.2010.24

[20] Teimourian B, Malekzadeh S. Rejuvenation of the upper arm. *Plast Reconstr Surg*. 1998;102(2):545-551; discussion 552. DOI: 10.1097/00006534-199808000-00041

[21] Appelt EA, Janis JE, Rohrich RJ. An algorithmic approach to upper arm contouring. *Plast Reconstr Surg*. 2006;118(1):237-246. DOI: 10.1097/01.prs.0000231933.05534.95

[22] El Khatib HA. Classification of brachial ptosis: strategy for treatment. *Plast Reconstr Surg*.

2007;119(4):1337-1342. DOI:10.1097/01.prs.0000254796.40226.92

[23] Rivers JK, Ulmer M, Vestvik B, Santos S. A customized approach for arm fat reduction using cryolipolysis. *Lasers in Surgery and Medicine*. 2018;50(7):732-737. DOI: 10.1002/lsm.22811

[24] Sykes JM, Allak A, Klink B. Future Applications of deoxycholic acid in body contouring. *J Drugs Dermatol*. 2017; 16(1):43-46.

[25] Egrari S. Brachioplasty. In: Nahai, F, Nahai, F, editors. *The Art of Aesthetic Surgery: Principles & Techniques*. 3rd ed. Volume 3. New York: Thieme Medical Publishers, 2020. 678 p. ch88.

[26] Brotzman EA, Sandoval LF, Crane J. Use of nitrous oxide in dermatology: A systematic review. *Dermatol Surg*. 2018;44(5):661-669. DOI:10.1097/DSS.0000000000001464

[27] Bird G, Albert C. Nitrous oxide as an adjunct in tumescent liposuction. *J Cosmet Dermatol*. 2005;4:267-71. DOI:10.1111/j.1473-2165.2005.00203.x

[28] Klein JA. Anesthesia for liposuction in dermatologic surgery. *J Dermatol Surg Oncol*. 1988;14:1124-32. DOI: 10.1111/j.1524-4725.1988.tb03469.x

[29] Jain K, Ghai B, Saxena AK, Saini D, Khandelwal N. Efficacy of two oral premedicants: midazolam or a low-dose combination of midazolam-ketamine for reducing stress during intravenous cannulation in children undergoing CT imaging. *Paediatr Anaesth*. 2010;20(4):330-7. DOI: 10.1111/j.1460-9592.2010.03279.x.

[30] Wall SH Jr, Lee MR. Separation, aspiration, and fat equalization: SAFE liposuction concepts for comprehensive body contouring. *Plast Reconstr Surg*. 2016;138(6):1192-1201. DOI: 10.1097/PRS.0000000000002808

[31] Capriotti K, Capriotti JA. Dimethyl sulfoxide: history, chemistry, and clinical utility in dermatology. *J Clin Aesthet Dermatol*. 2012;5(9):24-26.

[32] Kaoutzanis C, Gupta V, Winocour J, Layliev J, Ramirez R, Grotting JC, Higdon KK. Cosmetic liposuction: preoperative risk factors, major complication rates, and safety of combined procedures. *Aesthet Surg J*. 2017;37(6): 680-694. DOI: 10.1093/asj/sjw243

[33] Nguyen L, Gupta V, Afshari A, Shack RB, Grotting JC, Higdon KK. Incidence and risk factors of major complications in brachioplasty: Analysis of 2,294 patients. *Aesthet Surg J*. 2016;36(7):792-803. DOI: 10.1093/asj/sjv267

[34] Austin RE, Lista F, Khan A, Ahmad J. The Impact of protein nutritional supplementation for massive weight loss patients undergoing abdominoplasty. *Aesthet Surg J*. 2016;36(2): 204-210. DOI:10.1093/asj/sjv122

[35] Chia CT, Marte JA, Ulvila DD, Theodorou SJ. Second generation radiofrequency body contouring device: Safety and efficacy in 300 local anesthesia liposuction cases. *Plast Reconstr Surg Glob Open*. 2020;8(9):e3113. DOI:10.1097/GOX.0000000000003113

[36] Goldman A, Gotkin RH. Laser-assisted liposuction. *Clinics in Plastic Surgery*. 2009; 36(2), 241-253. DOI:10.1016/j.cps.2008.11.005

[37] Goldman A, de Mundstock E, Wollina U. Evaluation of tissue tightening by the subdermal Nd: Yag laser-assisted liposuction versus liposuction alone. *Journal of Cutaneous and Aesthetic Surgery*. 2011; 4(2),122. DOI:10.4103/0974-2077.85035

[38] Man D, Meyer H. Water jet-assisted lipoplasty. *Aesthet Surg J*. 2007; 27(3), 342-346. DOI:10.1016/j.asj.2007.04.008

[39] Shridharani SM, Broyles JM, Matarasso A. Liposuction devices: Technology update. *Med Devices (Auckl)*. 2014;7:241-251. DOI: 10.2147/MDER.S47322

- *The Renuvion® APR Handpiece is intended for the delivery of radiofrequency energy and/or helium plasma where coagulation/contraction of soft tissue is needed. Soft tissue includes subcutaneous tissue.*
- *The Renuvion APR Handpiece is intended for the coagulation of subcutaneous soft tissues following liposuction for aesthetic body contouring.*
- *The Renuvion APR Handpiece is indicated for use in subcutaneous dermatological and aesthetic procedures to improve the appearance of lax (loose) skin in the neck and submental region.*
- *The Renuvion APR Handpiece is intended for the delivery of radiofrequency energy and/or helium plasma for cutting, coagulation and ablation of soft tissue during open surgical procedures.*
- *The Renuvion APR Handpiece is intended to be used with compatible electrosurgical generators owned by Apyx Medical.*