

A retrospective chart review of subdermal neck coagulation using helium plasma technology

Vaishali Doolabh MD^{1,2}  | Paul Ruff MD^{1,2} 

¹Contemporary Plastic Surgery, Jacksonville, Florida, USA

²West End Plastic Surgery, Washington, District of Columbia, USA

Correspondence

Vaishali Doolabh, MD, Contemporary Plastic Surgery, 7035 Southpoint Pkwy South, Jacksonville, FL 32216, USA.
Email: vbdoolabh@gmail.com

Abstract

Background: A helium-based plasma technology has recently been cleared by the Food and Drug Administration for cutting, coagulation, and ablation of soft tissue (Renuvion® System; Apyx™ Medical Corporation). As the safety of helium plasma for treating lax and sagging skin in the neck area has not been previously reported, the objectives of this study were to obtain safety results from helium plasma used for neck rejuvenation, to summarize subject and procedure variables, and to assess treatment outcomes for the development of future treatment protocols.

Methods: Two retrospective chart reviews were performed using data from patients who had undergone a helium plasma procedure in the neck area to assess safety (Study 1) and effect (Study 2). For Study 2, pre- and posttreatment images of treatment areas were assessed by blinded reviewers.

Results: In Study 1 (N = 15), two adverse events felt to be treatment-related were noted. In Study 2 (N = 13), mean improvements included a 37.29% reduction in submental angle and reduction in the submental area.

Conclusions: Helium plasma technology appears to be a safe and well-tolerated treatment. Consistent and reproducible tissue contraction in the submental and neck area was observed between the authors' sites.

KEYWORDS

helium plasma, neck rejuvenation, radiofrequency, tissue contraction

1 | INTRODUCTION

Numerous heat-based technologies including microfocused ultrasound, laser, light, and radiofrequency are available for noninvasive and minimally invasive skin rejuvenation.^{1,2} The thermal effects of radiofrequency (RF) alternating current on tissue, when used in electrosurgery, have become well-established. Understanding the heat effects of RF energy enables predictable tissue changes that can be used to accomplish beneficial therapeutic results. Protein denaturation leading to soft tissue coagulation is one of the most versatile and widely used tissue effects.

During the process of denaturation, hydrothermal crosslinks between protein molecules, such as collagen, are instantaneously broken and then quickly reformed as tissue cools. This leads to the creation of uniform clumps of protein coagulum through the process of coagulation which results in predictable soft tissue contraction and stimulates long-term neocollagenesis and collagen remodeling.²

A helium-based plasma technology has recently been cleared by the Food and Drug Administration for cutting, coagulation, and ablation of soft tissue (Renuvion® System; Apyx™ Medical Corporation). The Apyx™ Plasma/RF system consists of a



FIGURE 1 Apyx™ Plasma/Radiofrequency handpiece

handpiece (Figure 1), an electrosurgical unit (Figure 2), and a supply of helium gas (Figure 2). The device handpiece delivers RF energy percutaneously in a controlled fashion that results in soft tissue coagulation and contraction within the fibro-septal network. The system consists of an electrosurgical generator unit, a handpiece, and a supply of helium gas. RF energy is delivered to the handpiece by the generator to energize an electrode.³ When helium gas passes over the energized electrode, a stream of helium plasma is generated which allows heat to be applied to tissue in two different and distinct ways. First, the heat generated by the plasma beam itself through ionization and rapid neutralization of helium atoms. As plasma is a very good conductor of electricity, a portion of the RF energy used to energize the electrode is also transferred to the tissue where heat is created due to electrical resistance by a process known as Joule heating.⁴ These two novel heat sources make the helium plasma device a useful surgical tool for heating, coagulating, and contracting soft tissue.^{5,6} This is achieved by the almost instant heating of soft tissue to over 85°C for 0.040 to 0.080 s.⁵ As a result, there is a less unwanted

transfer of heat to adjacent tissue compared with other heat-based devices. In a preclinical study, surface skin temperature reached a maximum of 41°C, an increase of less than 4°C.⁵

Advantages of helium plasma include^{3,7}:

- Unfettered power delivery regardless of tissue impedance due to the unique power output from the electrosurgical generator
- Focused delivery of energy immediately heats the fibro-septal network of the dermis resulting in immediate soft tissue contraction without heating the full thickness of the dermis
- Low-current RF energy causes the minimal depth of thermal effect and prevents overtreating tissue when performing multiple passes

As the safety of helium plasma for treating lax and sagging skin in the neck area has not been previously documented by clinical studies, two retrospective chart reviews were performed using data from patients who had undergone procedures in the neck area using a helium plasma procedure. The primary objective was to obtain information on the safety and treatment data




FIGURE 2 Electrosurgical unit and helium tank

from helium plasma used for neck rejuvenation. Secondary objectives were to summarize subject and procedure variables and assess treatment effects. This will provide some necessary parameters to conduct a formal, prospective, larger randomized clinical trial of the use of helium plasma alone or with concomitant facial procedures.

2 | METHODS

Paper or electronic medical records at the investigational sites were reviewed. Eligible participants were adult male and female subjects who had undergone a helium plasma neck procedure. All patients that underwent subdermal coagulation in the neck from the time period from December 2017 to August 2018 were considered eligible for analysis. The group of eligible patients represented a broad spectrum of patients seeking the esthetic face and body improvements, included both men and women over the age of 21, with body mass index (BMI) ranging from normal to obese. Table 1 lists each patient, their BMI, concomitant procedures. None of the patients had other concomitant procedures to the neck. Specifically, fat grafting was done to the body, resurfacing and peels stopped above the jawline, no permanent sutures were placed within the SMAS/platysma, and VASER probes similar in diameter to the helium plasma handpiece were used for pre-tunneling only without activation of the ultrasound component nor heat generation. Neck deformities seen in the patients were considered for treatment based upon the surgeon's judgment of skin laxity. Patients considered candidates for the use of helium plasma technology were those with notable skin laxity to the

extent that tumescent liposuction of any preplatysmal fat would not provide the optimal definition. Anatomical considerations of the amount of preplatysmal fat, absence or presence of platysmal banding, and adequacy of the skeletal frame were not determining factors in whether to utilize helium plasma technology. As these were retrospective chart reviews, there was no direct contact with study subjects. For each case, reports of adverse events and procedural complications were recorded. Additional variables included patient characteristics and comorbidities, procedural details and concomitant procedures, device settings, and treatment outcomes when available. For both studies, a waiver of Informed Consent and HIPAA Authorization was received from a commercial institutional review board (Sterling IRB, Atlanta, GA, USA).

For Study 1, descriptive statistics were performed on the deidentified information obtained. For Study 2, pre- and post-treatment images of treatment areas were obtained and compared by blinded physician reviewers who performed a randomized, qualitative analysis of each set of images to identify posttreatment images. As the blinded physician reviewers represented six plastic, oculoplastic, and dermatologic surgeons with the most experience with this novel technology, in terms of the number of patients treated and years of device usage, they were selected for qualitative and subjective evaluation of before and after photographs. Analyzed photographs were focused strictly on the neck area for the presence or absence of cervical skin tightening. Each blinded reviewer was given one training image to confirm the adequacy of their analysis. No inter-rater agreement analysis was used. Each blinded reviewer then randomly assessed the patient images that were provided in triplicate, ensuring that each member served as

TABLE 1 Concomitant procedures

Subject number	Body mass index	Concomitant procedures
01	24.27	None
02	20.50	Structural fat grafting, Renuvion dermal resurfacing, abdominal liposuction
03	21.92	Bilateral breast implant, structural fat grafting, Jessner's/trichloroacetic acid peel, electrofulguration multiple superficial keratoses
04	24.21	Subdermal Renuvion to breasts, liposuction to stomach and inner thigh
05	22.5	None
06	19.37	Breast implant, liposuction to arms and anterior thigh
07	24.89	Structural fat grafting, liposuction to arms, stomach, hips or love handles, scapular rolls, inner and outer thighs
08	23.17	Blepharoplasty, Renuvion dermal resurfacing
09	19.84	Renuvion dermal resurfacing, blepharoplasty
10	25.74	J-Platzy sutures, Renuvion dermal resurfacing, nasal tip lesion excision, face lift, chin implant
11	24.23	J-Platzy sutures, liposuction to stomach, hips or love handles, scapular rolls, and posterior shoulders
12	19.47	J-Platzy sutures, Renuvion dermal resurfacing
13	19.37	J-Platzy sutures, Renuvion dermal resurfacing, fractional CO ₂ laser

TABLE 2 Helium plasma settings for each subject

Power (%)	Helium flow (LPM)	Passes (n)
60	2	5
60	2	6
60	4	6
65	1.5	3
70	1.5	3
70	1.5	5-6
70	2	4
70	2	6
80	2	6
80	3	2-3
80	3	4-5
80	3	4-6
80	4	3

their own control when analyzing the 13 patients' images. The percentage of subjects with correct posttreatment image selection was used to validate the effect of tissue coagulation in the neck and submental regions. To be eligible for analysis, images were required to meet the review eligibility criteria for image consistency as established by the blinded physician reviewers, including similar subject positioning and lighting, original JPEG format (no altered images) of procedures performed on the neck. Images meeting these criteria were also independently assessed for visually apparent changes and changes in neck angle and area of skin laxity. Proprietary image analysis software developed by MS Clinical Research (P) Ltd. was utilized to measure the percent reduction in the cervicomental angle using the outer canthus, the most forward point of the nasal cavity, and the point where the chin meets the neck as anatomical landmarks. The treatment area confined within these landmarks was quantified in pixels and subsequent percent "reduction" in the area was quantified. Neck angle and neck area measurements were individually calculated for each baseline and follow-up image. The change between baseline and follow-up calculations was then determined and noted as percentage of change. Subjects with eligible pre- and posttreatment images provided permission to publish them.

3 | RESULTS

The Study 1 chart review identified 15 subjects who were female ($n = 14$; 93.3%) and male ($n = 1$; 6.7%), 48-76-years old with a mean body mass index of 22 kg/m^2 (range, $17-26 \text{ kg/m}^2$). No liposuction was performed in combination with the helium plasma treatment of the neck. The mean posttreatment follow-up was 4 months (range: 1 day to 15 months).

Two adverse events were noted in the charts without accompanying photos among the plasma-treated subjects. One subject, who was enrolled in both Study 1 and Study 2, experienced a procedural complication consisting of a simple, partial-thickness 0.6 cm^3 area of epidermal lysis in the region of the submental neck crease. The surgeon chose regenerative medicine treatment with the intent of expediting healing. The area was immediately treated with cool gauze, 0.5 ml of activated platelet-rich plasma and liquified amnion, and covered with an occlusive dressing (Xeroform® Occlusive Dressing; Covidien/Medtronic). The event was determined to be related to the helium plasma procedure and resolved without further treatment. The other reported adverse event was a temporary weakened right-sided depression of the lower lip. The next day, out of an abundance of caution, the perilobular incisions were opened, and the jawline area explored. The differential included neuropraxia of branches of the marginal mandibular nerve and/or injury to the platysma muscle itself. The event was determined to be treatment-related and resolution-consistent with neuropraxia was achieved, with full symmetry at rest and animation after 5 weeks without further intervention.

In Study 2, the same pool of safety patients was analyzed for effect. One out of town patient was lost to follow-up after postoperative day 1. Another patient was not felt to have standardized photographs that met the criteria for analysis. Hence, there were two fewer eligible patient photographs for measurements than available for safety and procedural data collation in Study 1. The eligible subjects ($N = 13$) were all female, 42-76-years old with a mean BMI of 22 kg/m^2 (range, $19-26 \text{ kg/m}^2$) and followed for a mean of 4 months (range, 1 day-7 months) postprocedure. As a retrospective study-combing data from multiple sites, there was no predetermined, agreed-upon duration of follow-up. The follow-up period of 4 months was the mean, and provides an early assessment of the improvement seen with helium plasma subdermal coagulation. More specifically, subjects were followed for 1 month (23%) or lesser, 2-5 months (46%), and 6-7 months (31%). For all subjects, a 1% lidocaine with 1:1,000,000 epinephrine was used. Undermining was performed using equal caliper probes and cannulas. No liposuction was performed on the neck; however, all subjects underwent concomitant procedures with most having liposuction on another body area ($n = 5$) and dermal resurfacing ($n = 6$; Table 1). Tumescence fluid volumes were not quantified separately between the neck and body in the charts.

The mean generator settings were 70% power (range, 60%-85%) and 2 (range, 1.5-4) LPM helium with a mean of five passes (range, 3-6; Table 2). The only adverse event reported in this study was previously described in the results of Study 1.

All subject image sets met the image review criteria. Shadowing in the images did not impact the identification of skin borders that was used to calculate differences in the angle of measurement or area reduced in the submentum. The six medical advisory board (MAB) members correctly identified 80% of pre- and posttreatment images (range, 69%-87%; Table 3) and all subject images (100%)

TABLE 3 Medical advisory board member image review results

Reviewer	Overall success (%)
1	87
2	87
3	79
4	82
5	77
6	69

were determined by the Independent Photographic Reviewers to demonstrate tissue contraction visible in photographs following a single treatment.

As a Shapiro–Wilk test determined neck angle data were not normally distributed, a nonparametric Wilcoxon test was performed to determine the difference in neck angle at pre- and posttreatment time points. The mean (SD) angle decreased from 27.2° (8.7°) to 17.1° (7.6°), a mean percent reduction of 37.29% ($p = .0002$; range, 18.32%–68.64%; Table 4). As the data were normally distributed, a parametric t test was used to determine the difference between the pre- and posttreatment area of skin laxity. The mean area from jawline to under the chin decreased from 26,820.3 (9171.9) pixels to 19,081 (10,193.1) pixels, a mean reduction in submental neck area of 35.44% ($p < .0001$; range, 11.64%–67.81%; Table 5). Pre- and post-treatment images with neck angle and submental area analyses are shown in Figures 3–6.

To demonstrate angles and area measured, the following notable individual results are detailed. One subject (Figure 3) at 7 months with a 51.14% reduction in submental angle and 67.81% reduction in

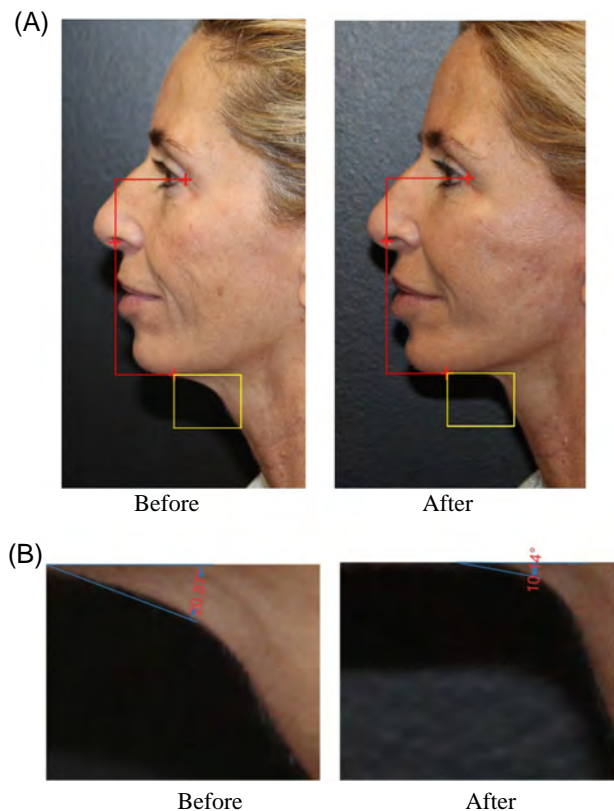
TABLE 4 Quantitative analysis 1: Angle across jawline to under the chin

Subject	Pretreatment angle (°)	Posttreatment angle (°)	% angle reduction
1	26.79	17.91	33.25
2	29.91	24.43	18.3
3	20.87	10.14	51.1
4	31.90	17.42	45.4
5	15.28	11.45	25.1
6	18.29	14.41	21.2
7	33.96	10.65	68.6
8	32.14	24.44	24.0
9	16.22	9.67	40.4
10	41.21	25.71	37.6
11	22.85	11.76	48.5
12	41.14	33.17	19.4
13	23.36	11.21	52.0

TABLE 5 Quantitative analysis 2: The area across jawline to under chin

Subject	Pretreatment area (pixels)	Posttreatment area (pixels)	% area reduction
1	39,434	32,767	16.9
2	43,737	38,646	11.6
3	19,954	6423	67.8
4	21,188	13,004	38.6
5	22,983	17,279	16.9
6	21,013	17,523	16.6
7	43,827	34,798	41.1
8	26,061	22,095	41.3
9	25,373	16,389	33.3
10	20,763	12,203	67.7
11	17,814	8965	30.9
12	24,210	16,082	48.0
13	22,307	11,879	29.9

area; Renuvion procedure was 80% power, 3 LPM, three passes. One subject (Figure 4) at 12 months with a 45.39% reduction in submental angle and 38.63% reduction in area; Renuvion procedure was 85% power, 3 LPM, three passes. One subject (Figure 5) at 1 month

**FIGURE 3** (A) 67.81% reduction in area at 7 months. (B) 51.14% reduction in angle at 7 months

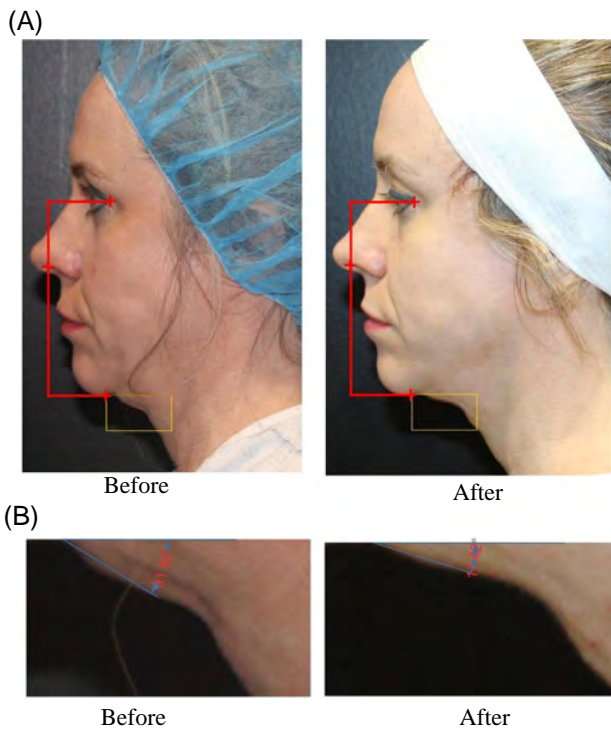


FIGURE 4 (A) 38.63% reduction in area at 12 months. (B) 45.39% reduction in angle at 12 months

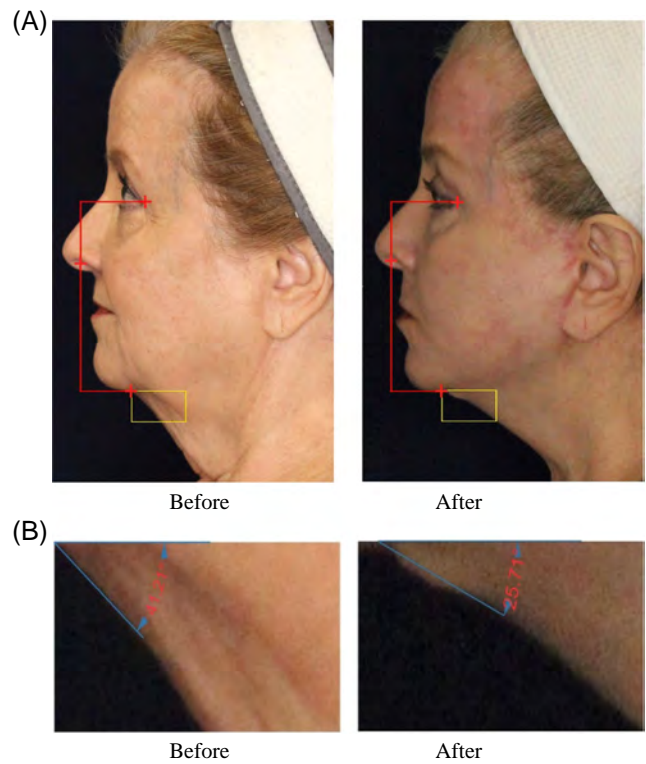


FIGURE 6 (A) 67.67% reduction in area at 3 months. (B) 37.61% reduction in angle at 3 months

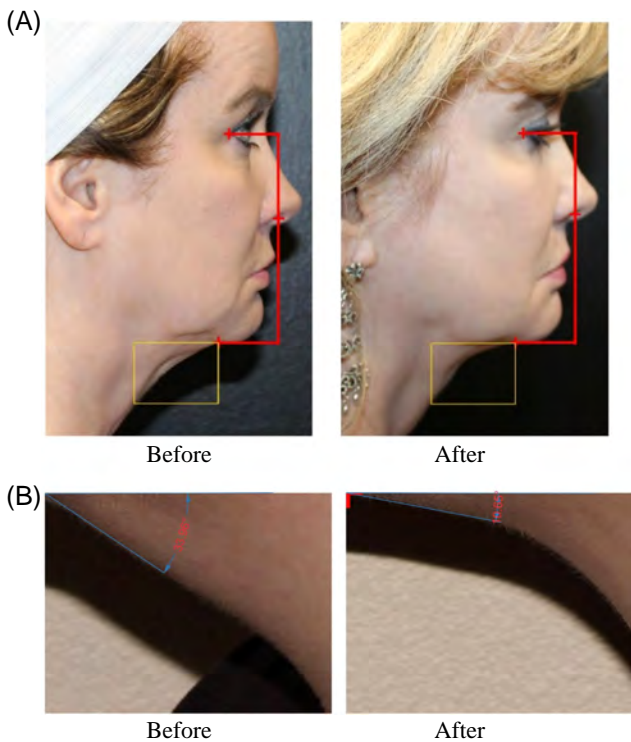


FIGURE 5 (A) 41.08% reduction in area at 1 month. (B) 68.64% reduction in angle at 1 month

with a 68.64% reduction in submental angle and 41.08% reduction in area; Renuvion procedure was 65% power, 1.5 LPM, four passes. One subject (Figure 6) at 3 months with a 37.61% reduction in submental angle and 67.67% reduction in area; Renuvion procedure was 60% power, 4 LPM, four passes.

4 | DISCUSSION

The outward signs of aging can be very evident in the neck. Changes affecting the appearance of the neck can include an increase or decrease of subcutaneous fat, platysmal banding, jowling, and skin laxity. Depending on the severity, a range of treatment options is available for use alone or in combination for treating the aging neck.⁸ As an ongoing series of retrospective analyses, the authors are demonstrating the adequacy of measured variables, methodologic omissions, and data abstraction methods in an attempt to establish clinical protocols for widespread adoption and clarify the safety and effect of this radio-frequency powered helium plasma technology. We have previously published a retrospective chart review in which helium plasma technology was safely used for skin contraction with and without concomitant tumescent liposuction and had a limited side effect protocol.⁹ Subsequently, looking across multiple investigator sites, we were able to present similar findings of few device-related adverse events occurring in patients treated intraoperatively with the same helium plasma subdermal coagulation technology immediately following

liposuction across a broad range of anatomical areas.¹⁰ Acknowledging the significant clinical challenge presented by cervical rejuvenation, this study focused on the safety and treatment complications from neck tissue contraction by Renuvion. We acknowledge the multiple deficiencies inherent in retrospective chart reviews, and anticipate that additional future studies will be undertaken to further quantify the effects of helium plasma independent of rater agreement, provide histology, patient satisfaction data, fully standardized photographs, collection of additional relevant parameters such as the depth of passes, and include longer consistent follow-up to help delineate the longevity of effect. We believe this review nonetheless provides clinically relevant data and will guide the development and applications of this unique technology.

Two adverse events were documented among the plasma-treated subjects in this study. There were no occurrences of hematoma, seroma, infection, necrosis, contour irregularity, or other complications. The overall rate of adverse events was 7.4% which compares favorably with other procedures for neck rejuvenation.^{11,12} Among subjects treated with percutaneous radiofrequency treating skin laxity under the chin and neck, common adverse events were hypoesthesia (30.56%), edema (22.22%), and swelling (11.11%) at the application site.¹³

A secondary objective of these studies was to determine the effectiveness of the helium plasma procedure for tissue contraction in the neck area. Most outcome measures in cosmetic surgery, are entirely subjective by the subject, investigator, and/or blinded independent assessor. Quantitative assessments allow for results of procedures to be evaluated in an objective fashion. In recent years, there has been a push to provide more quantitative data to support clinical findings. In Study 2, images were analyzed both subjectively and quantitatively to determine consistency in the results and to determine if the quantitative measurements were sensitive enough to calculate changes. Subjectively, blinded reviewers found all subjects before/after images to be visually different and the MAB members were able to correctly identify the correct before/after image 80% of the time. Quantitatively, measurements of submental angle and area from digital subject images revealed significant reductions of submental angle and area for all patients. These quantitative results suggest this method of measuring tissue contraction resulting from a treatment with helium plasma technology will be effective in future studies and that there is good consistency between subjective and quantitative assessments.

Although limited by small sample size and retrospective study design, the results of the present studies indicate helium plasma technology provides a safe and well-tolerated method for rejuvenating the appearance of an aging neck.

5 | CONCLUSION

Two retrospective reviews of 15 and 13 patients who underwent a neck procedure with a device based on helium plasma technology revealed a low incidence of mild adverse events after a mean follow-up of 4 months. Helium plasma technology appears

to be a safe and well-tolerated treatment for lax tissue in the neck with skin contraction changes visually apparent by subjective and quantitative analyses of before and after photographs.

ACKNOWLEDGMENT

This study was sponsored by Apyx™ Medical Corporation, Clearwater, FL

CONFLICT OF INTERESTS

No blinded physician reviewer received direct financial compensation for their participation. Each blinded physician reviewer is a member of the MAB, a consultant for Apyx™ Medical Corporation, and has stock options in Apyx™ Medical Corporation. Vaishali Doolabh, MD was an investigator on this study and is a paid Consultant for Apyx™ Medical Corporation.

ETHICS STATEMENT

All patients in this study consented to photographs and the use of those photographs in educational content and scientific journals.

ORCID

Vaishali Doolabh  <http://orcid.org/0000-0002-9190-9484>

Paul Ruff  <http://orcid.org/0000-0003-3882-0787>

REFERENCES

- Dierickx CC. The role of deep heating for noninvasive skin rejuvenation. *Lasers Surg Med*. 2006;38:799-807.
- Woolery-Lloyd H, Kammer JN. Skin tightening. *Curr Probl Dermatol*. 2011;42:147-152.
- Renuvion® Cosmetic Technology. <https://www.renuvion.com/>. Accessed October 29, 2019.
- Habermann W, Müller W. Tissue penetration of bipolar electro-surgical currents: Joule overheating beyond the surface layer. *Head Neck*. 2013;35:535-540.
- Gentile RD. Renuvion/J-Plasma for subdermal skin tightening facial contouring and skin rejuvenation of the face and neck. *Facial Plast Surg Clin North Am*. 2019;27:273-290.
- Masghati S, Pedroso J, Gutierrez M, Stockwell E, Volker KW, Howard DL. Comparative thermal effects of J-Plasma®, monopolar, argon, and laser electrosurgery in a porcine tissue model. *Surg Technol Int*. 2019;34:35-39.
- Pedroso JD, Gutierrez MM, Volker KW, Howard DL. Thermal effect of J-Plasma® energy in a porcine tissue model: implications for minimally invasive surgery. *Surg Technol Int*. 2017;30:19-24.
- Dibernardo BE. The aging neck: a diagnostic approach to surgical and nonsurgical options. *J Cosmet Laser Ther*. 2013;15:56-64.
- Doolabh V. A single-site postmarket retrospective chart review of subdermal coagulation procedures with Renuvion. *PRS Global Open*. 2019;7:e2502.
- Doolabh VB, Ruff PG, Gentile RD. A post-market retrospective chart review of subdermal coagulation procedures with a helium-based plasma device—Poster presented at: American Academy of Cosmetic Surgery; February 27, 2020; Las Vegas, NV (AACS 2020 Global Conference).
- Newman J, Chan J, Lorenc ZP, Stridde BC, Russell DJ. Multicenter efficacy trial of a percutaneous radiofrequency system for the reduction of glabellar lines. *Aesthet Surg J*. 2019.
- Serdar ZA, Tatlıparmak A. Comparison of efficacy and safety of fractional radiofrequency and fractional Er:YAG laser in facial and

neck wrinkles: six-year experience with 333 patients. *Dermatol Ther.* 2019;32:e13054.

13. National Institutes of Health. Safety and effectiveness evaluation of the device in achieving submental lift. [ClinicalTrials.gov](https://clinicaltrials.gov) Identifier: NCT02832674. <https://clinicaltrials.gov/ct2/show/NCT02832674>. Accessed February 4, 2020.

How to cite this article: Doolabh V, Ruff P. A Retrospective Chart Review of Subdermal Neck Coagulation Using Helium Plasma Technology. *Dermatological Reviews.* 2020;1-8. <https://doi.org/10.1002/der2.32>

- *The Renuvion® APR Handpiece is intended for the delivery of radiofrequency energy and/or helium plasma where coagulation/contraction of soft tissue is needed. Soft tissue includes subcutaneous tissue.*
- *The Renuvion APR Handpiece is intended for the coagulation of subcutaneous soft tissues following liposuction for aesthetic body contouring.*
- *The Renuvion APR Handpiece is indicated for use in subcutaneous dermatological and aesthetic procedures to improve the appearance of lax (loose) skin in the neck and submental region.*
- *The Renuvion APR Handpiece is intended for the delivery of radiofrequency energy and/or helium plasma for cutting, coagulation and ablation of soft tissue during open surgical procedures.*
- *The Renuvion APR Handpiece is intended to be used with compatible electro-surgical generators owned by Apyx Medical.*