

PUBLICATION INFORMATION

Thomas, M., D'silva, J., & Abraham, A. (2021). Use of Technologies to Improve the Liposuction Outcome Including Skin Texture and Form. In (Ed.), Enhanced Liposuction - New Perspectives and Techniques. IntechOpen. <https://doi.org/10.5772/intechopen.99947>

FINANCIAL & CONTENT DISCLOSURE: This literature was funded in part by Apyx Medical. The opinions contained herein are those of the authors(s) and do not necessarily represent the official position or policies of Apyx Medical, Inc.

MANUFACTURING DISCLOSURE: Apyx Medical manufactures and owns the Renuvion/J-Plasma technology discussed in this article.

INDICATIONS FOR USE & INTENDED USE DISCLOSURES

- The Renuvion® APR Handpiece is intended for the delivery of radiofrequency energy and/or helium plasma for cutting, coagulation, and ablation of soft tissue during open surgical procedures.
- The Renuvion® APR Handpiece is indicated for use in subcutaneous dermatological and aesthetic procedures to improve the appearance of lax (loose) skin in the neck and submental region.
- The Renuvion® APR Handpiece is intended to be used with compatible electrosurgical generators owned by Apyx Medical (specifically BVX-200H, BVX-200P, APYX-200H, APYX-200P, APYX-RS3, and APYX-JS3).
- Apyx Medical wants to present you with current scientific discourse. Specific usage outside of the cleared indications may not be safe or effective.
- The use of Renuvion with liposuction has not been approved or cleared by the FDA.

RISKS:

- As with all energy devices there are inherent risks associated with its use. Risk associated with the use of the Renuvion APR may include: helium embolism into the surgical site due to inadvertent introduction into the venous or arterial blood supply system, unintended burns (deep or superficial), pneumothorax, temporary or permanent nerve injury, ischemia, fibrosis, infection, pain, discomfort, gas buildup resulting in temporary and transient crepitus or pain, bleeding, hematoma, seroma, subcutaneous induration, pigmentation changes, increased healing time, scarring, asymmetry and/or unacceptable cosmetic result.

As with any procedure, individual results may vary. As with all energy devices there are inherent risks associated with its use, refer to the IFU for further information.

We are IntechOpen, the world's leading publisher of Open Access books Built by scientists, for scientists

5,700

Open access books available

141,000

International authors and editors

180M

Downloads

Our authors are among the

154

Countries delivered to

TOP 1%

most cited scientists

12.2%

Contributors from top 500 universities



WEB OF SCIENCE™

Selection of our books indexed in the Book Citation Index
in Web of Science™ Core Collection (BKCI)

Interested in publishing with us?
Contact book.department@intechopen.com

Numbers displayed above are based on latest data collected.
For more information visit www.intechopen.com



Use of Technologies to Improve the Liposuction Outcome Including Skin Texture and Form

Mohan Thomas, James D'silva and Amal Abraham

Abstract

Liposuction as the word suggests involves sucking out fat from the subcutaneous layers. In many parts of the world it is used interchangeably with weight loss and non-surgical fat reduction procedures. The gold standard for liposuction for many decades has been the "Suction assisted Liposuction" also called SAL. Newer technologies have been introduced with varied claims about skin retraction, painless and complete evacuation of fat as well as a faster recovery. This chapter elaborates the personal experience of the Authors with regards to the discussed newer technologies bringing into perspective their indications, mechanism of action as well as clinical outcomes. At the outset the Authors would like to state emphatically that technologies are as good as the surgeon holding them and that somewhat same result can be achieved through a traditional liposuction in most of the cases. A surgeon looking to incorporate these technologies in practice should first achieve a mastery of traditional SAL for the best outcomes.

Keywords: Liposuction, Ultrasound assisted Liposuction, Waterjet assisted Liposuction, Power assisted Liposuction, Radiofrequency assisted Liposuction, Laser assisted liposuction, J-Plasma assisted liposuction, VASER liposuction

1. Introduction

The first and most important thing to know is that not all patients are candidates for liposuction as it is not a weight loss procedure rather is only for body contouring. The satisfaction of a good outcome for both the patient and the operating surgeon would come from selecting the right patient. Liposuction is most effective for treating localized adipose deposits, particularly combined with a targeted weight loss and lifestyle changes. The gender-specific distribution of typical subcutaneous adipose accumulation that are eminently amenable for removal through small incisions allowing the entry of small cannulae connected to constant suction have been taught to us through experience. One of the most groundbreaking medical developments of our time is liposuction.

The suction-based removal of excess fat – which is the most basic requirement of liposuction – is the simple part. The creative part includes determining how much fat to remove for an overall contouring, how much to leave behind for a smooth coverage, and how retractile the skin is.

We classify patients based on their BMI, and if the BMI is greater than 33, we recommend bariatric surgery, which is a SLEEVE GASTRECTOMY generally depending on assessment by the Bariatric Surgeon. Liposuction and skin removal may still be required in such cases to achieve the ideal shape for the person once the weight has been stable for more than a year.

At first glance, liposuction may be considered to be one of the simplest treatments especially for someone seeking to be a cosmetic surgeon however it requires an artistic skill and experience.

2. History

Liposuction has its origin as a procedure involving subcutaneous scissor dissection with curettage and debris suctioning in the second step.

Modern fat extraction began approximately 40 years ago, initially as a closed technique, when the German physician Schrüdde [1] first published his technique (called lipexeresis) using a uterine curette to remove subcutaneous fat. Several other surgeons, including Kesselring and Meyer, used this technique in the mid-1970s, and combined this with aspiration to remove more fat. Further stages of development included the intriguingly named 'cellulosuctiontome' [2] and 'aspiradepts' [3] that defined the second generation where sharp dissection and suction were combined as a single stage.

The prime originator of contemporary liposuction is Illouz [4], from France who ushered in the third generation by innovating a blunt-tipped cannula and the use of wetting solution to aspirate a lipoma from a patient's back. The latter aided aspiration and for the first time a procedure with acceptable morbidity and reproducibility was available to address fat deposits. Visiting Americans embraced liposuction with such a vigor and it was an US dermatologist Jeffery Klien [5] who first introduced the tumescent technique. Such direct infiltration of tumescent fluid produced regional anesthesia of both the skin and subcutaneous tissue allowing avoidance of general anesthesia and its use as ambulatory day care procedure thus could be done by Non-surgeons and/or those not having formal admitting rights to hospitals. Moreover, the combination of dilution and active removal as part of the lipoaspirate allowed higher doses of lignocaine to be used, but a safety limit of 35 mg/kg was proposed to limit toxicity [5, 6]. A firm structure for protection (especially for intra-abdominal viscera in those with abdominal laxity) and a more controlled harvest to reduce post-operative contour irregularities are two other advantages of the tumescent technique. Suction-assisted liposuction (SAL) is the general term for this method, and it is the gold standard by which all others are evaluated.

The fourth generation are the use of novel lipolysis technologies, the first of which was ultrasound-assisted liposuction (UAL) [7]. With less physical effort put into the aspiration and sound energy breaking down the adipocytes, more attention could be placed on the end product, a term known as "liposculpture." Unexpected cutaneous burns from the extra energy transmitted to the tissues specially the skin dampened the excitement, but the idea of 'assistance' was born nevertheless. This is well discussed in **Figure 1**.

Laser-assisted liposuction (LAL or Smart lipo) [8], power-assisted liposuction (PAL such as from MicroAire) [9], and, most recently, radiofrequency-assisted liposuction (RFAL) [10] are some of the other choices available for the Liposuction surgeon.

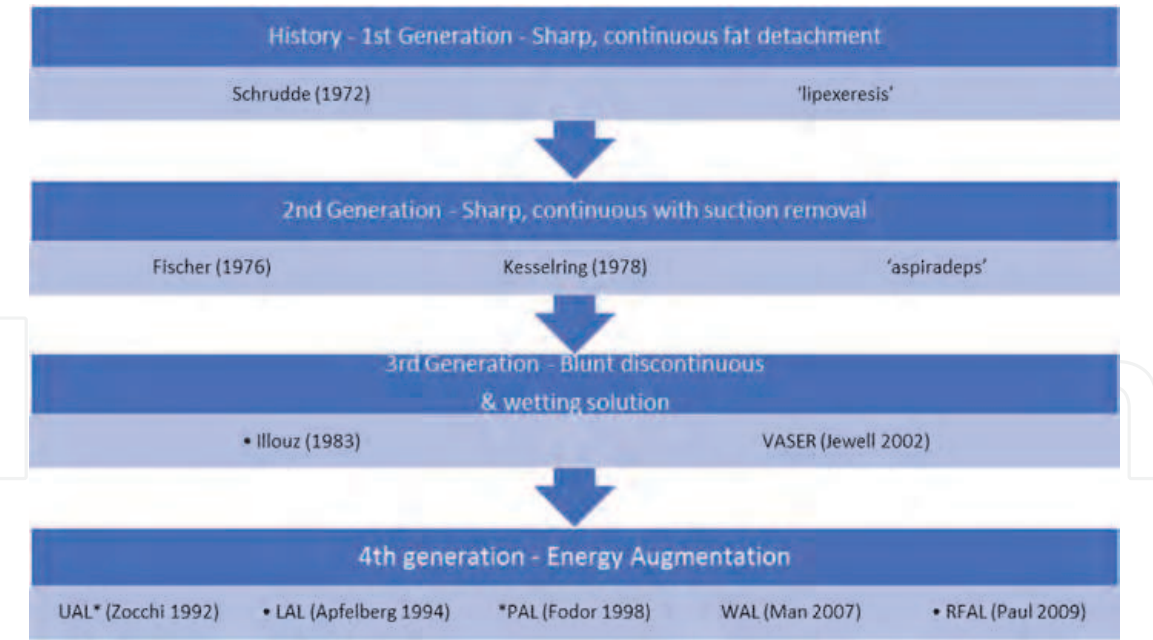


Figure 1.
The development of liposuction and the use of modern technologies for ease of fat removal.

3. Material and methods

The Authors have used the below mentioned technologies over the last 15 years and hence this section is dedicated to a discussion about individual technologies, their indications with respect to body contouring, method of undertaking the procedure, long term results of some patients who have undergone the procedures along with the complications that may be associated with the procedure.

3.1 Ultra sound assisted liposuction

Zocchi [7] is credited with the first person to use ultrasonic energy to more specifically target adipose tissue. The prototype UAL was a two-stage process that involved first breaking or lysing the fat followed by its suction. It began with use of 4–6 mm solid titanium probes which in contrast to steel, was better to harness the heat released by converting acoustic to mechanical energy. Electric energy is converted into mechanical energy using piezoelectric or quartz crystals, which is then transmitted and magnified by the probe as high-frequency (in excess of 16 kHz) acoustic energy inaudible to the human ear. The sound wave has alternating expansion and compression sections which produces negative pressure and induces an interstitial cavity, hence the term cavitation (**Figure 2**).

These microbubbles ultimately implode, resulting in cellular fragmentation and intracellular material release [7, 11]. The selectivity and tissue specificity of UAL are based on the assumption that this happens most rapidly with adipose tissue. Since this method generates a lot of heat, there should be plenty of wetting solution to aid dispersion and limit any negative thermal effects. The technological end point varies from SAL in that it is not simply the traditional ‘pinch test,’ but lack of resistance to probe progression that suggests adipocyte liquefaction and the ‘end point’. Lipoaspirate is also homogeneous and macroscopically acellular, with a slightly higher level of the intracellular glycerol 3-phosphate dehydrogenase isozyme unique to adipocytes [12].

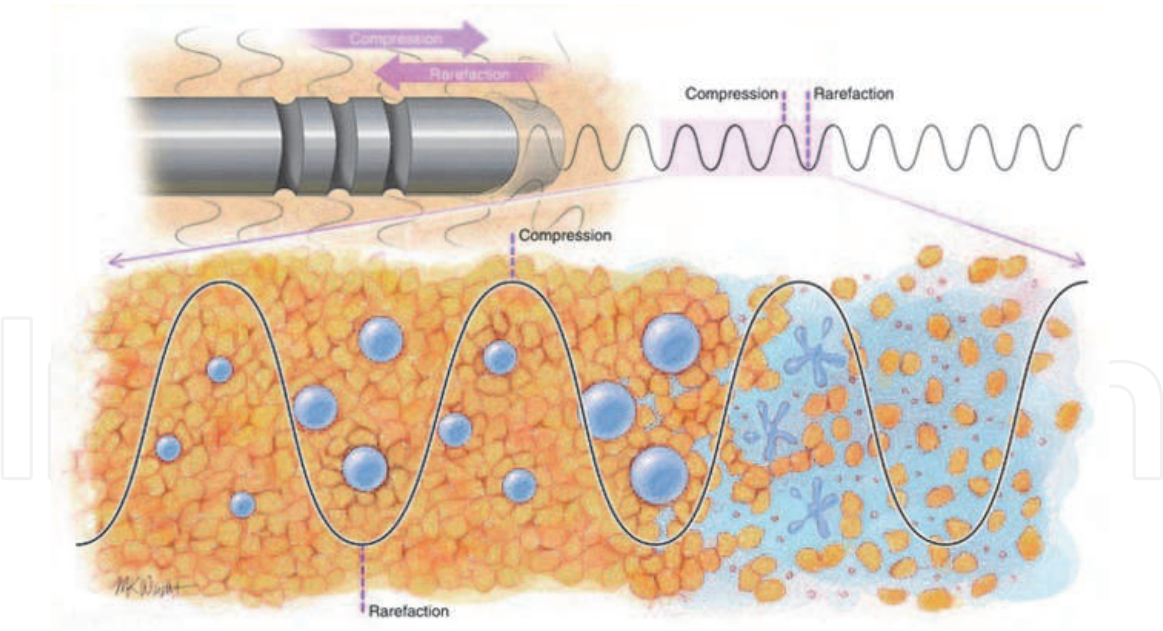


Figure 2.
The compression and rarefaction of the ultrasound waves causing breakage of the fat cells.

American doctors accepted UAL leading to the creation of second-generation UAL devices with hollow cannulae for simultaneous aspiration [13]. Unfortunately, the wetting solution’s simultaneous cooling effect is lost which led to the appearance of third-generation machines.

The VASER® (Vibration Amplification of Sound Energy at Resonance, Sound Surgical Technologies, Louisville, CO, USA) device [14] is one of the most commonly used. It comes in two models (**Figure 3**).



Figure 3.
VASER machine with its probes and other accessories.

The first uses pulsed energy rather than continuous energy, and the second uses concentric rings near the narrower (2.9–3.7 mm) probe tip to maximize performance. At lower and safer energy environments, substantially greater fragmentation efficiency can be achieved [15].

The VASER system uses a method for pretreating fatty tissue with ultrasonic energy, which induces fragmentation/emulsification by three biologic effects, similar to the previous devices.

1. The damage caused directly by the unidirectional action of ultrasonic waves in intracellular organic molecules is known as the micromechanical effect. This is a minor effect.
2. Thermal effect, which is a byproduct of the cannulas passing through the fat and the surrounding tissues' causes conversion of ultrasonic waves into heat energy.
3. Microcavitation effect, which involves gaps between cellular membrane molecules.

When ultrasonic waves reach their higher amplitude plateau, they cause expansion and when the ultrasonic waves reach their lower amplitude plateau it is followed by passive contraction of the gaps, resulting in a cycle of active expansion and passive contraction. The frequency at which the cycles occur, however, prevents the contraction process from being completed before the expansion cycle starts again. As a result, the gaps grow wider until they exceed 120 metres and implode, rupturing the cellular membrane and releasing the lipid content into the extracellular environment [16–18].

Tiny diameter titanium solid probes (2.9 and 3.7 mm) with grooves near the tip are used in the VASER method to improve fragmentation efficiency (**Figure 3**). The grooves close to the tip redistribute ultrasound energy and move some vibration from the tip to a region proximal to the tip. Less energy is thus needed to achieve the desired fatty tissue fragmentation due to the improved efficiency. As compared to the continuous mode, the probe design will result in a nearly 50% reduction in applied power with improved fragmentation capability. Another important difference is that the handpiece and instrumentation of the VASER system are lighter, smaller, less bulky, and more convenient than those of previous systems [19–22].

3.2 Vaser lipoplasty technique

For any procedure involving liposuction and body contouring pre – operative marking with the patient standing, is a must. Once marking is done and after administering Local or General Anesthesia. The tumescent fluid is infiltrated to the planned operating site, until the skin is blanched. The tumescent fluid composition used by us is mentioned below.

Tumescent fluid composition:

Lidocaine – 35 – 55 mg/kg body weight.

Epinephrine – 1: 1000000 meq/ body wt.

Sodium Bicarbonate – 12.3 meq / body wt.

Hyaluronidase – 1500 IU/ 1000 ml of fluid.

Ringer Lactate / Normal Saline – Mix all in 1 liter.

A minimum of 7–10 mins after the infiltration is required for the vasoconstrictive effects to take place. The access incisions of 4–5 mm are made using 11 no: blade and skin protectors (ceramic or plastic) are placed. They're made to prevent injury

to the incision edges during the fragmentation process [19]. The skin near the port should be covered with a wet towel to prevent unintended burn lesions if a probe comes into contact with exposed skin. This safety is particularly important in curved areas, where the surgeon's maneuvers to reach the treatment area can expose the skin to probe touch causing collateral damage due to the heat generated.

The first step in the VASER use is to create tunnels in the subcutaneous area so as to prevent damage to the Ultrasound probe. The probe must then be inserted via the port; simple axial back-and-forth motions should be used, with no levering to the sides or up and down. Without unnecessary pressing, the probe should be pushed smoothly at a pace that the tissue and VASER settings allow. It's best to travel at a pace that's close to or slightly slower than normal suction cannula movement. The probe should never be stationary and should always be kept moving parallel to the skin.

Cross-tunneling is highly desirable and should be used wherever possible to achieve more uniform emulsification and better aspiration. If the probe is vibrated in the air, it can cause damage hence the distal 1 or 2 cm of the probe must always be in contact with tissue or fluids or within the skin port and subcutaneous tissue. End-hits and scratching the dermis from below should be avoided to prevent burns to the skin.

The diameter of the probe and the amount of grooves on the tip has an effect on how well it penetrates any given tissue. Probes with more grooves emulsify fat tissue more effectively for a given diameter, but they do not easily penetrate fibrous tissues due to the large amount of vibratory energy transmitted to the sides of the probe rather than the tip.

For fibrous tissues, probes with less grooves are better. Apart from the number of grooves, smaller diameter probes penetrate fibrous tissues more easily. The 3.7-mm probes are designed for rapid debulking and contouring of soft to fibrous tissues in medium to large volumes. The 2.9-mm probes are used for fine contouring and treating smaller soft to highly fibrous localized fat deposits and sensitive areas.

In general, the continuous mode should be used in fibrous tissues for faster fragmentation and when tissue emulsification with the VASER mode is difficult. For more delicate work, finer sculpting, or softer tissues, use the VASER mode. The probe must pass smoothly through the tissue after the system has been calibrated. If the probe fails or drags, the amplitude should be increased, or a probe with less grooves or a smaller diameter should be chosen.

Initial application times with the VASER or continuous mode are recommended to be no more than 1 minute per 200 mL of infused solution, but this method typically results in only partial fragmentation of a targeted area. The manufacturer recommends these settings, but experience and practice allow for up to 1 minute per 100 mL infused. In general, the surgical endpoint occurs anywhere between the tissues' loss of resistance to the probe and that according to the time guidelines.

Suction-assisted lipoplasty or power-assisted lipoplasty may be used to aspirate the targeted localized fat deposits after emulsification [19–26]. Additional aspiration may be needed for optimum esthetic refinement, and since the site is dry, the probe cannot be reapplied after aspiration. Sutures are used to close the incisions, and a typical liposuction postoperative treatment begins.

3.2.1 Clinical outcome

When used in combination with suction-assisted lipoplasty or power-assisted lipoplasty, the VASER system operates in a complementary manner. It's a fatty tissue pretreatment process that uses ultrasound energy to fragment/emulsify fat before aspiration. It uses the least amount of ultrasound power possible to precondition fatty tissue for subsequent aspiration while preventing damage to other

elements of the tissue matrix and surrounding tissues thanks to its smaller diameter and specially built probes. Without extending the operative time, it is possible to treat a larger number of area with more cross tunnels for more consistent fragmentation as seen in **Figure 4**.

Histochemical analysis of the aspirate confirmed 70 percent to 90 percent cellular disruption when using VASER energy. Ultrasound energy splits the cellular membrane and releases the lipid content into the extracellular environment, but it does not induce the release of fatty acids from the triglyceride molecular structure, so the fat tissue that remains is not damaged.

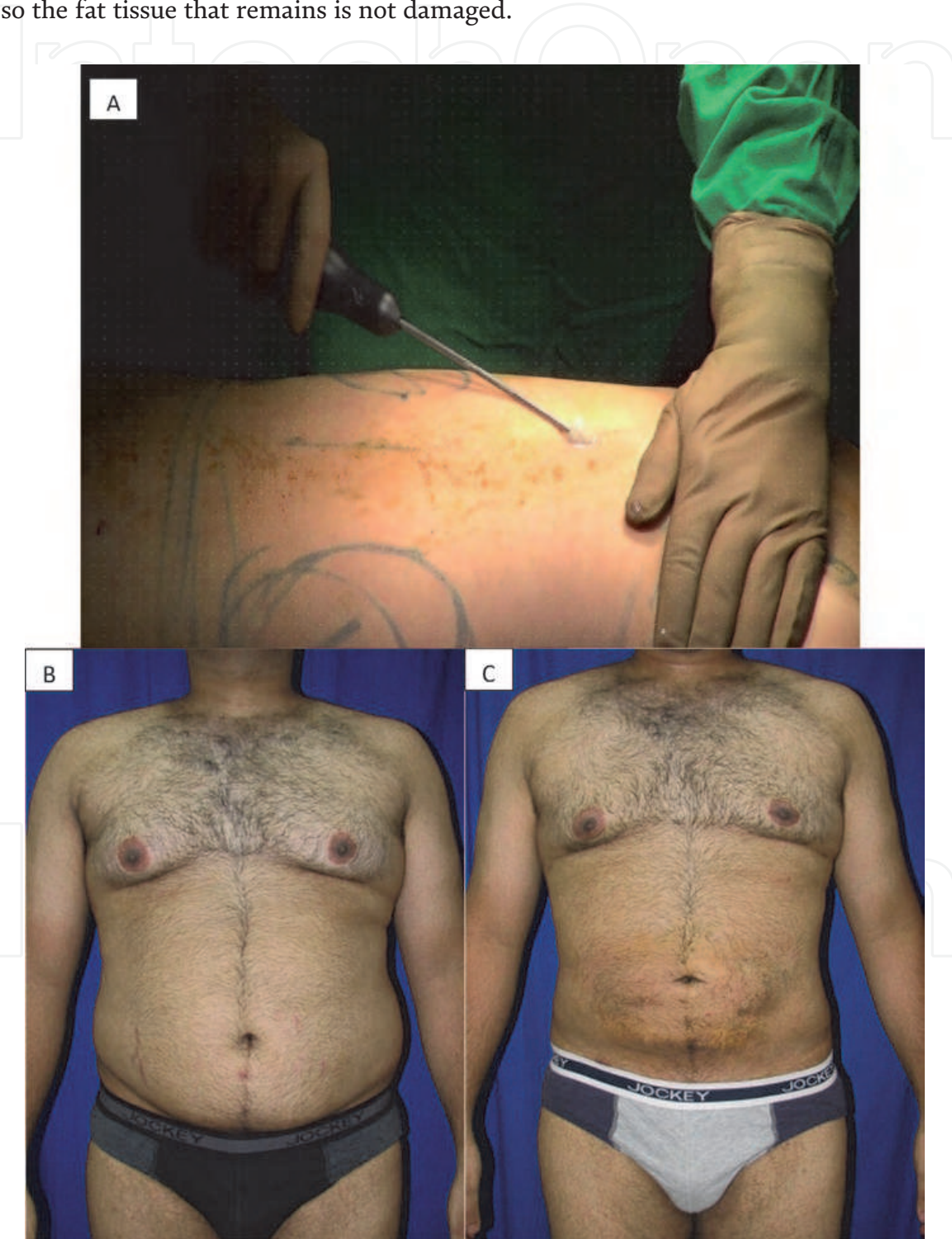

Figure 4.
(A) VASER technology being undertaken on the back with cross tunneling. The photograph shows the VASER probe being used to melt fat. Note the skin protection using a ceramic shield. (B) Pre and (C) post procedure photographs (4 weeks after surgery) of a 32 year old male patient who lost 10 kgs with diet and exercise and further wanted to shape his body to get a flat abdomen and not so protruding chest underwent VASER assisted liposuction.

3.2.2 Complications

The most recent series comparing the VASER device to first- and second-generation UAL devices found that the VASER device has a low to zero incidence of complications, while the average incidence of complications with earlier UAL devices is about 5%. Seromas or delayed bursa formation, prolonged dysesthesias, burns, induration, contour irregularities, hyperpigmentation, cellulitis, and prolonged swelling are the most common UAL complications, although these have been attributed to the use of excessive energy or prolonged application. When it comes to neural injury, studies have shown that the length of exposure is more important than the use of ultrasound energy.

The lower need for energy required for emulsification due to the optimization of the applied energy by the grooved probes and the pulsed emission of energy in the VASER mode may explain the lower incidence of such complications with the use of VASER. Burns and ischemic injuries associated with UAL systems have been documented in the literature, and they tend to be linked to execution issues such as end-hitting and intimate contact with the dermis from below [19].

3.3 Water jet assisted liposuction

A small, targeted, fan-shaped jet called Body-Jet (Human Med, Mecklenburg-West Pomerania, Germany) (Figure 5) is used to infuse fluid during water jet-assisted lipoplasty (WAL) (Figure 6). The fluid's goal is to loosen fat cells with as



Figure 5.
Water jet device.

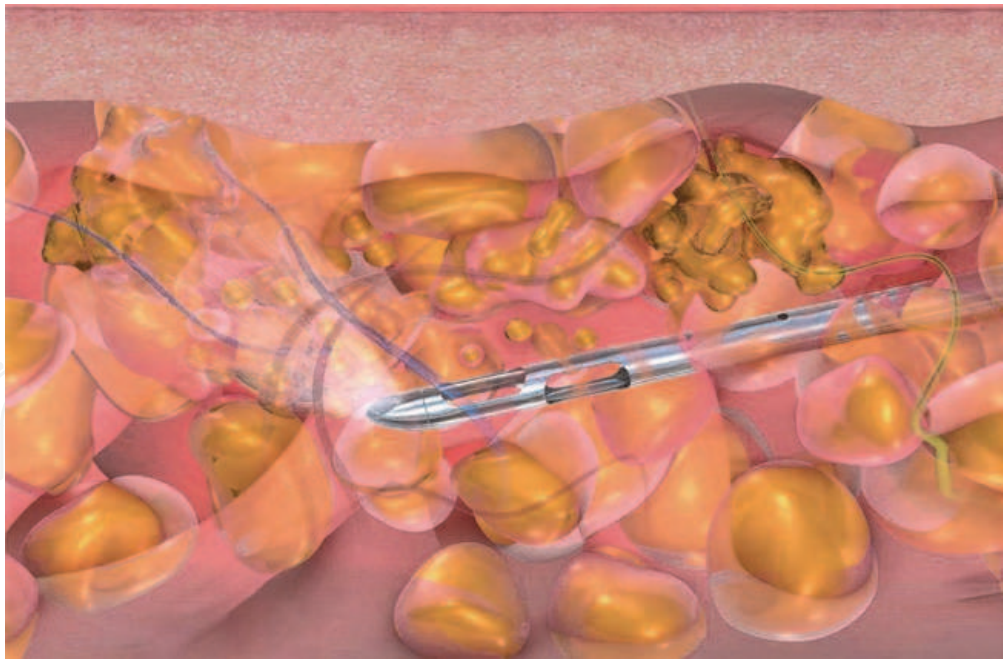

Figure 6.
The fan shaped jet of water infused into the tissues.

little collateral damage as possible, rather than cutting sharply through tissue. The jet is guided into adipose tissue to loosen the tissue structure and allow adipocytes to escape. This is an active method that replaces the conventional passive fluid entry processes of diffusion and osmosis [27].

3.3.1 Technique

WAL employs a dual-purpose cannula (**Figure 7**) that delivers pulsating, fan-shaped jets of tumescent solution, accompanied by simultaneous suctioning of fatty tissue and infused fluid.

The infiltration solution is pumped through a closed tubing system into a passageway within the device cannula by a variable-force infusion pump. The fluid is sprayed at a 30° angle from the cannula's nozzle tip to loosen the fatty tissue. A separate channel inside the cannula is connected to an integrated suction unit, and washed-out fatty tissue is evacuated from surgical sites. The diameter, arrangement, and sharpness of the openings differ among cannulas. Depending on the intent, the flow rate of the infiltrate as well as the application of variable intensities of negative pressure may be selected. To collect the aspirate without centrifuging



Figure 7.
Image of a dual purpose cannula.

under reduced negative pressures, a sterile container can be connected between the operating cannula and the suction pump.

Long-lasting, maximum anesthesia with minimal side effects is achieved using a two-stage procedure involving two separate tumescent solutions. Preinfiltration, for instance, induces rapid generalized anesthesia and vasoconstriction in the treatment area. Aspiration with a “rinsing solution” containing only small amounts of analgesic is then performed to enhance the analgesia effect and optimize vasoconstriction. The infiltration solution consists of a relatively short-acting analgesic with rapid uptake coupled with a long-acting analgesic with gradual uptake (based on pharmacokinetics). The goal of this formulation is to extend the spectrum of efficacy while keeping each agent’s side effects to a minimum [28, 29].

We currently use lidocaine which is considered very safe when used in sufficient doses [30, 31]. We also use epinephrine to induce vasoconstriction.

3.3.2 Method

WAL treatments are recommended for patients who have moderate adiposity with mild to moderate skin laxity, as well as those who want fat augmentation at the same time [32]. Pregnancy, uncontrolled diabetes mellitus, collagen disorders, cardiovascular diseases, and bleeding disorders are considered as an exclusion criteria.

3.3.3 Infiltration of anesthetic solution

To fully anesthetize the sensory nerves, low volumes of buffered 0.5 percent lidocaine containing 1:200,000 epinephrine (eight parts lidocaine, two parts 8.4 percent sodium bicarbonate) were injected above the fascial planes to anesthetize the surgical area. Separating the skin-fat layers from the underlying muscular-fascial layers was made easier by gripping the tissues in a fold.

For more extended periods of anesthesia, smaller amounts of 0.5 percent bupivacaine, up to 50 mL, were injected into sensitive areas over bones (costochondral rib margins, iliac crests, paraumbilicus) and along the boundaries of the planned suctioning areas.

3.3.4 Phase 1: infiltration of tumescent solutions

With the exception of lidocaine concentration, the tumescent solution used in Phases 1 through 3 contained similar ingredients (**Table 1**). After the skin-fat folds were grasped away from the underlying musculofascial structures, an infiltration cannula was inserted in the deep subcutaneous fat. The Body-Jet system was set to “1,” which sprayed the prewarmed wetting fluid at the lowest rate, 90 mL per minute, about 2.5 cm in front of the nozzle. The cannula was slowly moved back and forth in the same tract, resulting in a path of hydrodissection as the spray was directed downward (toward the fascia) on the first pass and upward (toward the

Phase 1	ml	Phase 2 and 3	ml
Normal saline	1000	Normal saline	1000
Lidocaine 1%	50 (500 mg)	Lidocaine 0.5%	25 (250 mg)
Epinephrine 1 mg/mL	1	Epinephrine 1 mg/mL	1
Sodium bicarbonate 8.4%	20	Sodium bicarbonate 8.4%	20

Table 1.
Standard wetting solutions.

skin) on the second pass in a twisting motion. Hydrodissection corridors were created in a fan-shape pattern, covering the entire suctioned zone. The low infiltration rate provided adequate anesthesia, effective fat lobule rinsing, and minimal tissue boggy in preparation for suctioning.

3.3.5 Phase 2: simultaneous irrigation and aspiration

Low infiltration settings were preferred over higher infiltration settings during Phase 2 to allow for more efficient aspiration of minimally turgid tissues. Once the skin-fat folds were distracted from the underlying muscle fascia, a slow, deliberate “to and fro” motion of the cannula was the most effective method for removing fatty tissue through the predetermined fan-shaped pathways. When dealing with denser fibrotic tissue, a cannula with a larger or sharper orifice was chosen. At 750 mm Hg of negative suction, a higher infiltration rate was found to be possibly more efficient for fat removal. A lack of fatty tissue withdrawn in the tubing, a decrease in the diameter of the grasped fat fold, and the occurrence of minimal resistance during repeated cannula passages were used to assess the clinical endpoint.

3.3.6 Phase 3: drying

Step 3 involved using a cannula with fenestrations on the underside to scrape fat remnants under the dermis with a low rate of tumescent solution penetration and a high degree of negative suctioning. The cannula was threaded back and forth slowly during this process, with openings guided away from the dermis to reduce skin irregularities. To remove any residual abnormalities, the irrigating and suctioning functions were switched off to “feather” the tissues.

3.3.7 Post-operative management

To allow drainage over the course of 24 hours, a Penrose or a tube drain can be placed into one of the dependent openings. Other incisions were closed loosely with a single suture and foam sponges were used to provide compression as well as absorb the drainage. Patients were advised to wear a compression garment around the affected region for at least four weeks before returning to normal activities.

3.3.8 Advantages

- In contrast to the amount of tumescent solution used in typical manual lipoplasty, an average of 20–30% was used in preinfiltration, according to the authors’ findings.
- As compared to all other tumescent-based lipoplasty methods, the suggested penetration solutions have a substantially shorter period of tumescent solution in the tissue, as well as absorption times.
- In an office-based operation, it allows surgeons to impact fatty tissue with a pulsating stream of tumescent solution while simultaneously removing aspirate under local anesthesia. Sterile fat can be collected for immediate transfer without the need for centrifuging (**Figure 8C**).
- Hematocrit changes were determined to be less than 1.0 percent, indicating that no or minimal blood was lost.

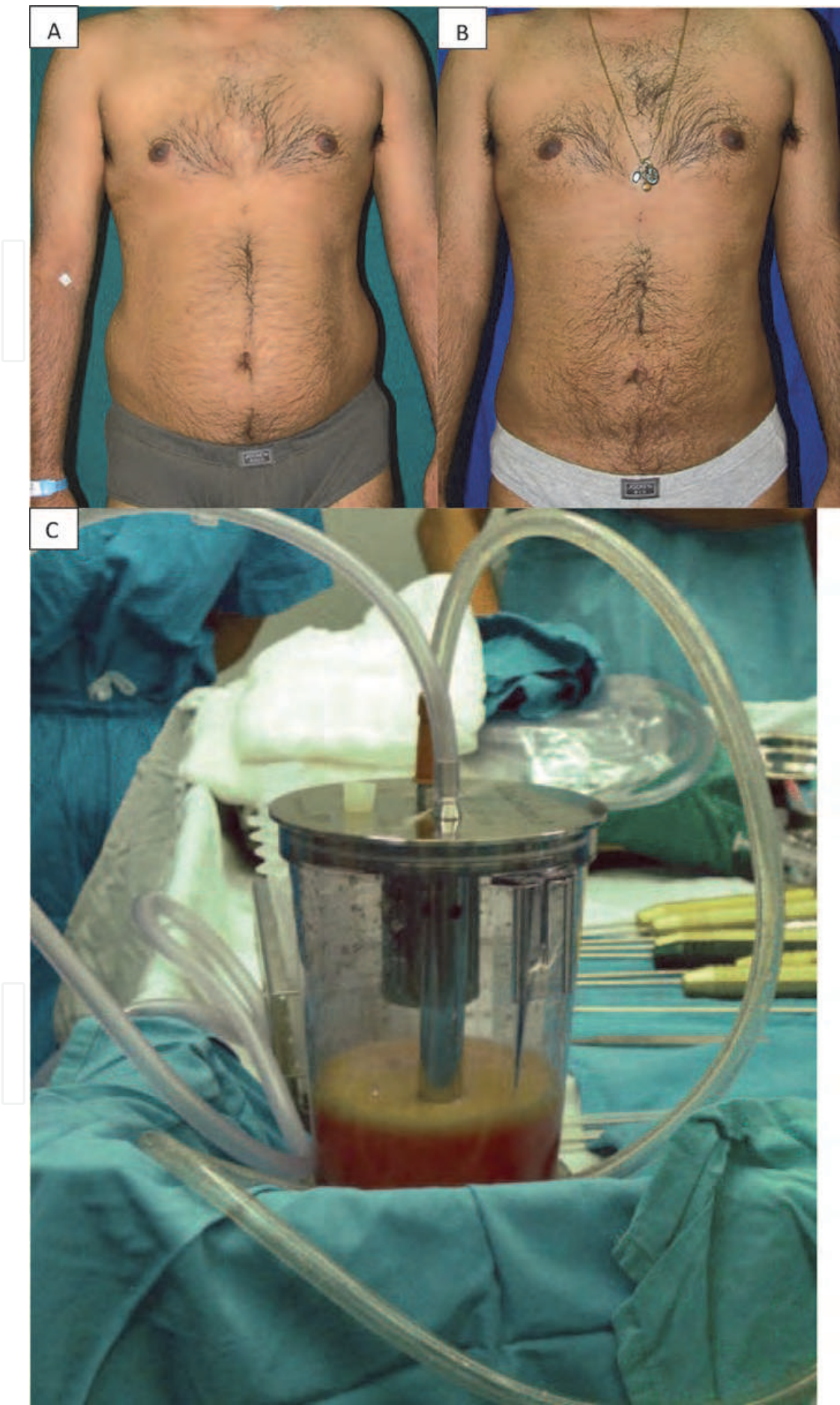

Figure 8.
Pre (A) and post operative (B) photographs (6 weeks later) of a 40 yr old patient who underwent liposuction of the abdomen and flanks along with fat transfer to the face. Fat was collected in a sterile manner using water jet technology. Fat was collected in a closed system as shown in the photograph (C).

- As compared to normal tumescent technique, there is substantially less pain-related impairment before and after the operation. Patients heal well and return to their regular routines faster.

3.4 Radiofrequency assisted liposuction

In the early 2000s, radiofrequency-assisted liposuction (RFAL) was undertaken through two main platforms: a monopolar point source with grounding pad and a novel asymmetric bipolar configuration that did not need a grounding pad. The energy is delivered between two electrodes in the latter device: an external one that maintains contact with the skin and an internal probe that is inserted into the subcutaneous fat layer. Separate temperature targets can be reached with different energy distribution (more internally than externally) (**Figure 9**). The dermis and external temperature can reach about 40°C and higher, while internal temperatures can reach up to 70°C. In addition to subtractive body contouring, these energy modalities are often combined with SAL to maximize soft tissue contraction [33, 34].

The second-generation asymmetric bipolar system (**Figures 10 and 11**) has many added safety features. When done with and without SAL, many RFAL users record substantial soft tissue contraction as a result of the applied energy [33–35].

The second generation bipolar RFAL system can be used safely and efficiently in a number of anatomical regions under local anesthesia, with a low complication rate and a quicker return to daily activities than conventional SAL and anesthesia techniques.

3.4.1 Techniques

The treated area was injected with tumescent solution (1000 mg lidocaine per 1000 mL Ringer's Lactate, 10 mL NaHCO₃, and 1.5 mL 1:1,000 concentration epinephrine) into the subcutaneous adipose layer of the treated area through an

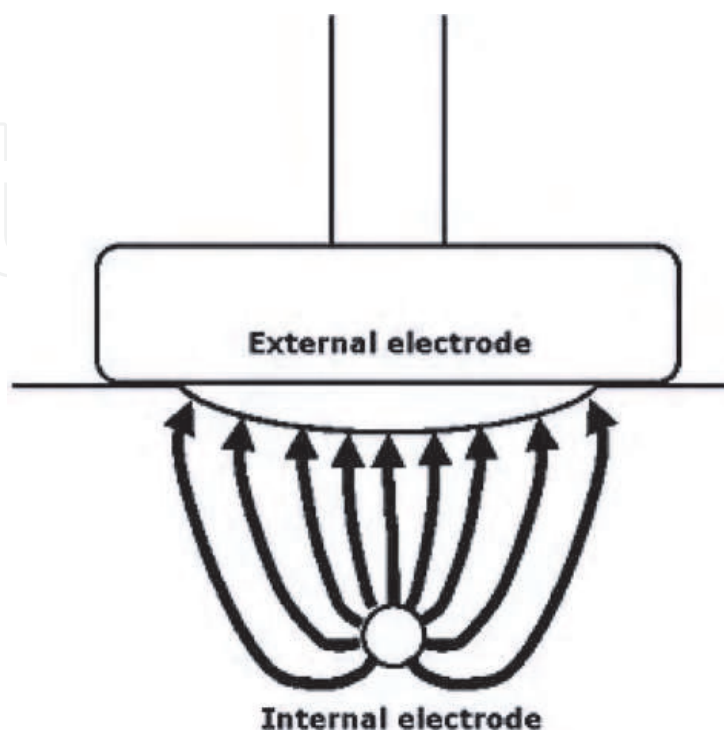


Figure 9.
The power distribution between the internal and external electrode of the radio frequency probe.



Figure 10.
Radiofrequency assisted liposuction device platform.

access incision made after careful marking of the topography of the areas to be treated. To achieve sufficient touch, the internal probe of the bipolar radio-frequency handpiece (BodyTite, InMode Company, Lake Forest, Calif.) (**Figure 11**) was inserted into the intermediate subcutaneous adipose layer, and the corresponding external probe was placed onto the skin covered in a water-based, sterile ultrasonic gel.

The device's maximum external and internal temperature parameters were then set in accordance with the operating surgeon's clinical indications. The RF system was then turned on, releasing asymmetric electromagnetic radiation to gently heat all the soft tissues between the external and internal probes until the desired temperatures were reached on both the skin and the collagen/fat layer. Once the optimum temperatures for both layers were reached, the heating was retained for several seconds according to the clinical presentation, and the energy deposition process was repeated until all treatment zones received the desired amount of energy.

Any areas requiring contouring were treated with regular manual suction-assisted lipectomy (SAL) or power-assisted liposuction (PAL) to remove excess fat




Figure 11.
Radiofrequency probes.

and fluid after this was accomplished. All access incisions were closed with 5–0 nylon sutures, and compression garments were worn on the treated areas for 3–4 weeks after surgery.

3.4.2 Final conclusion

Jowls, neck, upper arms, axillae, bra rolls (midback), flanks, hips, abdomen, male chest, female breast, medial/lateral thighs, and knees were among the common areas treated using radio frequency assisted liposuction. **Figure 12** showing Pre and Post surgery photographs of patient who has undergone RFAL liposuction of the arms.

The procedure usually takes 90–120 minutes to complete, with a tumescent injection volume of approximately 2000 mL.

The mean temperatures outside and inside were 35–42°C and 50–70°C, respectively. Following the protocols, all patients would be discharged home, with follow-up appointments set for one week and three months afterward.

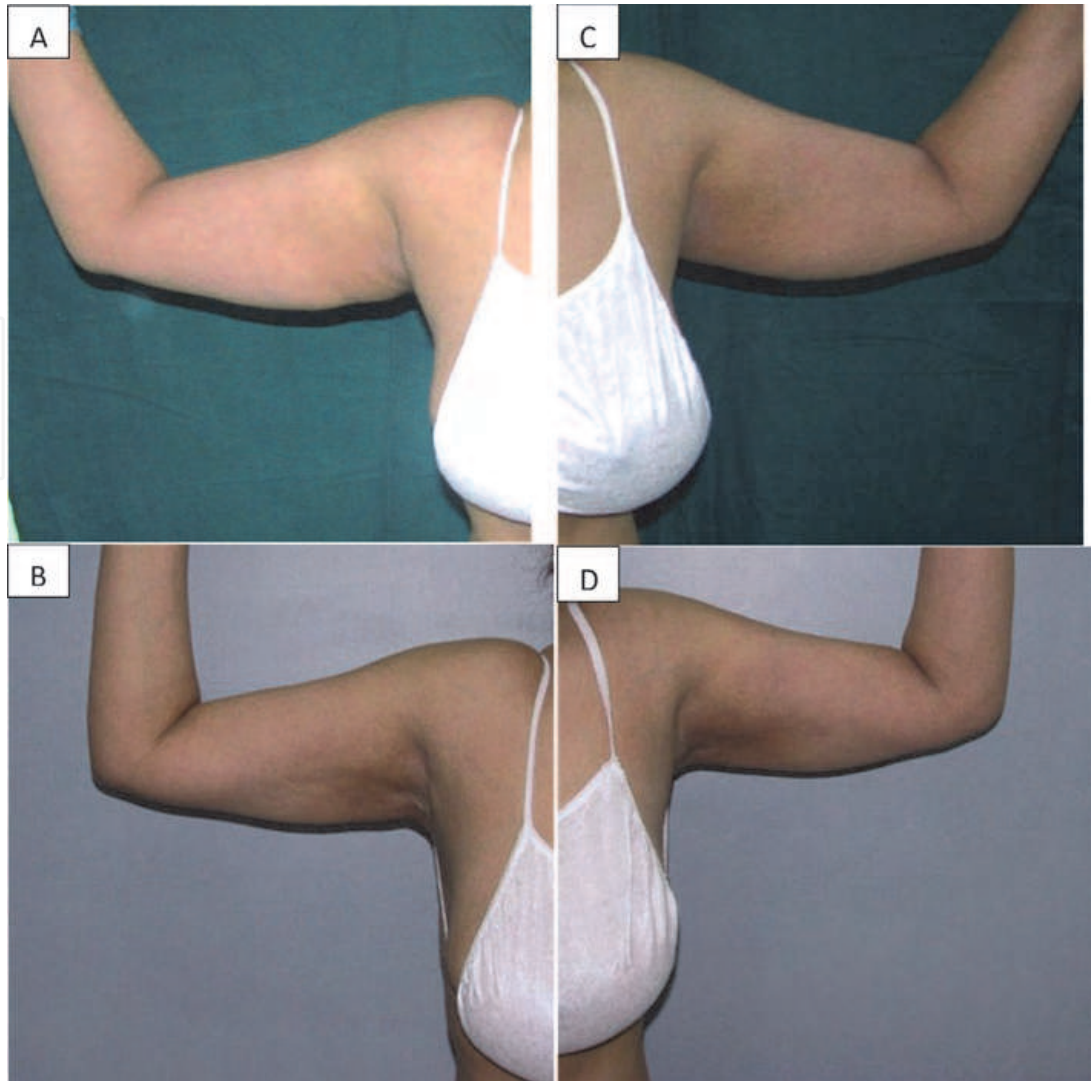


Figure 12.

(A and C) Pre-operative photograph of a 50 year old lady who has fat deposits with moderate skin laxicity in her arms. RFAL can achieve consistent and reproducible results with excellent soft tissue contraction as seen in the above post-operative images 12 weeks after surgery (B and D).

3.4.3 Complications

Temporary weakness of the marginal branch of the mandibular nerve caused ipsilateral weakness of the depressor anguli oris was observed in one case of neck and lower face RFAL. After 5 weeks of monitoring and no action, the issue was finally resolved. Two patients with burns were published in a report [35].

3.5 Laser assisted liposuction

In 1990, a 34-year-old man with abdominal lipodystrophy underwent the first laser-assisted lipoplasty under an IRB procedure. The findings of a multicenter analysis of the laser-assisted liposuction system were announced by Apfelberg et al. [36, 37] and Fodor [38]. There were 51 patients in the study, 15 of whom had laser-assisted liposuction on one side and traditional liposuction on the other. The laser-treated areas had somewhat less discomfort, edema, and ecchymosis, but the hematocrit findings were inconclusive.

The effect of low-level transcutaneous 635-nm, 10-mW diode laser radiation on the subcutaneous fat was studied by Neira et al. [39] in 2002. On human adipose tissue taken from lipectomy samples of 12 patients, total energy values of 1.2, 2.4, and 3.6 J/cm² were added. Transmission electron microscopy and scanning electron

microscopy were used where the standard adipose tissue appeared as clusters of grapes without laser exposure. 80 percent of the fat was released from adipocytes after 4 minutes of laser exposure, and 99 percent of the fat was released after 6 minutes of laser exposure. The fat that had been released had accumulated in the interstitial space. At 60,000 magnification, transmission electron microscopic images of adipose tissue revealed that the adipose cell was affected by the low-level laser energy by causing a transitory pore in the cell membrane to expand, allowing the fat content to escape from the cells.

The interstitial space cells and capillaries remained unharmed. Since red light (635 nm) does not penetrate effectively underneath the skin surface and into the subdermal tissues, Brown concluded that low-level laser therapy is ineffective. The word “greatest active depth” refers to the point at which the light intensity is so minimal that no biological impact can be measured. Just 0.3 percent of laser photons penetrate to a depth of 2.0 cm in a 50 mW/cm² exposure.

By 2005, laser lipoplasty (SmartLipo, Deka, Florence, Italy) as seen in **Figure 13** with a pulsed 1,064nmNd:YAG laser was commonly used in Europe and Latin America, and had recently been introduced in Japan and the United States. The SmartLipo hand piece is a cannula with a handle that has a diameter of 1 mm. The glass laser fiber extends through the cannula to the open end, and the laser energy is directed to the fat from the cannula tip. On the market, this cannula was the first so-called bare fiber free beam laser lipolysis kit. On October 31, 2006, Cynosure obtained FDA approval for the Smart Lipo product for sale in the United States.



Figure 13.
The Smart Lipo machine by Deka with a pulsed 1064 nm Nd:YAG laser.

3.5.1 Technique

The tumescent anesthesia technique remains the same as mentioned in 3.1 above. After waiting for an adequate period of time the laser cannula is slowly passed through the tissue to achieve lipolysis in the different levels of fat (superficial, medium, and deep) and into the subdermal plane where enough accumulated energy must be delivered. When the laser is used in the subdermal plane, the skin feels warm to the touch. Once the laser was used for lipolysis, the fat was aspirated using a 3 mm liposuction cannula. Acute adipocyte rupture and subdermal collagen band rupture is seen in histological studies. Tiny areas of fat deposits, areas with moderate or possible flaccidity, highly vascular areas, and secondary liposuction with defects, fibrosis, or other difficult cases are ideally suited for this procedure, which takes longer than traditional liposuction.

LAL is a surgery technique that has been recently introduced. However, credible studies comparing its advantages, protective features and effectiveness to those of the well-established technique of conventional liposuction are lacking. Five studies [40–44] indicated that LAL has advantages over conventional liposuction, and only two [45, 46] failed to find statistically significant differences between the techniques in the evaluated endpoints. Histological review [40, 42] shows that subcutaneous fat reduction [41, 43], skin retraction [41–43] and patient satisfaction [41, 43] were the key endpoints assessed in the studies.

Patients who have conventional liposuction procedures can experience ecchymosis, bleeding, and discomfort, which may lead to a longer recovery time [47] Jecan's [40] histological research shows that the LAL technique has potential benefits over the traditional technique, such as the protection of nerve endings and increased blood vessel clotting with less blood loss and milder grades of ecchymosis. Furthermore, the coagulation-modified collagen seen by microscopy could clarify the esthetic advantage of skin retraction after laser use, as shown in other studies [48].

However, promising outcomes in histological evaluations should be backed up by randomized trials that look at specific clinical endpoints.

Two studies [41, 43] found that the LAL technique produced superior results in terms of subcutaneous fat reduction as measured by ultrasound analysis after the procedure. The use of a laser could potentially aid in the destruction of adipocyte membranes, making removal simpler and more uniform, as well as improving the clotting of tiny blood vessels and lymphatic vases. Huge amounts of fat may be eliminated thanks to these benefits, reducing the risk of hemodynamic complications [49, 50].

LAL has the ability to cause collagen formation as well as fatty tissue rupture and liquefaction, allowing for further remodeling and skin retraction [50–52]. Wolfenson's major skin retraction could mean that the use of a dual-wavelength diode laser (924–975 nm) allows for subcutaneous cell tissue and deep dermis remodeling. The most important advantage of laser-assisted liposuction is the skin tightening effect. For that to occur, as previously described, achieved internal temperature should be within the 48–50°C range. That temperature promotes desired thermal injury within the dermis (**Figure 14A**). Subsequently the physiologic healing process is initiated which leads to fibroblast stimulation and neocollagenesis. At the same time, the heat itself shrinks the existing collagen. The final effect is superior skin redraping. Significant decrease in blood loss can be observed during the laser-assisted vs. conventional liposuction. Goldman reported coagulated blood vessels in fatty tissue in the histological analysis of lipolytic tissue.

The use of laser during the liposuction procedures enables the use of smaller cannulas. The fat is being liquefied during the laser lipolysis and in the melted form

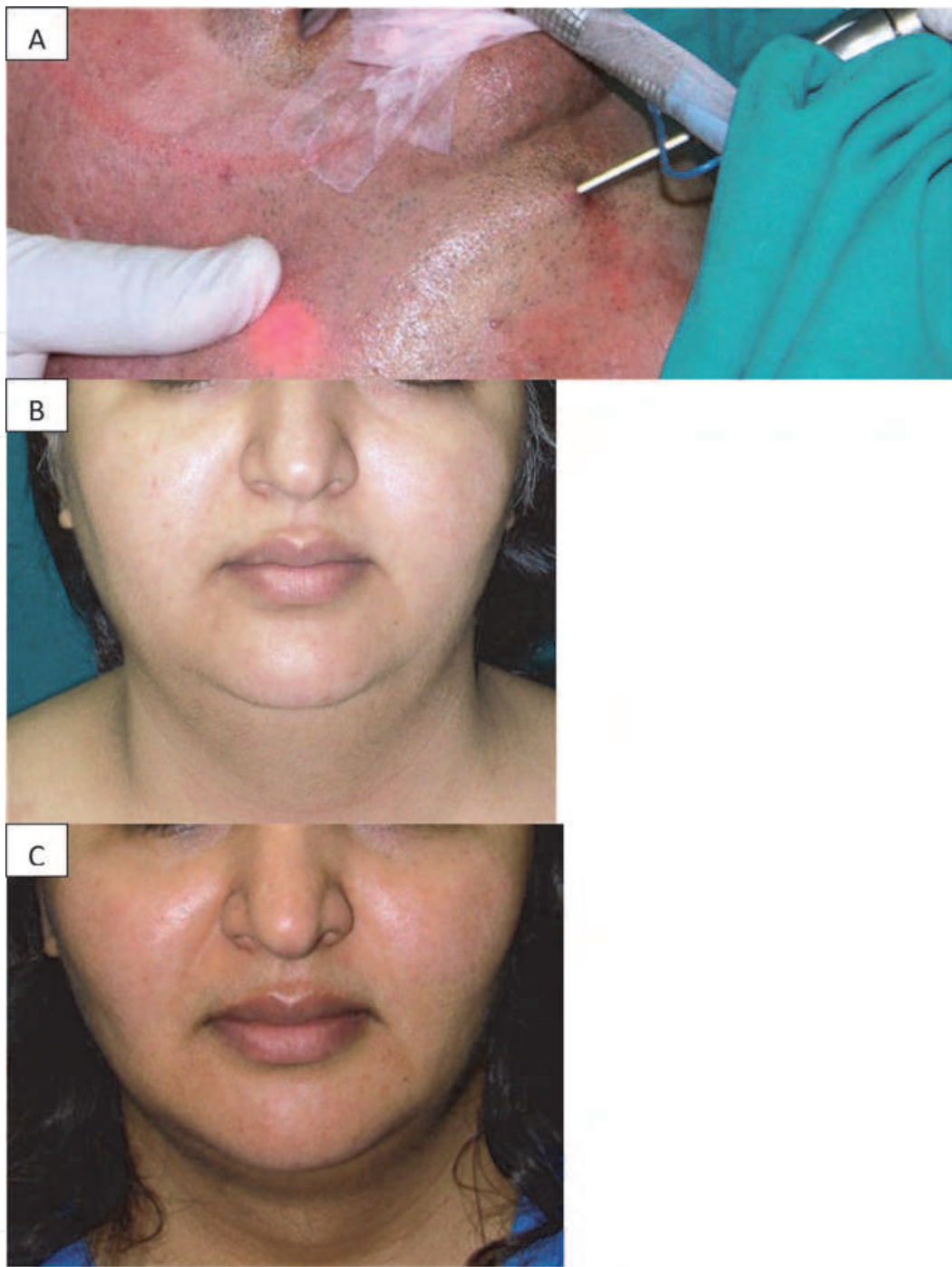

Figure 14.
(A) Laser fiber being used for lipolysis in the cervicofacial area. A red colored hue can be seen in the subcutaneous layer when the laser is fired. Patient pre (B) and (C) 7 days post-operative photographs in a 48 year old lady who had lost her jawline due to weight gain.

can be suctioned through smaller cannulas. The liquefaction of fat combined with smaller cannulas for suction enable the treatment of smaller areas as well as the areas that are highly fibrous and where the fat is enclosed in smaller compartments. That advantage is especially significant when treating post-liposuction irregularities, face, male chest, knees, hips and back. **Figure 14B** and **C** are the pre and post photographs of a lady who has undergone cervico facial Liposuction.

3.5.2 Complications

The most common concern regarding the use of lasers in the subcutaneous area is the overheating of the tissue and subsequent burns and skin necrosis. It is

important to bear in mind that the injury came from the subcutaneous plane. Therefore, if any blistering occurs in the postoperative period it will definitely result in a full-thickness burn although initially it may appear as superficial one. Due to the scarring of the full-thickness burn, this has to be avoided at all costs.

3.6 J plasma/renuvion assisted liposuction

One of the newer entrants to the energy-based device market is Renuvion® (Apyx Medical, Clearwater, Florida), which is powered by helium plasma. Cold Atmospheric Plasma (CAP) in a highly reactive (partly) ionized physical state that comprises a mixture of physical and biologically active agents and thermal levels of varying degrees is used for this purpose. Through the interaction of the plasma beam (He) with the surrounding air (N₂, O₂) or the water in the tissue (H₂O), cold plasma generates radical species. Reactive oxygen species (ROS) and reactive nitrogen species (RNS) are understood to cause cell proliferation and cell death, while extreme amounts of reactive oxygen and nitrogen species can induce protein, lipid, and DNA apoptosis and damage. These interactions can lead to epigenetic changes at the cellular level [53].

The unique Renuvion energy—helium plasma and proprietary radiofrequency (RF)—allows for precisely controlled delivery of heat to tissue, with minimal thermal spread and rapid heating with near-instantaneous cooling in part aided by the cooling effect of helium gas under the skin (in subdermal applications), which allows for shorter duration of activation and, therefore, less diffusion of heat to the skin. For just a brief interval, it flows through the application site and then disperses, leaving very reliable, predictable results.

There is no net electrical movement across the body, so there is no return electrode needed.

The cold plasma effect is extremely localized, reducing collateral damage to healthy tissue surrounding it. With its reduced tissue spread, Renuvion uses nonconductive currents and limits direct injury, reducing the chance of direct and capacitative coupling.

In addition, Renuvion facilitates secure and efficient coagulation/ablation/incision of tissue with controlled accuracy when tissue is ablated and decreases fear of damage to healthy surrounding structures. The Renuvion thermal ablation zones are illustrated in **Figure 15** and contrasted with normal electrosurgical ablation zones based on current.

In a number of tissue types and contrasts with various instruments, the Renuvion helium unit has limited lateral and thermal spread depth and its tissue effect depth varies from no apparent effect to approximately 2.0 mm with a lateral spread varying from 1.0 mm to 4.0 mm overall diameter for normal use [54].

3.6.1 Renuvion/J-plasma subdermal method of action

The average body temperature is 37° and can rise to 40° with normal illness without permanent effect or damage to the body cells. However, when the cell temperature in the tissue exceeds 50°, cell death takes place in around 6 minutes. Cell death occurs when the temperature of cells in the tissue exceeds 60° instantaneously [55].

Between the temperatures of 60° and just below 100°, 2 simultaneous processes take place. Protein denaturation leading to coagulation is the first. The second is desiccation or dehydration, since the adipocytes lose water through the thermally damaged cellular wall. Intracellular water transforms to steam as temperatures rise above 100°, and tissue cells begin to vaporize because of the massive intracellular expansion that occurs. Finally, organic molecules are broken down into a mechanism called carbonization at temperatures of 200° or more.

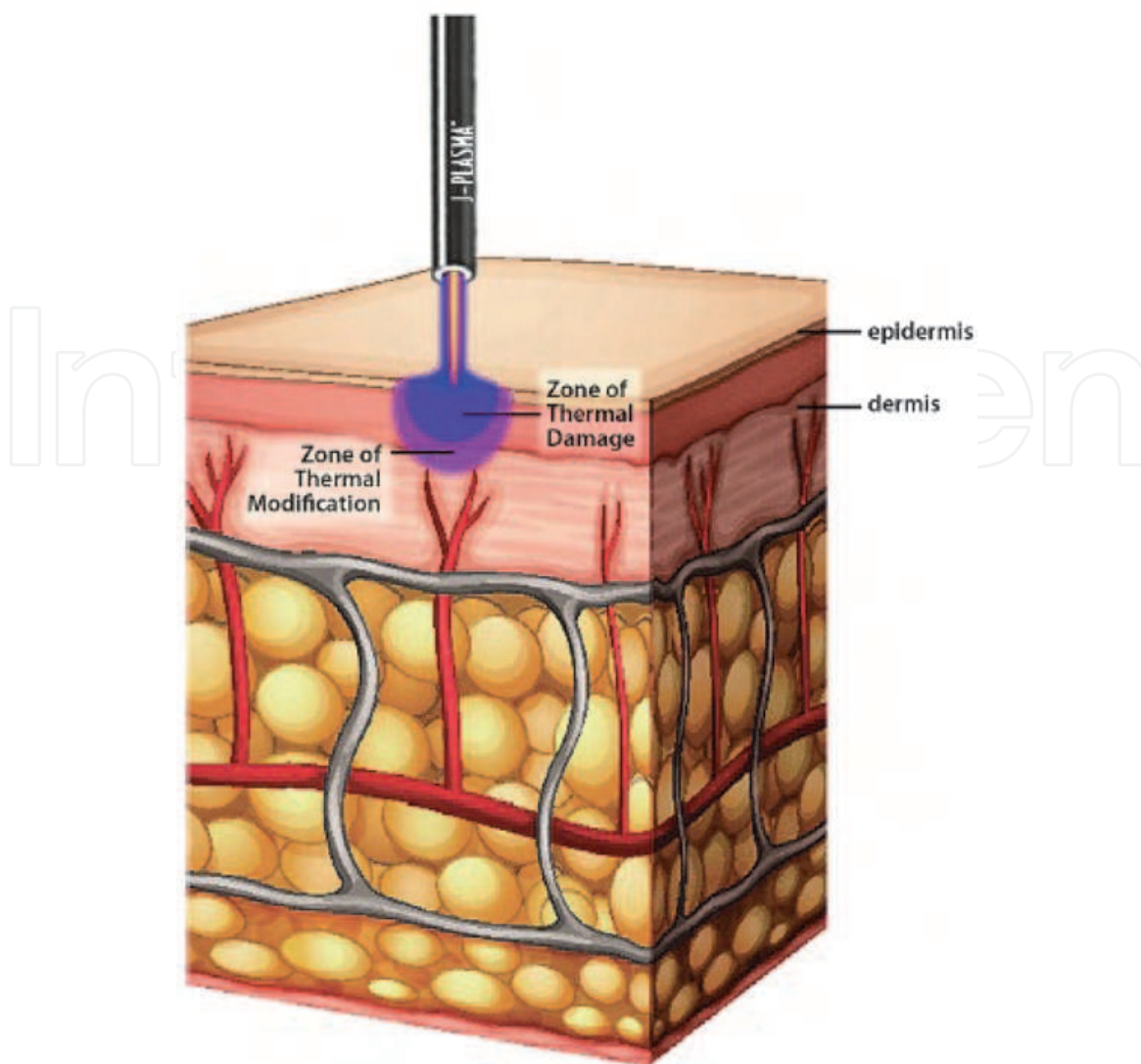


Figure 15.
Precise thermal ablation zones demonstrated with CAP/J-plasma. (Courtesy of Apyx Medical, Clearwater, FL.)

This carbonization leaves behind molecules of carbon that give the tissue a black and/or brown look. These heat effects of RF energy on cells and tissue will make it possible to use predictable changes to achieve beneficial therapeutic results.

Protein denaturation which leads to coagulation of soft tissue is one of the most commonly used tissue effects. Protein denaturation is the mechanism in which protein hydrothermal bonds (cross connections), are instantaneously destroyed and then easily reformed as tissue cools.

This step is followed by coagulation, which contributes to the formation of uniform clumps of protein commonly called coagulum. Inside the cellular proteins are altered but not killed in the coagulation process and form protein bonds that create homogenous, gelatinous structures. The resulting coagulation tissue effect is extremely helpful and is most widely used to occlude blood vessels and induce hemostasis.

One of the major proteins present in human skin and connective tissue is collagen. Collagen's coagulation/denaturation temperature is conventionally stated to be 66.8 C, although this can vary for various types of tissue [56].

Once denatured, as fibers shrink to one-third of their total length, collagen quickly contracts. However, the amount of contraction depends on the temperature and duration of the treatment. The hotter the temperature, the shorter the amount of maximum contraction treatment time required [57].

In medicine, this phenomenon of thermally induced collagen contraction by denaturation and coagulation of soft tissue is well known and is used in ophthalmology, orthopedic applications, treatment of varicose veins, and cosmetic plastic surgery procedures to produce beneficial results.

The use of thermal-induced contraction of collagen/tissue has recently been extended to minimally invasive procedures. Subcutaneous tissue coagulation results in the contraction of collagen/tissue that decreases skin laxity. The helium-based plasma technology of BMC's Renuvion (formerly branded as J-Plasma) has FDA approval for soft tissue cutting, coagulation and ablation.

The Renuvion device consists of a generator unit for electrosurgery, a handpiece, and a helium gas supply (**Figure 16**). RF energy is delivered to the handpiece by the generator and is used to energize an electrode.

A helium plasma is generated when helium gas is passed over the energized electrode, which enables heat to be applied to tissue in 2 distinct ways. First, through the ionization and rapid neutralization of the helium atoms, heat is generated by the actual production of the plasma beam itself. Secondly, because plasmas are very good electrical conductors, a portion of the RF energy which is used to energize the electrode and produce the plasma passes from the electrode to the patient and heats the tissue by passing current through the tissue resistance, a method known as Joule heating.

These 2 tissue heating sources give the Renuvion device some unique advantages for the purpose of coagulation and contraction of subcutaneous soft tissue during use as a surgical tool.

3.6.2 Renuvion for skin tightening and skin rejuvenation

Renuvion may be used for skin tightening using tumescence anesthesia with or without liposuction. Different areas of applications commonly include jawline, submental region, posterior arms, trunk and upper medial thighs (**Figure 17**).

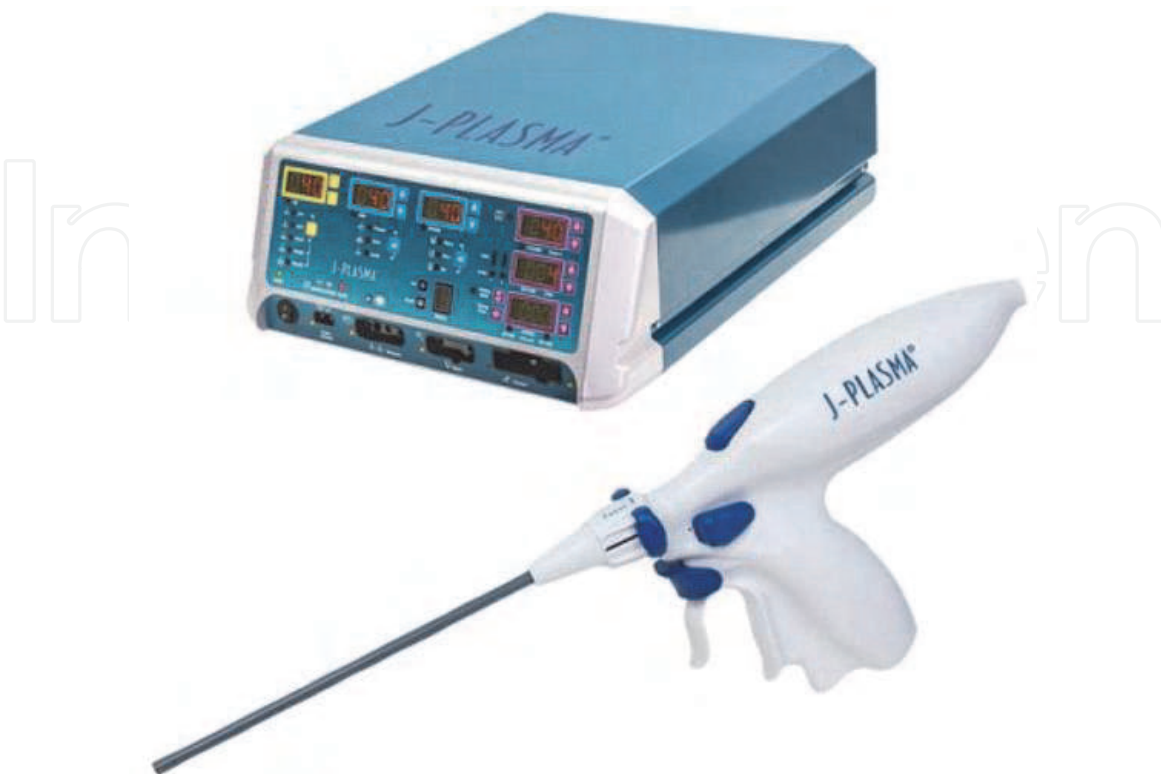

Figure 16.
The J-plasma compressor and the probe.

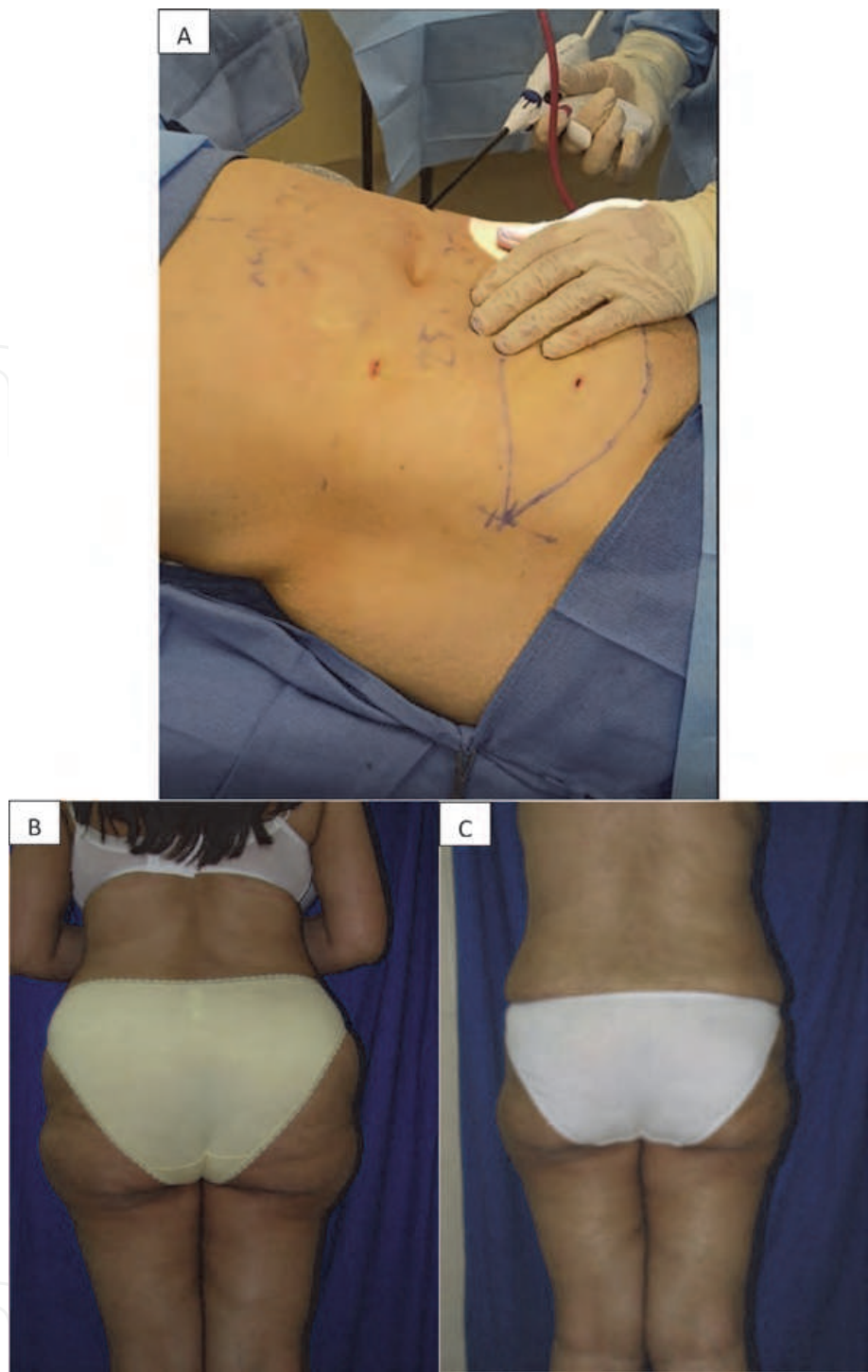


Figure 17.
(A) Renuvion being used for skin tightening in the abdomen after traditional liposuction. Pre (B) and post (C) procedure photographs of a 47 year old lady who wanted to drastically reduce her buttocks as they were in congruent with the shape of her legs. She underwent renuvion for the buttocks along with suction assisted liposuction to take out 5 liters of fat just from her buttocks. The post-operative photograph was taken 8 weeks after surgery.

One of the main key points to achieve good tissue response and proper results with Renuvion® is to assess tissue thickness and depth. The thicker the treatment area is, the higher power and more passes are needed and vice versa. For example, treating submental region and jawline represents an area with thin skin and not significant amount of subcutaneous tissue as compared to the trunk. So, when treating the submental region and jawline, keep the power setting at 60% with Helium flow of 1.5–2 liters/minute and based on the thickness of the tissue perform 1 or 2 passes only. It is very important to avoid crosshatching in this area as this can cause thermal injury and disfiguring scarring of the neck. Staying in the superficial

subdermal plane is essential to avoid injury to the marginal mandibular nerve. It is important to keep in mind that thinner areas need less power and lower flow to avoid overzealous treatment.

3.6.3 Complications

Renuvion patients typically do not encounter any new or different complications than those identified as possible complications for the operation being performed. In fact, when compared to other energy-based devices used in the subcutaneous or interstitial space, such as fiber lasers or RF devices, whether temperature regulated or not, the complication profile is lower, thanks to the volume of unionized helium gas under the flaps, which acts as a simultaneous air conditioner. Renuvion's thermal profile, combined with unionized helium gas, produces a more balanced atmosphere than energy-based systems operating on their own.

Renuvion has a low risk of damage to surrounding tissue because of the following factors:

- Minimized thermal spread in depth and laterally;
- controllable and precise micron-level plasma stream length;
- Smoke, odor, and eschar are reduced;

There are no conductive currents going through the patients' bodies thus safe and effective on multiple types of tissue.

3.7 Power assisted liposuction (PAL)

Liposuction, a surgical procedure that removes unwanted and resistant fat from the body has been a labor intensive process for the Surgeon as well as the patient, but now there is a procedure that is less intensive and less traumatic: power assisted liposuction (PAL).

Since the introduction of power-assisted liposuction (PAL) by MicroAire Surgical Instruments, the device has undergone many advances to improve mechanical disruption of normal and fibrotic fatty areas and also works within firmer tissues after secondary surgery for superior fat extraction.

PAL is an advancement over traditional SAL that involves using a rapidly reciprocating cannula tip, in "to-and-fro" motion of the operator's arm but at a lower amplitude of 3 mm [58]. The microcannula eases through the fat and sucks the fat out. The cannula is attached to a hand piece, powered by micromotor device, that causes it to vibrate. The vibration (or reciprocation), is 4000 times per minute. This low-speed reciprocation delivers enough energy to the tip of the cannula, so it passes easily through the substance of the fat with almost no physical effort by the surgeon. This causes a "jack hammer effect" causing the breakdown of resistant parcels of fat tissue which are also avulsed and sucked by the reciprocating cannula [59]. This results in greater control of the area to be liposucked and less trauma to the patient. The vibration also assists in passing the cannula through fibrous and scar tissue.

The MicroAire lipoplasty handle (**Figure 18**) is powered by an electric power source. Both the suction and the power source, which reciprocates the cannula, are attached to the proximal end of the hand piece. As in traditional lipoplasty, the incisions are made to comfortably accept the introduction of the cannula chosen for the procedure. A guard should be preferably used to prevent injury to the entry

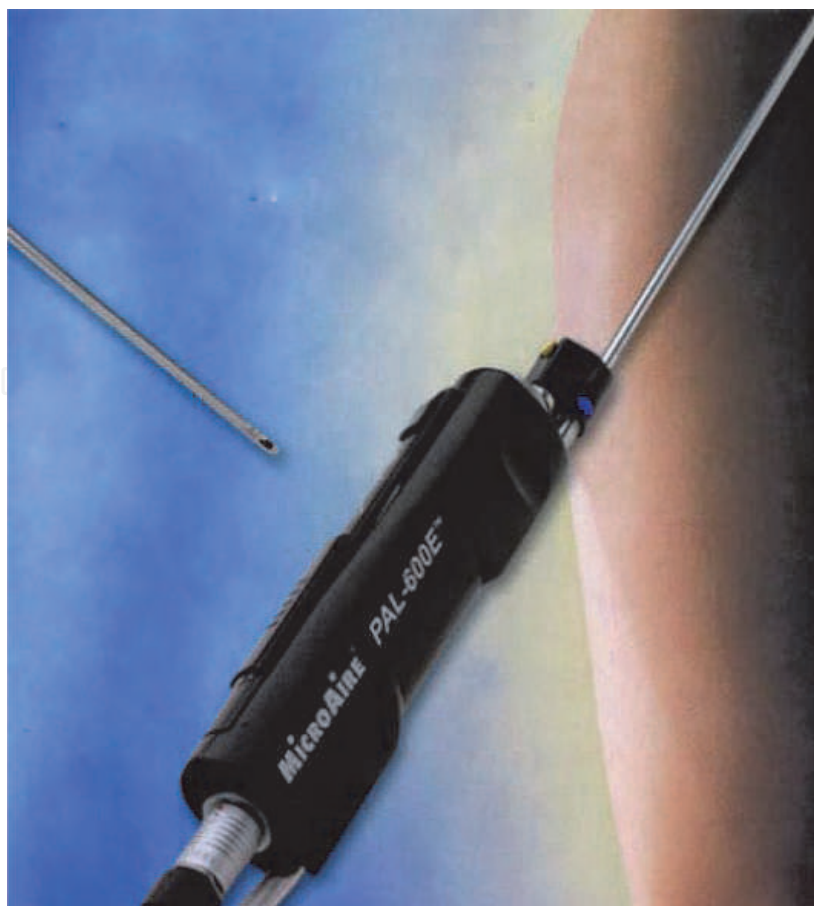

Figure 18.
Microaire handle and cannula attached.

points. The use of mechanical energy avoids the side effects and tissue injuries associated with thermal energy, such as deep tissue and skin burns, increased seromas, and painful recovery [60].

The MicroAire powered cannula should be moved slowly so as to break the resistance in the tissue. The sensation of gliding through the tissue should be felt. The end point is the pinch test as well as the obvious absence of lumps and depressions. **Figure 19** shows the pre and post surgery photographs using PAL.

3.7.1 Advantages

1. The PAL cannula breaks up fibrous fat more readily and thus becomes less laborious even when treating fibrotic areas such as Gynaecomastia and back and even in secondary Lipoplasty. It is also very beneficial if done safely for body sculpting when superficial liposuction is required.
2. The PAL cannulas do not get plugged with fibrous tissue as compared to small diameter traditional cannulas. The lipoaspirate can be used for fat grafting too.

3.7.2 Disadvantages

1. Discomfort to the surgeon due to the vibration in the hand piece which is proportional to the speed of the cannula.

Power assisted liposuction (PAL) has several advantages over ultrasonic assisted liposuction: the cannulas used in PAL are usually smaller (micro cannula), that

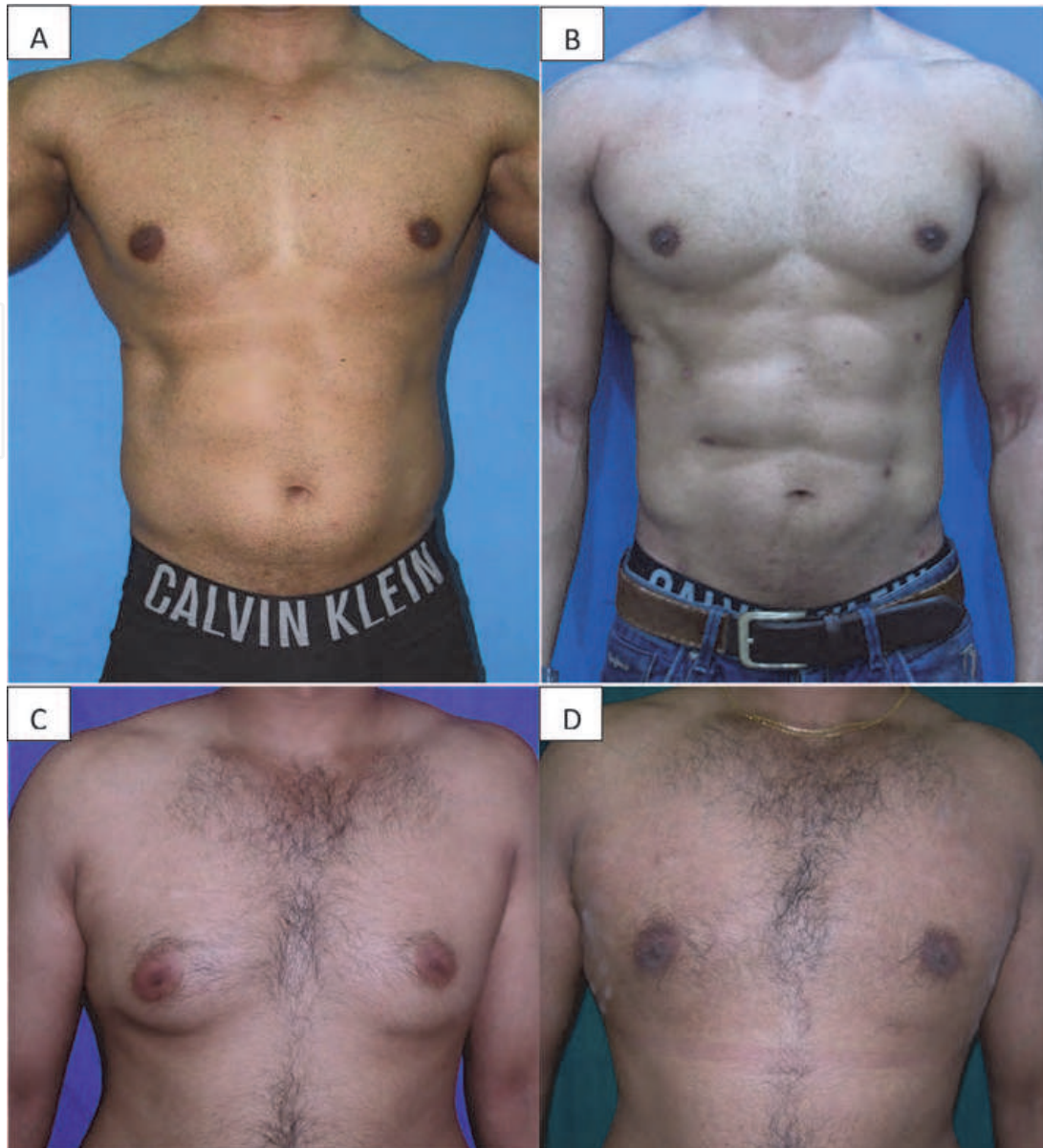

Figure 19.

Pre (A) and post-operative (B) pictures of a 27 year old man who had already worked hard to create a good body but wanted further definition of his abdominal muscle. The muscle definitions were created using the power assisted liposuction technique. Pre (C) and post-operative (D) pictures of a 22 year old male who wanted to get rid of his gynecomastia surgery using PAL. The result seen is 4 weeks post-surgery in both the patients.

result in smaller scars: there is no potential for burn injury with the PAL; liposuction procedure takes less time with PAL, therefore is safer for patients; and postoperative pain is less with PAL.

4. Conclusion

This chapter deals with the various technologies which are present in the market and in some way affect the liposuction outcome, be it to improve speed, complete evacuation of fat and achieving tightening of the overlying skin.

VASER is the single best technology in our opinion which not just helps in complete fat evacuation in normal and resistant regions but also helps in skin retraction to an extent.

J-Plasma and Radiofrequency of the tissues helps in skin retraction without any significant side effects which can become the surgeon's next investment. Overall

how effective the technology is depends on the right indications, precautions taken and not being cavalier while using it on a patient. Ultrasound and heat can destroy fat cells in therapeutic range but can also injure other tissues if used aggressively.

Conflict of interest


The authors declare no conflict of interest.

Author details

Mohan Thomas*, James D'silva and Amal Abraham
The Cosmetic Surgery Institute and Dr. Mohan Thomas Aesthetics, Mumbai, India

*Address all correspondence to: drmohanthomas@gmail.com

IntechOpen

© 2021 The Author(s). Licensee IntechOpen. This chapter is distributed under the terms of the Creative Commons Attribution License (<http://creativecommons.org/licenses/by/3.0>), which permits unrestricted use, distribution, and reproduction in any medium, provided the original work is properly cited. 

References

- [1] Schrudde J. Lipectomy and lipexheresis in the area of the lower extremities. *Langenbecks Arch Chir.* 1977;345:127–131.
- [2] Fischer G. First surgical treatment for modelling the body's cellulite with three 5 mm incisions. *Bull Int Acad Cosmet Surg.* 1976;2:35–37.
- [3] Kesselring UK, Meyer R. Suction curette for removal of excessive local deposits of subcutaneous fat. *Plast Reconstr Surg.* 1978;62(2):305–306.
- [4] Illouz YG. Body contouring by lipolysis: a 5-year experience with over 3000 cases. *Plast Reconstr Surg.* 1983;72(5):591–597.
- [5] Klein JA. Tumescence technique for regional anaesthesia permits lidocaine doses of 35 mg/kg for liposuction. *J Dermatol Surg Oncol.* 1990;16(3):248–263.
- [6] Klein JA. Tumescence technique for local anaesthesia improves safety in large-volume liposuction. *Plast Reconstr Surg.* 1993;92(6):1085–1098.
- [7] Zocchi M. Ultrasonic liposculpturing. *Aesthetic Plast Surg.* 1992;16(4):287–298.
- [8] Apfelberg DB, Rosenthal S, Hunstad JP, Achauer B, Fodor PB. Progress report on multicenter study of laser-assisted liposuction. *Aesthetic Plast Surg.* 1994;18(3):259–264.
- [9] Fodor PB, Vogt PA. Power-assisted lipoplasty (PAL): a clinical pilot study comparing PAL to traditional lipoplasty (TL). *Aesthetic Plast Surg.* 1999;23(6):379–385.
- [10] Paul M, Mulholland RS. A new approach for adipose tissue treatment and body contouring Using radiofrequency-assisted liposuction. *Aesthetic Plast Surg.* 2009;33(5):687–694.
- [11] Zocchi ML. Ultrasonic assisted lipoplasty: technical refinements and clinical evaluations. *Clin Plast Surg.* 1996;23(4):575–598.
- [12] Rohrich RJ, Morales DE, Krueger JE, Ansari M, Ochoa O, Robinson Jr J, Beran SJ. Comparative lipoplasty analysis of in vivo-treated adipose tissue. *Plast Reconstr Surg.* 2000;105(6):2152–2158.
- [13] Maxwell GP, Ginggrass MK. Ultrasound-assisted lipoplasty: a clinical study of 250 consecutive patients. *Plast Reconstr Surg.* 1998;101(1):189–202.
- [14] Jewell ML, Fodor PB, de Souza Pinto EB, Al Shammari MA. Clinical application of VASER assisted lipoplasty: a pilot clinical study. *Aesthet Surg J.* 2002;22(2):131–146.
- [15] de Souza Pinto EB, Abdala PC, Maciel CM, dos Santos Fde P, de Souza RP. Liposuction and VASER. *Clin Plast Surg.* 2006;3(1):107–115.
- [16] Coleman III WP, Brody HJ, Narins RS, et al. Update from the ultrasonic liposuction task force of the American Society for Dermatological Surgery. *Dermatol Surg.* 1997;23:210–214.
- [17] Lawrence N, Coleman III WP. The biologic basis of ultrasonic liposuction. *Dermatol Surg.* 1997;23:1197–1200.
- [18] Graf R, Auersvald A, Damásio RC, et al. Ultrasound assisted liposuction: an analysis of 348 cases. *Aesthetic Plast Surg.* 2003;27(2):146–153.
- [19] Jewell ML, Fodor PB, Souza Pinto EB, et al. Clinical application of VASER-assisted lipoplasty: a pilot clinical study. *Aesthetic Surgery Journal.* 2002;22(2):131–146.
- [20] Rohrich RJ, Morales DE, Krueger JE, et al. Comparative analysis of

in vivo-treated adipose tissue. *Plast Reconstr Surg* 2000;105(6):2152–2157.

survey results. *Dermatolog Surg* 196;22: 459-462.

[21] Beckenstein MS, Grotting JC. Ultrasound assisted lipectomy using the solid probe: a retrospective review of 100 consecutive cases. *Plast Reconstr Surg* 2000;105(6):2161–2174.

[31] Housman T, Lawrence N, Mellen BG, Beorge MN, Filippo JS, Cervenky KA, et al. The safety of liposuction: results of a national survey. *Dermatologic Surg* 2002;28:971-978.

[22] Chang CC, Commons GW. A comparison of various ultrasound technologies. *Clin Plast Surg* 1999;26: 261–268.

[32] Sasaki G.H. (2011). Water Assisted Liposuction for Body Contouring and Lipo Harvesting: Safety and Efficacy in 41 Consecutive Patients. *Aesthetic Surg Journal* ;2011 :31 (1) 76-88.

[23] Graf R, Auersvald A, Damásio RC, et al. Ultrasound assisted liposuction: an analysis of 348 cases. *Aesthetic plast Surg* 2003;27(2):146–153.

[33] Paul M, Mulholland RS. A new approach for adipose tissue treatment and body contouring using radiofrequency-assisted liposuction. *Aesthetic Plast Surg*. 2009;33:687–694.

[24] Maxuel GP. Use of hollow cannula technology in UAL. *Clin Plast Surg* 1999; 26:255–260.

[34] Duncan DI. Nonexcisional tissue tightening: creating skin surface area reduction during abdominal liposuction by adding radiofrequency heating. *Aesthetic Surg J*. 2013;33: 1154–1166.

[25] Rohrich RJ, Beran SJ, Kelken LM, et al. Extending the role of liposuction in body contouring with ultrasound-assisted liposuction. *Plast Reconstr Surg* 1998;101:1090–1102.

[35] Theodorou SJ, Paresi RJ, Chia CT. Radiofrequency-assisted liposuction device for body contouring: 97 patients under local anesthesia. *Aesthetic Plast Surg*. 2012;36:767–779.

[26] Gripaudo FR, Matarese RM, Macone A, et al. Effects of traditional and ultrasonic liposuction on adipose tissue: a biochemical approach. *Plast Reconstr Surg* 2000;106(6): 197–199.

[36] Apfelberg D, Rosenthal S, Hunstad J, Achauer B, Fodor P. Progress report on multicenter study of laser-assisted liposuction. *Aesthetic Plast Surg* 1994;18:259–264.

[27] Daniel Man; Hartmut Meyer. Water jet – assisted Lipoplasty. *Aesthetic Surg J* 2007; 27:342-346.

[28] Lillis PJ. Liposuction surgery under local anesthesia: limited blood loss and minimal lidocaine absorption. *J Dermatolog Surg Oncology* 1988;114: 1145-1148.

[37] Apfelberg D. Results of multicenter study of laser-assisted liposuction. *Clin Plast Surg* 1996;23:713–719.

[29] Rohrich RJ, Beran SJ. Is liposuction safe? *Plast Reconstr Surg* 1999;104;3: 819-822.

[38] Fodor PB. Progress report on multicenter study of laser assisted liposuction. *Aesthetic Plast Surg* 1995; 19:379–385.

[30] Hanke CW, Bernstein G, Bullock BS. Safety of tumescent liposuction in 15,336 patients—national

[39] Neira R, Arroyave J, Ramirez H, Ortez CL, Solarte E, Sequeda F, Gutierrez MI. Fat liquefaction: Effect of low-level laser energy on adipose

tissue. *Plast Reconstr Surg* 2002;110: 912–922.

[40] Jecan CR, Hernic AD, Tianu EC, Florescu IP, Lascăr I (2015) Histological differences between laser-assisted and suction-assisted lipoplasty aspirates—a comparative study. *Rom J Morphol Embryol* 56:797–801

[41] Valizadeh N, Jalaly NY, Zarghampour M, Barikbin B, Haghighatkah HR (2016) Evaluation of safety and efficacy of 980-nm diode laser-assisted lipolysis versus traditional liposuction for submental rejuvenation: a randomized clinical trial. *J Cosmet Laser Ther* 18:41

[42] Wolfenson M, Hochman B, Ferreira LM (2015) Laser lipolysis: skin tightening in lipoplasty using a diode laser. *Plast Reconstr Surg* 135:1369–1377

[43] Branñas EB, Moraga JM (2013) Laser lipolysis using a 924- and 975-nm laser diode in the lower extremities. *Aesthet Plast Surg* 37:246–253

[44] DiBernardo BE (2010) Randomized, blinded split abdomen study evaluating skin shrinkage and skin tightening in laser-assisted liposuction versus liposuction control. *Aesthet Surg J* 30:593–602

[45] Prado A, Andrades P, Danilla S, Leniz P, Castillo P, Gaete F (2006) A prospective, randomized, double-blind, controlled clinical trial comparing laser-assisted lipoplasty with suction-assisted lipoplasty. *Plast Reconstr Surg* 118:1032–1045

[46] Mordon S, Plot E (2009) Laser lipolysis versus traditional liposuction for fat removal. *Expert Rev Med Devices* 6:677–688

[47] Venkataram J (2008) Tumescence liposuction: a review. *J Cutan Aesthet Surg* 1:49–57

[48] Sasaki GH (2010) Quantification of human abdominal tissue tightening and contraction after component treatments with 1064-nm/1320-nm laser-assisted lipolysis: clinical implications. *Aesthet Surg J* 30:239–245

[49] Bazin AZ, Gondek LBE, Garcia MJ, Valle LC, Flizikowski FB, de Noronha L (2005) Analysis of laser lipolysis effects on human tissue samples obtained from liposuction. *Aesthet Plast Surg* 29: 281–286

[50] Goldman ASD, Blugerman GS (2002) Laser lipolysis: liposuction using Nd:YAG laser. *Rev Soc Bras Cir Plast* 17: 17–26

[51] Az Badin, Moraes LM, Gondek L, Chiaratti MG, Canta L (2002) Laser lipolysis: flaccidity under control. *Aesthet Plast Surg* 26:335–339.

[52] Matarasso A (2015) Discussion: laser lipolysis: skin tightening in lipoplasty using a diode laser. *Plast Reconstr Surg* 135:1378–1380

[53] Gumbel D, Bekeschus S, Gelbrich N, et al. Cold atmospheric plasma in the treatment of osteosarcoma. *Int J Mol Sci* 2017;18(9):2004.

[54] Pedroso JP, Gutierrez M, Volker W. Thermal effect of JPlasma energy in a porcine tissue model: implications for minimally invasive surgery. 2016/06/WP-Thermal_Effect_Of-J-Plasma_Energy_In_A_Porcine_Tissue_Model_Implications_For_Minimally_Invasive_Surgery.pdf. Accessed November 2018.

[55] Thomsen S. Pathologic analysis of photothermal and photomechanical effects of laser-tissue interactions. *Photochem Photobiol* 1991;53:825–835.

[56] Ross EV, McKinlay JR, Anderson RR. Why does carbon dioxide resurfacing work? A review. *Arch Dermatol* 1999;135(4):444–454.

[57] Chen SS, Wright NT, Humphrey JD. Heat-induced changes in the mechanics of a collagenous tissue: isothermal free shrinkage. *J Biomech Eng* 1997;109: 372–378.

[58] Fodor PB, Vogt PA. Power-assisted lipoplasty (PAL): a clinical pilot study comparing PAL to traditional lipoplasty (TL). *Aesthetic Plast Surg.* 1999;23(6): 379-385

[59] Young VL. Power-assisted lipoplasty. *Plast Reconstr Surg.* 2001; 108:1429-1432

[60] Fodor P. Power-assisted lipoplasty. *Aesthet Surg J.* 2001;21(1):90-92.