

PUBLICATION INFORMATION

Duncan, DI. The future of skin tightening: Mechanical or biological? Dermatological Reviews. 2020; 1: 128- 137. <https://doi.org/10.1002/der2.40>

FINANCIAL & CONTENT DISCLOSURE: Dr. Duncan is a consultant and a member of the Medical Advisory Board for Apyx Medical. The opinions contained herein are those of the author and do not necessarily represent the official position or policies of Apyx Medical, Inc.

MANUFACTURING DISCLOSURE: Apyx Medical manufactures and owns the Renuvion/J-Plasma technology discussed in this article.

INDICATIONS FOR USE & INTENDED USE DISCLOSURES

- The Renuvion® APR Handpiece is intended for the delivery of radiofrequency energy and/or helium plasma for cutting, coagulation, and ablation of soft tissue during open surgical procedures.
- The Renuvion® APR Handpiece is indicated for use in subcutaneous dermatological and aesthetic procedures to improve the appearance of lax (loose) skin in the neck and submental region.
- The Renuvion® APR Handpiece is intended to be used with compatible electrosurgical generators owned by Apyx Medical (specifically BVX-200H, BVX-200P, APYX-200H, APYX-200P, APYX-RS3, and APYX-JS3).
- Apyx Medical wants to present you with current scientific discourse. Specific usage outside of the cleared indications may not be safe or effective.
- The use of Renuvion with liposuction has not been approved or cleared by the FDA.

RISKS:

- As with all energy devices there are inherent risks associated with its use. Risk associated with the use of the Renuvion APR may include: helium embolism into the surgical site due to inadvertent introduction into the venous or arterial blood supply system, unintended burns (deep or superficial), pneumothorax, temporary or permanent nerve injury, ischemia, fibrosis, infection, pain, discomfort, gas buildup resulting in temporary and transient crepitus or pain, bleeding, hematoma, seroma, subcutaneous induration, pigmentation changes, increased healing time, scarring, asymmetry and/or unacceptable cosmetic result.

As with any procedure, individual results may vary. As with all energy devices there are inherent risks associated with its use, refer to the IFU for further information.

The future of skin tightening: Mechanical or biological?

Diane I. Duncan MD, FACS

Department of Plastic Surgery, Plastic
Surgical Associates of Fort Collins, P. C.,
Fort Collins, Colorado, USA

Correspondence

Diane I. Duncan, MD, FACS, Department
of Plastic Surgery, Plastic Surgical Associates
of Fort Collins, P. C., 1701 East Prospect
Road, Fort Collins, CO 80525, USA.
Email: momsurg@aol.com

Abstract

Introduction. Not too long ago, the concept of nonexcisional skin tightening was a field of dreams. Currently, the field of nonexcisional skin tightening is heavily device dependent. Though great strides have been made in both minimally invasive skin tightening and totally noninvasive devices, will these be in use for decades? Advances in biological research and development have been rapid. Consumer demand for regenerative solutions is high, despite the warnings from the Food and Drug Administration (FDA) noting that benefits are unproven and that instances of charlatan practice are high. While genetic modification of food is frowned upon, the use of biomarkers in medicine has become a standard of care. **Energy based devices.** Current devices that have retained value in the skin tightening arena include transcutaneous radiofrequency (RF) and microfocused ultrasound. Laser resurfacing can improve mild skin laxity but its best use is wrinkle removal and pigment and textural improvement. RF-based subdermal tightening consistently achieves a higher measured skin surface contraction than alternatives such as ultrasound-assisted or laser-assisted liposuction. High-intensity electromagnetic field (HIFEM) improves that framework that supports the overlying skin, as well as reducing diastasis recti. HIFEM can generate a 17.9% skin surface area contraction. A combination of transcutaneous RF and targeted pressure energy significantly reduces skin surface irregularities, cellulite, and striae while measurably thickening the dermis. **Injectables and biologicals.** Biologically based entries into the field include mechanically processed adipose-derived stem cells, nanofat, and exosomes. Intradermal injection of nanofat and topical application of exosomes following microneedling can "resurface" skin by reversing many age related changes. A recently approved collagenase drug can correct skin surface depressions such as cellulite, deformities following liposuction, and other areas of fibrosis. **Conclusion.** Surgical skin excision has largely been replaced with minimally invasive and noninvasive alternatives. While energy based devices still dominate this field, biologicals are rapidly gaining ground. Substances that induce cell signaling can target cell senescence. The future of skin tightening will include treatment options that offer tightening, smoothing, dermal thickness improvement, hydration, and overall skin quality improvement.

KEYWORDS

collagenase, exosomes, HIFEM, nanofat, radiofrequency, skin tightening

1 | INTRODUCTION

Before the turn of the century, nonexcisional skin tightening was only a concept. The idea, stimulated both by intellectual curiosity and consumer demand, drove esthetic surgeons and device manufacturers to come up with ways to achieve this goal. Ablative CO₂ laser resurfacing, as well as the less aggressive Thermage device, were the first entries into the skin tightening arena.¹ Devices that claimed tightening, such as Thermage, Skin Tyte, and Ulthera do create some skin tightening but results are modest.^{2–4} Subdermal radiofrequency (RF) devices have been shown to generate a significant amount of nonexcisional skin tightening over time.⁵ Laser-assisted tissue treatments cause skin contraction as well, but the numbers are less than half of the RF effect.⁶ While ultrasound-assisted liposuction (UAL) has a thermal component, little peer reviewed data shows a strong secondary effect of skin tightening with subdermal ultrasound.⁷ Recently, noninvasive electromagnetic treatments were shown to create approximately 17% measured skin surface area contraction in a pilot study.⁸ Irreversible electroporation appears to be the mechanism of action in this case. While there are many energy-based devices able to achieve mild to moderate skin tightening, in many cases, skin quality is not significantly improved. A particularly difficult target is cellulite and aging skin in the arms, hands, and knee region.

In the future, skin tightening will incorporate textural elements such as wrinkle reduction, soft tissue tone, pore size reduction, and surface irregularity smoothing. Tighter skin is not necessarily attractive following a procedure; thoroughness in device use must be balanced with a desirable outcome. During recent years, the addition of topical and injectable biologicals has become quite popular. While platelet-rich plasma (PRP) treatment outcomes remain quite variable,⁹ intradermal injection of autologous nanofat has shown some dramatic clinical outcomes.¹⁰ Exosomes are quickly replacing other biological topicals as an accompaniment to microneedling, or combined with a liposome based preparation for simple topical use.¹¹ A combination of noninvasive

devices that address the entire framework of the skin, including muscle and fat, plus a device that addresses the superficial hypodermis dermis, can create a desirable multilayer effect. The Food and Drug Administration (FDA) recently approved an injectable biological for improvement of mild to moderate cellulite (https://www.accessdata.fda.gov/drugsatfda_docs/label/2020/761146s000lbl.pdf). The drug also improves skin contour irregularities following surgery or liposuction. The future of skin tightening may demonstrate a shift away from a multitude of devices toward enzymatic agents or cell signaling biologicals such as exosomes, and secretomes. Another rapidly growing field is genetic modification of cells using the CRISPR/Cas system.¹² As always, patient evaluation and proper assessment of needs and goals will drive treatment. In most cases, combination therapy will achieve the best clinical outcome.

2 | AGING

While most aging patients can identify skin laxity as one of the changes associated with getting older, the components may be hard to define. A “loose” feeling, accompanied by thinning of the dermis, a crepey rather than taut and smooth skin surface, and a lack of firmness to touch are commonly noted. Disconnection of the skin/fat layer from the underlying fascia due to stroma/vascular atrophy is clinically seen as pendulosity (Figure 1). Subjective complaints include a combination of superficial fine wrinkling, a dull, dry appearance to the skin, skin surface irregularities or age acquired cellulite, pigmented lesions or “age spots,” and a loose or “floppy” character of the soft tissue. Extrinsic factors tend to govern superficial and more visible skin damage.¹³

Other contributing causes of loose, pendulous skin include intrinsic factors such as the general processes of aging, bone loss, sarcopenia or muscle wasting, and adipose atrophy with loss of the stroma/vascular fraction.¹⁴ At the cellular level, a variety of factors also contribute to the inevitable aging process. These include instability of DNA with

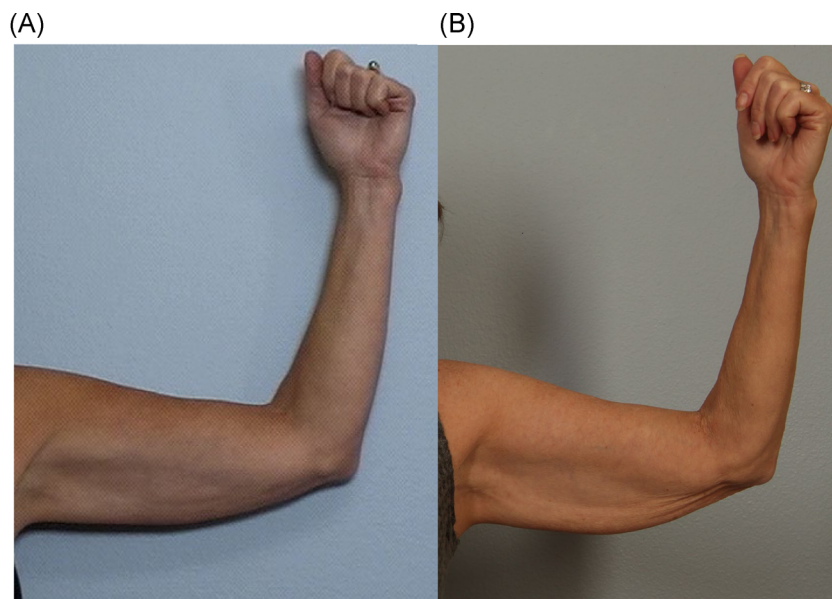


FIGURE 1 (A) 50-year-old with mild upper arm laxity. (B) Same patient aged 63. No weight gain nor procedures.

accumulated damage, telomere shortening, insulin sensitivity and nutritionally induced damage, epigenetic changes, and changes in protein repair through proteostasis.¹⁵ Cellular senescence drives many of the clinical manifestations of human skin and soft tissue. This process accelerates between the ages of 50 and 60.¹⁶ Interestingly cell senescence may have evolved as a way to control tumors, since at a certain point irreversible growth arrest can be signaled.¹⁷ Senescence associated secretory phenotypes (SASPs) can spread aging signals and cellular senescence through a paracrine signaling system.¹⁸ Disturbances in mitochondrial metabolism can contribute to the generation of reactive oxygen species (ROS).¹⁹ As cells age, telomeres shorten.²⁰ In 1965, Hayflick proposed that cells could undergo mitosis only a certain number of times before cell division was no longer possible. This phenomenon, known as the "Hayflick limit," is influenced by the telomere effect.²¹ Telomerase can help by elongating the terminal ends of telomeres to promote continued cell division by regulating the DNA repair system. Abnormalities in the DDR and activation of the tumor suppression proteins p53 and p21 can induce an arrest of cell division.²² These cellular aging pathways regulate most age related pathologies. In the future, treatments that resurrect deficient cellular mechanisms to restore proper cellular function will become more and more important in improving biological and esthetic aspects of aging. While the skin is the largest organ in most people, in women with a body mass index > 35, fat is their largest organ.²³ Current life extension therapies directly affecting adipose tissue that have proven to be therapeutic include caloric restriction, surgical removal of visceral fat, and reduction of insulin sensitivity.²⁴ Reduction of chronic low grade inflammation, influencing the mitochondrial ROS response, and reduction of the expression of the p16 protein have also been shown to directly slow the aging process.²⁵

Future approaches to skin tightening must address all of these factors to satisfy patient needs. While we currently have some solutions for a few of these concerns, most efforts have been focused on the face and neck. Aging body parts such as the upper arms, hands, and knees currently have no complete answers. While tighter skin can technically be achieved with some noninvasive and minimally invasive approaches, the quality of skin in these patients is not always improved. In fact, depletion of the structural support of the skin by performing superficial liposuction can lead to worsening of the skin's appearance (Figure 2).

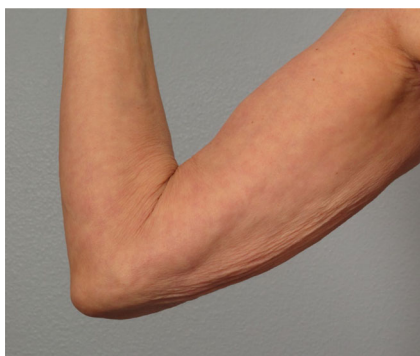

FIGURE 2 56-year old with volar wrinkling and cannula marks following vaser-assisted liposuction

Focal skin contour irregularities following body contouring procedures is a major complaint from 8.4% of patients who have undergone liposuction.²⁶ While "skin tightening" has been a universal goal during the past decade, in coming years the field will extend to restoration of youthful appearing skin.

Mechanical procedures such as non-thermal and thermal microneedling and laser resurfacing may be supplanted by intradermal injection of biologicals such as nanofat and exosomes. Subcision of cellulite may soon be replaced with a simple injectable. Abdominoplasty surgery numbers could decrease as more and more women choose noninvasive methods of improving fascial laxity and skin flaccidity with minimally and noninvasive energy-based devices. In order for EBDs to maintain a market presence, they must be geared towards correcting foundational problems rather than merely mechanically tightening skin.

3 | CURRENT EVOLVING SOLUTIONS

Much of the new research in all fields of medicine focuses on the influence of genetic markers, cell signaling, cell senescence, proteomics, and regenerative medicine.²⁷ During the last decade, the field has expanded at an exponential rate. In the past, the esthetic field has been heavily device oriented. Some devices have proven their value over time, while others are no longer commonly in use. Most devices with retained value offer minimally invasive or noninvasive solutions to lift and contour both facial and body regions. Transcutaneous RF and microfocused ultrasound (MFU) are still shown to be effective for both lifting and tightening the skin.²⁸ Minimally invasive subdermal RF treatments are currently the gold standard for significant skin tightening.²⁹ Monopolar, bipolar, and helium plasma assisted RF devices can create fascial tightening as well as restoring the stroma/vascular framework of the adipose layer³⁰ (Figure 3). During the last several years, combination treatments involving energy based devices plus biologicals have become quite popular.³¹ Especially common are thermal or nonthermal needling treatments plus topicals such as PRP or growth factors.³² While the FDA has advised that microneedling plus biological agents should be regulated as a drug, they agency is not enforcing the ruling at this time (<https://www.fda.gov/regulatory-information/search-fda-guidance-documents/regulatory-considerations-microneedling-devices>). Injectables are still popular, and some fillers have now been repurposed as biostimulation devices. Calcium hydroxylapatite (CaHa) has been successfully used in the limbs and torso as well as in the face for skin thickening and fine wrinkle reduction.³³ Poly-L-lactic acid remains popular as a biostimulatory agent as well.³⁴ Interestingly, polydioxanone (PDO) threads have been shown to add immediate volume as well as stimulating the deposition of a collagen matrix once the resorbable thread has disappeared.³⁵ Even simple hyaluronic acid fillers (HA) have been showing to stimulate neocollagenesis, though the volumetric correction disappears over time.³⁶

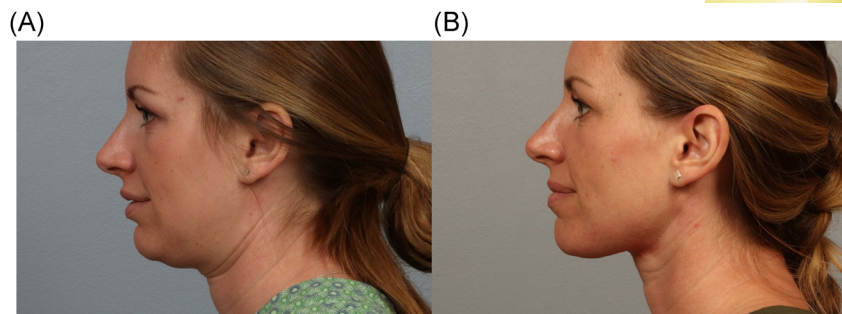


FIGURE 3 (A) 30-year-old before treatment. (B) 3 months following radiofrequency (RF) necklift using helium plasma-driven RF

4 | FUTURE SKIN IMPROVEMENT SOLUTIONS

Simple skin tightening is not a long-term solution for aging skin. Surgical skin excision may provide temporary help, but the character of the remaining tissue is not upgraded. In a few years, recurrent sagging, textural and volumetric changes, and looseness of the skin and soft tissue can be seen again. Noninvasive and minimally invasive solutions that can actually alter the structure of aging tissue will have enduring value. Examples include existing technologies such as minimally invasive subdermal RF and noninvasive high-intensity electromagnetic field applications.

5 | RF ENERGY

Aging in the adipose layer is characterized by volumetric changes as well as loss of stromal and vascular support. Restoration of the stromal/vascular fraction using RF-assisted devices can reverse the structural changes than are clinically manifested as soft tissue flabbiness and pendulosity, and by dermal thinning and laxity. Figure 4 shows a scanning electron micrograph study showing the adipocyte matrix of a young woman, a middle aged woman, and an older woman. Clear loss over time of the fibrocollagenous three-dimensional framework that knits the layer together in a firm and defined shape is noted. Skin laxity can be improved by using subdermal RF

treatments. Up to 36% skin surface area contraction can be seen at 1-year posttreatment.³⁷ The process has been studied and interestingly, causes indirect skin contraction by stimulating the three-dimensional adipose collagen framework. Both monopolar and bipolar devices can be effective. Helium plasma-driven RF adds safety to the treatment, as the skin surface does not need to become warm in order for soft tissue contraction to occur.³⁸ As people age, their adipose layer atrophies, and both collagen stroma and vascular supply erode away. The collagen framework that knits adipocytes together into a defined shape can be restored using multilevel RF energy following liposuction or simple tunneling with a cannula following tumescent infusion. These structures proliferate over a year's time, though a single treatment generally is needed (Figure 5). Restoration of a cohesive subcutaneous structure with a firmer tone is accompanied by measurable skin surface area contraction.³⁹ Clinically, a 35% skin surface area contraction is the maximum that retains a smooth unwrinkled skin surface.

6 | HIGH-INTENSITY FOCUSED ELECTROMAGNETIC FIELD

In the aging patient, volumetric loss over time includes bone, muscle, the adipose/stroma layer, as well as skin. By creating supramaximal muscle contractions that cannot be duplicated in daily life, sarcopenia can be focally reversed.⁴⁰





FIGURE 4 (A) SEM of 21 year old adipose has strong network of collagen fibers knitting adipocytes together. (B) 41 year old adipose stroma shows loss of these fibers, but still a cohesive structure. (C) SEM of 61 year old fat shows both extreme loss of collagen framework as well as clinical tissue pendulosity

FIGURE 5 (A) Tissue biopsy at baseline. (B) Same patient 3 months post-treatment with radiofrequency-assisted liposuction. Note resotation of a contiguous stromal framework



Emsculpt (BTL) utilizes high-intensity electromagnetic energy to generate both muscle hypertrophy and fat reduction. Quantification of muscle hypertrophy and hyperplasia shows a 13%–16% increase in overall muscle mass in tested regions, including the buttocks, abdomen, arms, and calves.⁴¹ Four 30 min treatment sessions are performed. Histologic evaluation of muscle shows both muscle fiber hypertrophy as well as hyperplasia.⁴² In regions with excess adipose tissue, a different program using the same device can generate a 15%–23% fat thickness reduction as measured with magnetic resonance imaging and ultrasound⁴³ (Figure 6). An interesting side effect of the device is fascial tightening. Jacobs and Lozanova⁴⁴ demonstrated a 22.1% decrease in the width of diastasis recti in postpartum women at 3 months posttreatment. The author's experience has been that even more diastasis improvement can be achieved with a higher number of treatments. Figure 7 shows a 63-year-old woman who underwent two sessions of six treatments each, spaced 3 months apart. Vectra evaluation showed an abdominal volumetric reduction of 1151 cc, and a measured skin surface contraction of 17.9%.

7 | NONINVASIVE RF PLUS THERMOPLASTIC ELASTOMERS (TPE)

Noninvasive devices using RF, or RF combined with shock wave therapy can improve previously difficult problems such as peri-umbilical flaccidity after childbirth, striae, and disconnection of the skin/fat layer from the underlying fascia. Emtone (BTL) combines transdermal RF energy with targeted pressure energy to treat both cellulite and skin laxity. The simultaneous delivery of TPE has been shown to enhance the clinical effect of RF heating.⁴⁵ Histology shows

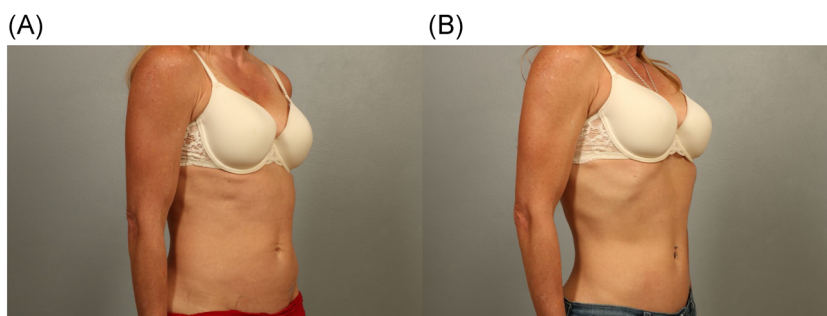
stimulation of both collagen and elastin fibers intradermally, resulting in skin thickening as seen in the reticular dermis. The device also directly affects the septae of the superficial adipose layer in the hypodermis. Biopsies show a decrease in adipose content in the superficial fat compartments, and better fat chamber organization with uniformity of the septae.

Age acquired cellulite, frequently seen on the anterior thighs, is strongly improved with subdermal RF and Emtone applied in a series of four topical treatments. The device works on the premise that an enhanced framework combined with direct dermal repair will result in clinically smoother and tighter skin. Emtone specifically addresses skin laxity. A series of four treatments is used to address skin flaccidity, wrinkling, and striae in the abdomen, arms, and thighs. The device also improves the pronounced contour irregularities in the buttock region (Figure 8).

8 | NANOFAT

Upcoming skin tightening and quality improvement solutions will all have a physiological or biological basis. While the FDA has decried the field of regenerative medicine as a whole (<https://www.fda.gov/vaccines-blood-biologics/cellular-gene-therapy-products/framework-regulation-regenerative-medicine-products>), the popularity of the genre remains strong. PRP treatments remain popular, despite the plethora of peer reviewed articles showing little effect outside treatments of articular joint surfaces.⁴⁶ Topical growth factors are also popular, but none are FDA approved for an esthetic indication. Multiple studies performed since 2001 have shown that adipose-derived stem cells (ADSCs) can improve collagen and elastin content in

FIGURE 6 (A) 49-year-old marathon runner prior to treatment. (B) Patient 6 weeks following four treatments with high-intensity electromagnetic field



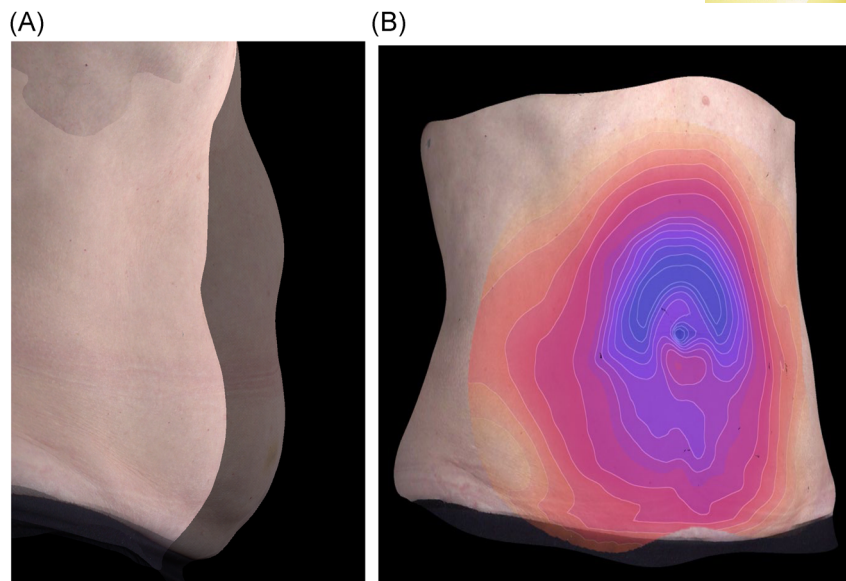


FIGURE 7 (A) 63-year-old with ghosted pretreatment image over posttreatment image. Patient was treated with two sets of six sessions of Emsculpt to the abdomen. (B) Volumetric measurement using the Vectra XT system showed volume reduction of 1151 cc.

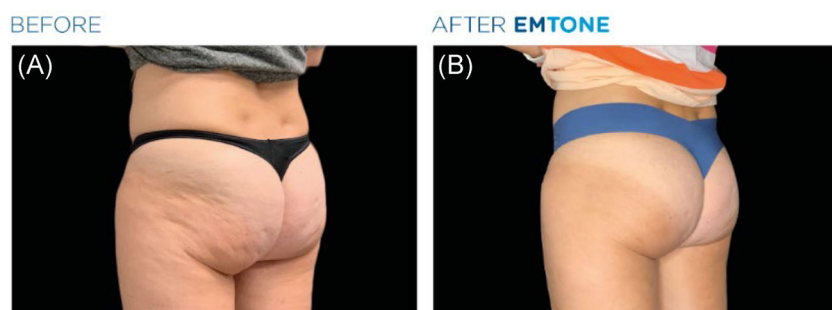


FIGURE 8 (A) 35-year-old with grade II cellulite before treatment. Body mass index is 26.12. (B) Six weeks following 4th treatment with combined radiofrequency and thermoplastic elastomers

the skin and adipose framework.⁴⁷ Many centers showed that fat grafting could be used for both cosmetic and structurally beneficial purposes.^{48,49} In addition to restoring volume in the adipose layer, Cohen⁵⁰ notes the improvement of collagen and elastin in the dermal layer, as well as neoangiogenesis. FDA disapproval of “more than minimal manipulation” of autologous tissue led to a ban on the use of SVF techniques for stem cell treatments (<https://www.fda.gov/vaccines-blood-biologics/cellular-gene-therapy-products/framework-regulation-regenerative-medicine-products>). While there are many internet claims of FDA approved stem cell solutions (https://exosomes.sale/gclid=Cj0KCQjw3s_4BRDPArisAJsyoLMUzRfrQB8cmPC6_9ytWlyolk_SrVoSxf0Ov5ChQ4nKMr5SXy_zGdEaAueDEALw_wcB), none are actually FDA approved. The challenge has been finding a minimally manipulative procedure to produce progenitor cells that is acceptable to the regulatory agency.

In 2013, Tonnard et al.⁴⁷ described the use of “nanofat” instead of traditionally processed adipose stem cells for facial rejuvenation. His group noted that adipose tissue processed through a series of screens eventually lost all adipose cells, but many progenitor cells were still present. Mechanical processing avoided the need for collagenase, thus meeting the FDA standard of “minimally manipulated” tissue. Cohen, Hewett and Ross described several levels of adipose particulates including “macrofat,” “millifat,” “microfat,” and nanofat.⁵¹ Each is

injectable with successively smaller needles. The injection of nanofat intradermally can provide remarkable improvement in solar elastosis, dark undereye circles, fine wrinkling, and loss of skin tone and texture (Figure 9). These injections can be safely performed in conjunction with a necklift, or immediately after laser resurfacing (Figure 10). Injections seem clinically superior to needling followed by topical application, as stem cells are subject to a rapid demise when dessicated.

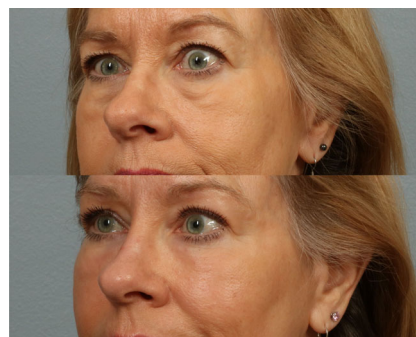

FIGURE 9 62-year-old preoperatively, above. Below, 1 year following erbium laser resurfacing and fat grafting. Macrofat was placed at the supraperiosteal level of the infraorbital rim. Nanofat was injected intradermally in the lower eyelid and infraorbital region

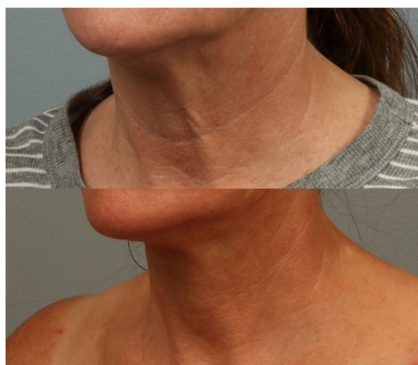

FIGURE 10 56-year-old patient before, above, and 3 months post nanofat injection intradermally into the neck and necklace lines. Necklace lines were injected at 4 and 1.5 mm depths. Platysmal lines are softened without platysmaplasty

Exosomes are a relatively new resource. These tiny extracellular particles are derived from intracellular endosomes. Endosomes fuse with the cell membrane before extruding their contents.⁴⁶ These nanoparticles work by sending signals to nearby cells using the paracrine signaling system. Now, instead of needing actual progenitor cells, these messengers can be used as a substitute. Exosomes can be found in the conditioned media that is used as nutrition for stem cell cultures.⁵² In 2005, Gnechi noted that cardiac stem cells combined with bone marrow derived mesenchymal cells did not engraft well into a damaged myocardium. However, despite the low number of viable cells noted, there was a strong clinical improvement. The team proposed that stem cells released some kind of “factor” that induced cardiac myocyte proliferation, as well as angiogenesis and stabilization of injured cells.⁵³ While Darwin had proposed particles called “gemmules” that were shed from all cell types in 1868, it wasn't until after the turn of the century that hypothesis was modified and validated.⁵⁴

Exosomes range in size from 30 to 120 nm⁵⁵ and contain many small molecules. mRNA, miRNA < siRNA, and thousands of proteins including ALIX, Tsg101, heat shock proteins, annexin, and flotillins.⁵⁶

Production and isolation systems of these tiny acellular particles can vary. Commonly used methods include ExoChip, immune modified

magnetic affinity isolation, PEG size differential and ultrafiltration or ultracentrifugation.⁵⁷ The use of exosomes as a biomarker has led to development of nonsurgical “biopsies” by evaluating fluids containing exosomes such as urine, sputum, blood, breast milk, and saliva.^{58–61} MicoRNA biomarkers can be used to evaluate patients for the presence of Alzheimer's disease and Parkinson's disease.^{62,63} Exosomes can be used to both evaluate patients for the presence of breast cancers as well as to check for residual disease once treatments are concluded.^{64,65} While used in cardiology, hepatic, and pulmonary medicine for some years,^{66–68} exosomes are new in the esthetic field. Current esthetic uses include topical application for atopic dermatitis, hair restoration, and acceleration of healing in laser resurfacing patients.^{2,69,70} Kwon et al.⁷¹ showed a 32.5% improvement in acne scarring using a topical application of lyophilized exosomes. Chernoff reported a 94% success rate in treating keloid scars with exosomes at 1 year. He also reported an 86% patient satisfaction rate following treatments combining microneedling and topical application of exosomes.⁷² Regulatory concerns regarding the newest entry into the regenerative medicine market caused the FDA to issue a public safety notification on December 6, 2019 (<https://www.fda.gov/vaccines-blood-biologics/safety-availability-biologics/public-safety-notification-exosome-products>). To date, there are no pending esthetic based investigational new drugs (INDs) for exosome products (<https://bioinformant.com/top-exosome-companies/>). Since the FDA is not currently enforcing the 2018 ruling on the use of biologics with microneedling, most esthetic practitioners are choosing to use only topical application of exosomes to comply with regulatory guidelines (<https://www.fda.gov/regulatory-information/search-fda-guidance-documents/regulatory-considerations-microneedling-devices>). Even use of topical exosomes without microneedling can offer remarkable reduction in inflammation as well as rapid healing. Figure 11 shows a stage IV lobular carcinoma patient immediately post radiation treatment. She was treated with topical application of lyophilized exosomes in a squalene lipophilic emulsion twice a day for 10 days. The patient reported immediate pain cessation following the first application. Five days posttreatment, her erythema had decreased markedly. At 9 days posttreatment, her skin had returned to a normal color and had resumed a soft and supple character.

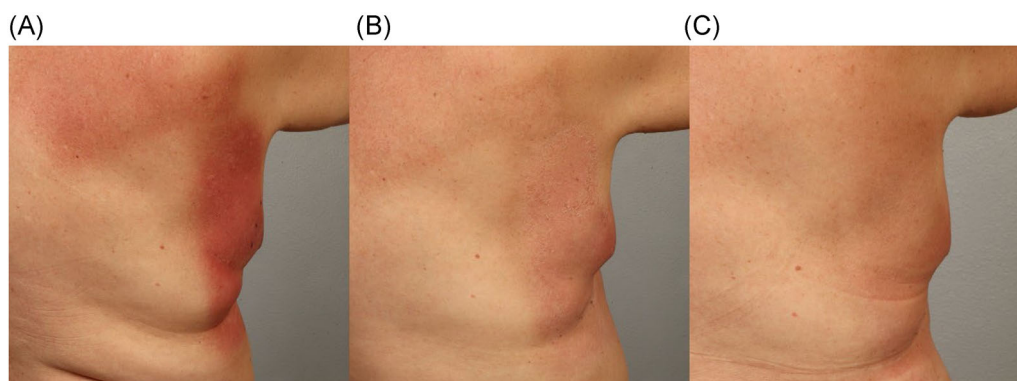


FIGURE 11 (A) 62-year-old 1 day post chest wall radiation for metastatic breast cancer. The burn extended through the chest cavity to her back. (B) 5 days post bid topical application of exosomes plus squalene. (C) 9 days post topical treatment with exosomes plus resolution of burn plus preservation of skin mobility. Significant reduction in hyperpigmentation as well

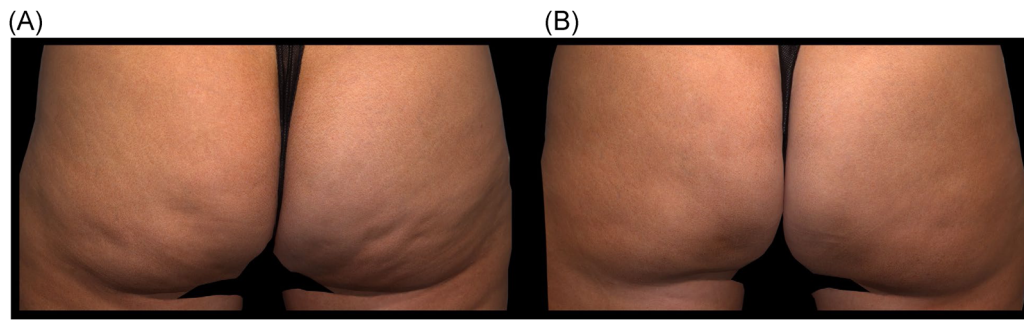


FIGURE 12 (A) 52-year-old woman before treatment. Body mass index, 23.6; skin type II. (B) Patient 71 days posttreatment with Qwo injected subdermally. Patient's composite cellulite score was reduced by two levels

9 | COLLAGENASE

Once considered a throwaway enzyme for producing SVF fractions from ADSCs, collagenase has now become a mainstream player in the skin and soft tissue contour correction field. Xiaflex was approved by the FDA for injection in cases of Dupuytren's contracture in 2010.⁷³ Shortly afterwards, FDA approval for use in Peyronie's disease was granted.⁷⁴

Matrix metalloproteases can lyse some collagen based structures found in the extracellular matrix.⁷⁵ When the presence of excessive amounts of collagen clinically presenting as hypertrophic scars, fibrosis, localized skin depressions, or depressed scars is noted, injections of collagenase can help. The enzyme is secreted by fungi, certain plants, animals such as the crab *Paralithodes camtschatica*⁷⁶ and specifically by the bacteria *Clostridium histolyticum*.⁷⁷ Other collagenases are produced by *Achromobacter*, *Streptomyces*, and *Actinomyces*. These have been extensively studied in the laboratory.⁷⁸ Type I collagenase is the most commonly used to process ADSCs when using the stromal vascular fraction technique.⁷⁹

Side effects of injected collagenase include localized bruising, itching, swelling, and lymphadenopathy.⁸⁰ In some cases, incomplete correction of the targeted deformity can require a secondary injection.

The author has been using collagenase for injectable treatment of cellulite in combination with injection lipolysis since 2006.⁸¹ Depressed surgical scars and post-liposuction deformity treatment are other off label uses for collagenase. On July 6, 2020, the FDA granted approval for the new drug "Qwo" (Endo Pharmaceutical) as an injection for global improvement of cellulite grades II and III. Figure 12 shows a two-grade improvement of cellulite in a 52-year-old woman's buttock at day 71 following a single injection session. Kaufman⁸² presented a series of patients, noting a one- to two-grade improvement in cellulite classification of the buttocks at 71 days posttreatment, using the new collagenase injectable.

10 | CONCLUSION

It is interesting that esthetic specialists are just beginning to embrace the concepts of cell based therapy and genetically targeted signaling. Perhaps one reason is that, as a whole, our industry is largely driven

by injectables, devices, and surgical procedures. These are "languages" we speak. While PRP, stem cells, and other topical biologicals are not new, they have had difficulty taking off due to tight FDA constraints. Patient acceptance of regenerative medicine is strong, but regulatory concerns about false claims and lack of product uniformity are real, due to instances in which patients were misled and in some cases, harmed. While targeted biologicals are clearly the direction of the future, patient safety is always the top concern.

CONFLICT OF INTERESTS

The author is a member of the medical advisory board of APYX Medical. She is a consultant for BTL.

ETHICAL STATEMENT

All participants/patients consented to publication of their photography in this manuscript.

REFERENCES

- Gold MH. Noninvasive skin tightening treatment. *J Clin Aesthet Dermatol*. 2015;8(6):14-18.
- Gold M. Update on tissue tightening. *J Clin Aesthet Dermatol*. 2010;3(5):36-41.
- Marcus BC, Hyman D. Evidence-based medicine in laser medicine for facial plastic surgery. *Facial Plast Surg Clin North Am*. 2015;23(3):297-302. <https://doi.org/10.1016/j.fsc.2015.04.003>
- Fabi SG. Noninvasive skin tightening: focus on new ultrasound techniques. *Clin Cosmet Invest Dermatol*. 2015;8:47-52. <https://doi.org/10.2147/CCID.S69118>
- Irvine Duncan D. Nonexcisional tissue tightening: creating skin surface area reduction during abdominal liposuction by adding radiofrequency heating. *Aesthet Surg J*. 2013;33(8):1154-1166. <https://doi.org/10.1177/1090820X13505862>
- DiBernardo BE. Randomized, blinded split abdomen study evaluating skin shrinkage and skin tightening in laser-assisted liposuction versus liposuction control. *Aesthet Surg J*. 2010;30(4):593-602. <https://doi.org/10.1177/1090820X10380707>
- Collins PS, Moyer KE. Evidence-based practice in liposuction. *Ann Plast Surg*. 2018;80(6S suppl 6):S403-S405. <https://doi.org/10.1097/SAP.0000000000001325>
- Duncan Diane I. Mommy makeover: what can be achieved with HIFEM. In: 5CC Aesthetic Conference, Barcelona; 2020.
- Dhurat R, Sukesh M. Principles and methods of preparation of platelet-rich plasma: a review and author's Perspective. *J Cutan Aesthet Surg*. 2014;7(4):189-197. <https://doi.org/10.4103/0974-2077.150734>

10. Cohen SR, Hewett S, Ross L, et al. Regenerative cells for facial surgery: biofilling and biocontouring. *Aesthet Surg J*. 2017;37(suppl_3):S16-S32. <https://doi.org/10.1093/asj/sjx078>
11. Duncan DI. Combining PDO threads with exosomes for microlifting. *InTech Open*; 2020. <https://doi.org/10.5772/intechopen.91796>. <https://www.intechopen.com/online-first/combining-pdo-threads-with-exosomes-for-microlifting>
12. Ford K, McDonald D, Mali P. Functional genomics via CRISPR-Cas. *J Mol Biol*. 2019;431(1):48-65. <https://doi.org/10.1016/j.jmb.2018.06.034>
13. Waaijer MEC, Parish WE, Strongitharm BH, et al. The number of p16^{INK4a} positive cells in human skin reflects biological age. *Aging Cell*. 2012;11(4):722-725.
14. Wehrli NE, Bural G, Houseni M, Alkhawaldeh K, Alavi A, Torigian DA. Determination of age-related changes in structure and function of skin, adipose tissue, and skeletal muscle with computed tomography, magnetic resonance imaging, and positron emission tomography. *Semin Nucl Med*. 2007;37(3):195-20.
15. López-Otín C, Blasco MA, Partridge L, Serrano M, Kroemer G. The hallmarks of aging. *Cell*. 2013;153(6):1194-1217. <https://doi.org/10.1016/j.cell.2013.05.039>
16. Tchkonina T, Morbeck DE, von Zglinicki T, et al. Fat tissue, aging, and cellular senescence. *Aging Cell*. 2010;9(5):667-684.
17. Regulski MJ. Cellular senescence: what, why, and how. *Wounds*. 2017;29(6):168-174.
18. Nie L, Zhang P, Wang Q, Zhou X, Wang Q. IncRNA-triggered macrophage inflammation deteriorates age-related diseases. *Mediators Inflamm*. 2019;2019:4260309-4260312. <https://doi.org/10.1155/2019/4260309>
19. Ziegler DV, Wylie CD, Velarde MC. Mitochondrial effectors of cellular senescence: beyond the free radical theory of aging. *Aging Cell*. 2015;14(1):1-7.
20. Sahin E, Depinho RA. Linking functional decline of telomeres, mitochondria and stem cells during aging. *Nature*. 2010;464(7288):520-528.
21. Hayflick L. The limited in vitro lifetime of human diploid cell strains. *Exp Cell Res*. 1965;37:614-636.
22. Tian X, Seluanov A, Gorbunova V. Molecular mechanisms determining lifespan in short- and long-lived species. *Trends Endocrinol Metab*. 2017;28(10):722-734
23. Muzumdar R, Allison DB, Huffman DM, et al. Visceral adipose tissue modulates mammalian longevity. *Aging Cell*. 2008;7(3):438-40.
24. Barzilai N, Gupta G. Revisiting the role of fat mass in the life extension induced by caloric restriction. *J Gerontol A Biol Sci Med Sci*. 1999;54(3):B89-B96; discussion B97-8.
25. Quinlan CL, Perevoshchikova IV, Hey-Mogensen N, Orr AL, Brand MD. Sites of reactive oxygen species generation by mitochondria oxidizing different substrates. *Redox Biol*. 2013;1:304-312.
26. Kim YH, Cha SM, Naidu S, Hwang WJ. Analysis of postoperative complications for superficial liposuction: a review of 2398 cases. *Plast Reconstr Surg*. 2011;127(2):863-871. <https://doi.org/10.1097/PRS.0b013e318200afbf>
27. Rayment EA, Williams DJ. Concise review: mind the gap: challenges in characterizing and quantifying cell- and tissue-based therapies for clinical translation. *Stem Cells*. 2010;28(5):996-1004. <https://doi.org/10.1002/stem.416>
28. Fabi SG, Goldman MP. Retrospective evaluation of micro-focused ultrasound for lifting and tightening the face and neck. *Dermatol Surg*. 2014;40(5):569-575. <https://doi.org/10.1111/dsu.12471>
29. Theodorou SJ, Paresi RJ, Chia CT. Radiofrequency-assisted liposuction device for body contouring: 97 patients under local anesthesia. *Aesthetic Plast Surg*. 2012;36(4):767-779. <https://doi.org/10.1007/s00266-011-9846-1>
30. Paul M, Blugerman G, Kreindel M, Mulholland RS. Three-dimensional radiofrequency tissue tightening: a proposed mechanism and applications for body contouring. *Aesthetic Plast Surg*. 2011; 35(1): 87-95. <https://doi.org/10.1007/s00266-010-9564-0>
31. Duncan DI. Microneedling with biologicals: advantages and limitations. *Facial Plast Surg Clin North Am*. 2018;26(4):447-454. <https://doi.org/10.1016/j.fsc.2018.06.006>
32. Ibrahim MK, Ibrahim SM, Salem AM. Skin microneedling plus platelet-rich plasma versus skin microneedling alone in the treatment of atrophic post acne scars: a split face comparative study. *J Dermatolog Treat*. 2018;29(3):281-286. <https://doi.org/10.1080/09546634.2017.1365111>
33. deAlmeida, AT, Figueredo V, da Cunha ALG, et al. Consensus recommendations for the use of hyperdiluted calcium hydroxylapatite as a face and body biostimulatory agent. *Plast Reconstr Surg Glob Open*. 2019; 7(3): e2160. <https://doi.org/10.1097/GOX.0000000000002160>
34. Schierle CF, Casas L. Nonsurgical rejuvenation of the aging face with injectable poly-L-lactic acid for restoration of soft tissue volume. *Aesthet Surg J*. 2011;31(1):95-109. <https://doi.org/10.1177/1090820X10391213>
35. Visco A, Scolaro C, Giamporcaro A, De Caro S, Tranquillo E, Catauro M. Threads made with blended polymers: mechanical, physical, and biological features. *Polymers (Basel)*. 2019; 11(5): 901. <https://doi.org/10.3390/polym11050901>
36. Snetkov P, Zakharova K, Morozkina S, Olekhovich R, Uspenskaya M. Hyaluronic acid: the influence of molecular weight on structural, physical, physico-chemical, and degradable properties of biopolymer. *Polymers (Basel)*. 2020; 12(8): 1800. <https://doi.org/10.3390/polym12081800>
37. Diane Irvine Duncan MD. FACS, Improving outcomes in upper arm liposuction: adding radiofrequency-assisted liposuction to induce skin contraction. *Aesthet Surg J*. 2012;32(1):84-95. <https://doi.org/10.1177/1090820X11429549>
38. Duncan DI. Helium plasma driven radiofrequency in body contouring. *InTech Open*. 2019. <https://doi.org/10.5772/intechopen.84207>
39. Mulholland RS. BodyTite: the science and art of radiofrequency assisted lipocoagulation (RFAL) in body contouring surgery. *InTech Open*. 2019. <https://doi.org/10.5772/intechopen.83446>
40. Kinney B, Lozano P. High intensity focused electromagnetic therapy evaluated by magnetic resonance imaging: safety and efficacy study of a dual tissue effect based non-invasive body shaping. *Lasers Surg Med*. 2019; 51(1): 40-46. <https://doi.org/10.1002/lsm.23024>
41. Katz B. An overview of HIFEM technology in body contouring. *Derm Reviews*. 2020;1:91-96. <https://doi.org/10.1002/der.2.24>
42. Duncan D, Dinev I. Noninvasive induction of muscle fiber hypertrophy and hyperplasia: effects of high intensity focused electromagnetic field evaluated in an in-vivo porcine model: a pilot study. *Aesthet Surg J*. 2020; 40(5): 568-574. <https://doi.org/10.1093/asj/sjz244>
43. Weiss R, Bernardy J. Induction of fat apoptosis by a non-thermal device: Mechanism of action of non-invasive high-intensity electromagnetic technology in a porcine model. *Lasers Surg Med*. 2019; 51(1): 47-53. <https://doi.org/10.1002/lsm.23039>
44. Jacobs C, Lozano P. MRI study: women after childbirth. VCS, Las Vegas; 2019.
45. Kinney BM, Kanakov D, Yonkova P. Histological examination of skin tissue in the porcine animal model after simultaneous and consecutive application of monopolar radiofrequency and targeted pressure energy. *J Cosmet Dermatol*. 2020;19(1):93-101. <https://doi.org/10.1111/jocd.13235>
46. Amable P, Carias RB, Teixeira MV, et al. Platelet-rich plasma preparation for regenerative medicine: optimization and quantification of cytokines and growth factors. *Stem Cell Res Ther*. 2013; 4(3): 67. <https://doi.org/10.1186/scrt218>
47. Zuk PA, Zhu M, Mizuno H, et al. Multilineage cells from human adipose tissue: implications for cell-based therapies. *Tissue Eng*. 2001;7:211-228.

48. Rigotti G, Charles-de-Sá L, Gontijo-de-Amorim NF, et al. Expanded stem cells, stromal-vascular fraction, and platelet-rich plasma enriched fat: comparing results of different facial rejuvenation approaches in a clinical trial. *Aesthet Surg J*. 2016;36:261-270. <https://doi.org/10.1093/asj/sjv231>
49. Strong AL, Cederna PS, Rubin JP, Coleman SR, Levi B. The current state of fat grafting: a review of harvesting, processing, and injection techniques. *Plast Reconstr Surg*. 2015; 136(4): 897-912. <https://doi.org/10.1097/PRS.0000000000001590>
50. Cohen SR, Womack H. Injectable tissue replacement and regeneration: anatomic fat grafting to restore decayed facial tissues. *Plast Reconstr Surg Glob Open*. 2019;7:e2293. <https://doi.org/10.1097/GOX.0000000000002293>
51. Scott CC, Vacca F, Gruenberg J. Endosome maturation, transport and functions. *Semin Cell Dev Biol*. 2014;31:2-10. <https://doi.org/10.1016/j.semcdb.2014.03.034>
52. Sharma S, Scholz-Romero K, Rice GE, Salomon C. Methods to enrich exosomes from conditioned media and biological fluids. *Methods Mol Biol*. 2018;1710:103-115. https://doi.org/10.1007/978-1-4939-7498-6_8
53. Gnecci M, He H, Liang OD, et al. Paracrine action accounts for marked protection of ischemic heart by AKT-modified mesenchymal stem cells. *Nat Med*. 2005;11:367-368.
54. Liu Y. A new perspective on Darwin's Pangenesis. *Biol Rev Camb Philos Soc*. 2008;83(2):141-149. <https://doi.org/10.1111/j.1469-185X.2008.00036.x>
55. Zhang KL, Wang YJ, Sun J, et al. Artificial chimeric exosomes for anti-phagocytosis and targeted cancer therapy. *Chem Sci*. 2018; 10(5):1555-1561. <https://doi.org/10.1039/c8sc03224f>
56. Phinney DG, Pittenger MF. Concise review: MSC-derived exosomes for cell-free therapy [published correction appears in *Stem Cells*. 2017;35(9):2103]. *Stem Cells*. 2017;35(4):851-858. <https://doi.org/10.1002/stem.2575>
57. Baranyai T, Herczeg K, Onódi Z, et al. Isolation of exosomes from blood plasma: qualitative and quantitative comparison of ultracentrifugation and size exclusion chromatography methods. *PLOS One*. 2015;10(12): e0145686. <https://doi.org/10.1371/journal.pone.0145686>
58. Kang YT, Purcell E, Palacios-Rolston C, et al. Isolation and profiling of circulating tumor-associated exosomes using extracellular vesicular lipid-protein binding affinity based microfluidic device. *Small*. 2019;15(47):e1903600. <https://doi.org/10.1002/sml.201903600>
59. Tang YT, Huang YY, Zheng L, et al. Comparison of isolation methods of exosomes and exosomal RNA from cell culture medium and serum. *Int J Mol Med*. 2017;40(3):834-844. <https://doi.org/10.3892/ijmm.2017.3080>
60. Cai S, Luo B, Jiang P, et al. Immuno-modified superparamagnetic nanoparticles via host-guest interactions for high-purity capture and mild release of exosomes. *Nanoscale*. 2018;10(29):14280-14289. <https://doi.org/10.1039/c8nr02871k>
61. Lau C, Kim Y, Chia D, et al. Role of pancreatic cancer-derived exosomes in salivary biomarker development. *J Biol Chem*. 2013; 288(37):26888-26897. <https://doi.org/10.1074/jbc.M113.452458>
62. Yang TT, Liu CG, Gao SC, Zhang Y, Wang PC. The serum exosome derived microRNA-135a, -193b, and -384 were potential Alzheimer's disease biomarkers. *Biomed Environ Sci*. 2018;31(2):87-96. <https://doi.org/10.3967/bes2018.011>
63. Cao XY, Lu JM, Zhao ZQ, et al. MicroRNA biomarkers of Parkinson's disease in serum exosome-like microvesicles. *Neurosci Lett*. 2017; 644:94-99. <https://doi.org/10.1016/j.neulet.2017.02.045>
64. Joyce DP, Kerin MJ, Dwyer RM. Exosome-encapsulated microRNAs as circulating biomarkers for breast cancer. *Int J Cancer*. 2016; 139(7):1443-1448. <https://doi.org/10.1002/ijc.30179>
65. Alimirzaie S, Bagherzadeh M, Akbari MR. Liquid biopsy in breast cancer: a comprehensive review. *Clin Genet*. 2019;95(6):643-660. <https://doi.org/10.1111/cge.13514>
66. Zhang Y, Hu YW, Zheng L, Wang Q. Characteristics and roles of exosomes in cardiovascular disease. *DNA Cell Biol*. 2017;36(3): 202-211. <https://doi.org/10.1089/dna.2016.3496>
67. Kubo H. Extracellular vesicles in lung disease. *Chest*. 2018;153(1): 210-216. <https://doi.org/10.1016/j.chest.2017.06.026>
68. Sato K, Meng F, Glaser S, Alpini G. Exosomes in liver pathology. *J Hepatol*. 2016;65(1):213-221. <https://doi.org/10.1016/j.jhep.2016.03.004>
69. Shin K-O, Ha DH, Kim JO, et al. Exosomes from human adipose tissue-derived mesenchymal stem cells promote epidermal barrier repair by inducing de novo synthesis of ceramides in atopic dermatitis. *Cells*. 2020;9:680.
70. Lim SK, Yeo MSW, Sheng CT, Chai LR. Use of exosomes to promote or enhance hair growth. Patent EP2629782A1. January 22, 2015.
71. Kwon HH, Yang SH, Lee J, et al. Combination treatment with human adipose tissue stem cell derived exosomes and fractional CO₂ laser for acne scars: a 12-week prospective, double-blind, randomized, split-face study. *Acta Derm Venereol*. 2020. <https://doi.org/10.2340/00015555-3666>
72. Chernoff G. Fetal mesenchymal cultured stem cell derived exosomes: the potential utilization in aesthetic and reconstructive surgery: a pilot study. 7th International Cell Surgical Meeting, Las Vegas; 6/19-6/20, 2020.
73. Food and Drug Administration. FDA approves Xiaflex for debilitating hand condition. 2010. <http://www.drugdiscoverytoday.com/view/7083/fda-approves-xiaflex-for-debilitating-hand-condition/>. Accessed 16 March 2010.
74. Haberfeld, H, ed. (2009). *Austria-Codex* (in German) (2009/2010 ed.). Vienna: Österreichischer Apothekerverlag.
75. Shekhter AB, Balakireva AV, Kuznetsova NV, Vukolova MN, Litvitsky PF, Zamyatin AA Jr. Collagenolytic enzymes and their applications in biomedicine. *Curr Med Chem*. 2019;26(3):487-505. <https://doi.org/10.2174/0929867324666171006124236>
76. Merkel JR, Dreisbach JH, Ziegler HB. Collagenolytic activity of some marine bacteria. *Appl Microbiol*. 1975;29(2):145-151.
77. Eckhard U, Huesgen PF, Brandstetter H, Overall CM. Proteomic protease specificity profiling of clostridial collagenases reveals their intrinsic nature as dedicated degraders of collagen. *J Proteomics*. 2014; 100(100):102-114. <https://doi.org/10.1016/j.jprot.2013.10.004>
78. Demina NS, Lysenko SV. Kollagenoliticheskie fermenty, sinteziruemye mikroorganizmami [Collagenolytic enzymes synthesized by microorganisms]. *Mikrobiologiya*. 1996;65(3):293-304.
79. Chang H, Do BR, Che JH, et al. Safety of adipose-derived stem cells and collagenase in fat tissue preparation. *Aesthetic Plast Surg*. 2013; 37(4):802-808. <https://doi.org/10.1007/s00266-013-0156-7>
80. Hayton MJ, Bayat A, Chapman DS, Gerber RA, Szczypa PP. Isolated and spontaneous correction of proximal interphalangeal joint contractures in Dupuytren's disease: an exploratory analysis of the efficacy and safety of collagenase *Clostridium histolyticum*. *Clin Drug Investig*. 2013;33(12): 905-912. <https://doi.org/10.1007/s40261-013-0139-0>
81. Duncan DI, Chubaty R. Clinical safety data and standards of practice for injection lipolysis: a retrospective study. *Aesthet Surg J*. 2006; 26(5):575-585. <https://doi.org/10.1016/j.asj.2006.08.006>
82. Kaufman J. A new injectable for cellulite grades II and III. American Academy of Dermatology Annual Meeting; March 2, 2019; Washington, DC.

How to cite this article: Duncan DI. The future of skin tightening: Mechanical or biological? *Dermatological Reviews*. 2020;1:128-137. <https://doi.org/10.1002/der.240>